

Two Cases Of Nasal Neurofibroma

M Fraczek, M Zaleska-Krecicka, T Zatonski, T Krecicki

Citation

M Fraczek, M Zaleska-Krecicka, T Zatonski, T Krecicki. *Two Cases Of Nasal Neurofibroma*. The Internet Journal of Otorhinolaryngology. 2005 Volume 5 Number 2.

Abstract

We describe here two cases of neurofibroma arising from the nasal cavity. Those cases represent a peripheral nerve sheath tumor extremely uncommon in the nasal cavity and paranasal sinuses. The patients complained of nasal obstruction, periodical epistaxis and intensive watery leakage from the nose. Anterior rhinoscopy, computed tomography and magnetic resonance imaging revealed a polypoid masse in the nasal cavity. The tumours were treated by complete local excision. The postoperative course was uneventful, and no recurrence has been observed to date.

INTRODUCTION

Schwann cells and perineural cells derived from neuroectoderm are thought to be the origin of so called peripheral nerve sheath tumours (1). These cells are located in different positions within the nerve sheath; otherwise they cannot be distinguished from each other. These tumours might be classified as benign and malignant. The first group consists of solid schwannoma (also called neurilemoma, neurilemmoma, neurolemoma and neurinoma) and neurofibroma. A malignant tumour comprises neurogenic sarcoma diagnosed with other terms including malignant schwannomas, malignant neurilemoma, malignant neurinoma, malignant nerve sheath tumour, neurogenic sarcoma, and neurofibrosarcoma. Neurofibroma is divided into solitary tumours and multiple tumours that include neurofibromatosis I and II. Neurofibromas of the upper respiratory tract occur only rarely and are extremely uncommon in the nasal cavity, paranasal sinuses and nasopharynx (2). In the area of the nose and paranasal sinuses, neurofibroma arises from the first and second division of the trigeminal nerve and from autonomic plexuses (3).

We here describe two cases of neurofibroma of the nasal cavity.

CASE REPORTS

CASE 1

A 68-year-old female patient complained of a slightly progressive right monolateral nasal obstruction and a later slowly growing mass in the right nostril for 6 months. She

also suffered from periodical right side epistaxis and intensive watery leakage from the nos. A biopsy was taken and diagnosis was made on the basis of histopathology. Anterior and posterior rhinoscopy showed a polypoid, firm, reddish lesion filling the right nasal cavity and extending to the nasal septum medially and the choana posteriorly (Fig 1).

Figure 1

Figure 1: Anterior (A) and posterior (B) rhinoscopy with polypoid, firm, reddish lesion filling the right nasal cavity and extending to the nasal septum medially and the choana posteriorly.

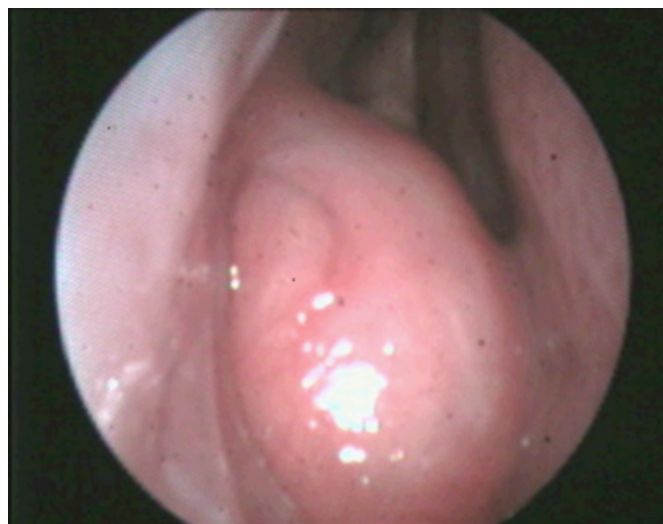
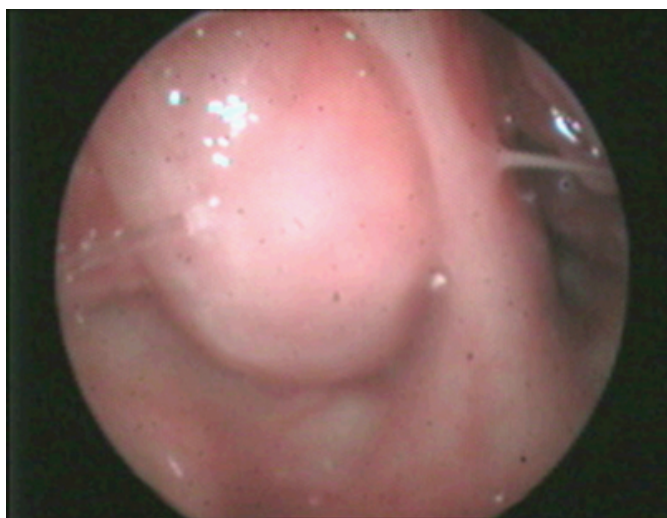


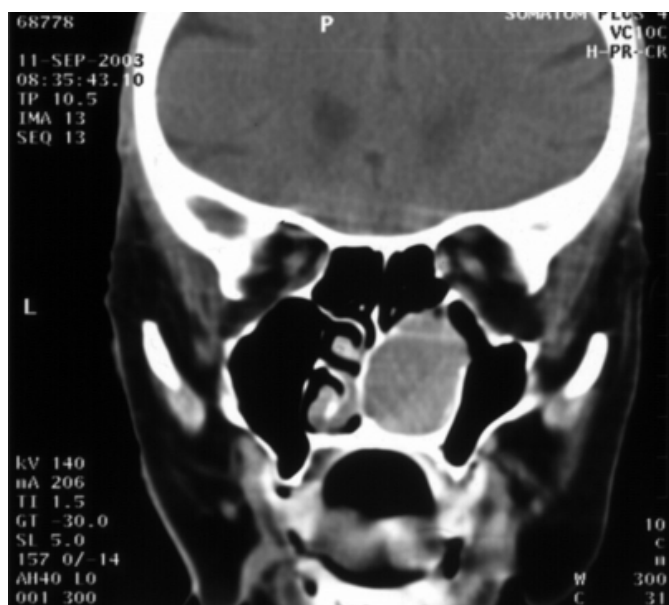
Figure 2



Computerized tomography (CT) revealed soft tissue, a homogenous mass without calcification or obvious necrosis in the right nasal fossa at the level of middle turbinate that enhanced uniformly after an endogenous injection of contrasting medium (Fig 2).

Figure 3

Figure 2: Coronal CT image shows a tumour of the right nasal cavity enveloping the septum medially.



The nasal septum was displaced to the left and the lateral wall of the right nasal cavity was pushed laterally. The lesion appeared to give no evidence of invading the surrounding structures. Paranasal sinuses were free of disease. Maximal size of the tumour was 2.3 x 3.0 x 4.0 cm. The slow growing behavior and lack of aggressive appearance on imaging study indicated benign character of

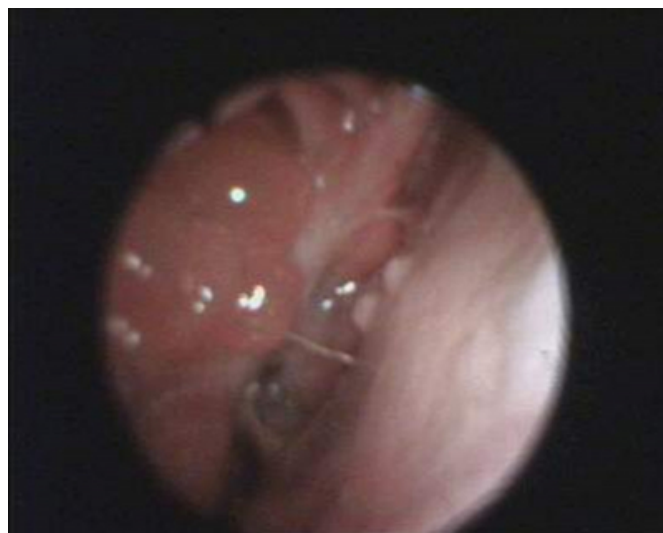the tumour. Excision of the mass was performed using external approach. The lesion was adherent to the septum and lateral wall of the right nasal cavity. The postoperative course was uneventful. The follow-up visit ten months after therapy revealed no local recurrence so far.

CASE 2

A 46-year-old woman was admitted to our department in January 2003 with a whitish, smooth-surface polypoid mass in the right nasal cavity at the level of middle turbinate (Fig 3).

Figure 4

Figure 3: Anterior rhinoscopy revealed irregular, polypoid masse in the right nasal cavity at the level of middle turbinate.



The patient had undergone right side, unilateral polypectomy four years earlier in another hospital, with unknown histopathological diagnosis. The lesion was almost asymptomatic and the patient was suffering only from mild nasal obstruction. On CT scanning it appeared as a soft-density mass filling the right upper meatus, involving the part of maxillary sinus, ethmoid and sphenoid sinus. Partial destruction of the lateral wall of right orbita and nasal cavity was seen. Magnetic resonance imaging (MRI) revealed irregular mass in the right nasal cavity reaching the middle turbinate and occupying completely right ethmoid and sphenoid sinus. The right maxillary sinus was full of fluid. The lateral orbital wall was preserved and displaced to the right by tumour. There was no evidence of extension of the lesion into the orbita or intracranial compartment. The patient underwent complete surgical excision of the tumour with resection of the orbital floor and ethmoid and sphenoid sinuses. The postoperative course was uneventful. There has

been no evidence of recurrence of the mass to data after two years.

DISCUSSION

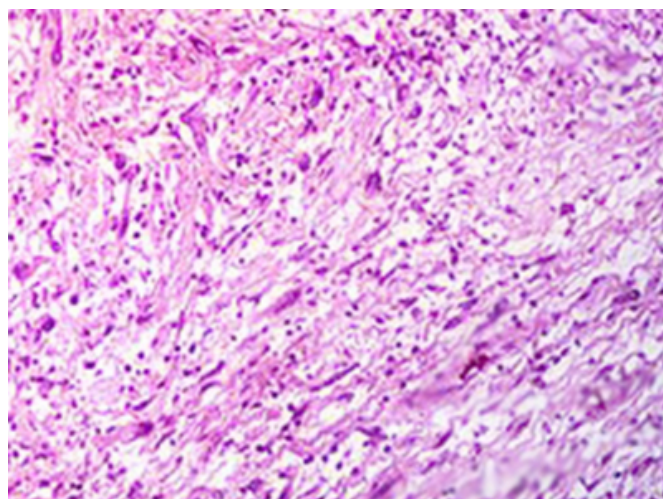
Neurofibroma is localized, benign peripheral nerve sheath tumors caused by abnormal proliferation of Schwann cells. There is no sex predilection for neurofibromas and they commonly occur in the third or fourth decades of life. Solitary neurofibroma arises along a nerve trunk, occurring as spontaneous lesion. The tumours are frequently centrally located, and are usually nontender. Infrequency in the occurrence of neurofibromas in nasal cavity and paranasal sinuses might be surprising considering the fact that neurofibromas are found with moderate frequency elsewhere in the body and are most commonly seen in the skin and subcutaneous tissue. Only a relatively small number of Schwann cell tumors including neurofibromas, involving upper respiratory system have been reported in literature. In most papers only one or two cases are described (3, 4, 5, 6). Involving the upper respiratory passages, neurofibromas usually produced symptoms varying according to the site and the size of the tumour. The most common symptoms are nasal obstruction, epistaxis, mucopurulent rhinorrhea, hyposmia and pain. Lesion involving the paranasal sinuses often led to swelling in the facial or orbital area. The differential diagnosis of the nasal tumors might include lymphoma, inverted papilloma, intranasal extension of juvenile angiofibroma, meningioma, neurofibroma, neurilemmoma, enchondroma, septal dermoid, idiopathic midline granuloma, squamous cell carcinoma, chondrosarcoma, esthesioneuroblastoma, and malignant neurilemmoma.

In neurofibromas, contrary to neurilemmomas, malignant transformation is reported to be at the rate of 10%, which presses the pathologist to differentiate between these tumours (7). Because of distinctive histologic appearance it is usually not difficult to make a diagnosis. Problems may arise in differentiating between neurilemmoma and neurofibroma in small biopsy or curettage specimens when additionally it is difficult to determine if a lesion is encapsulated. Adequate biopsy or specimens sufficient for macroscopic and microscopic examination, and immunohistochemical studies are essential for exact diagnosis (8). Neurilemmomas have a capsule; neurofibromas are generally not encapsulated and usually interdigitate with adjacent tissue. Neurons don't traverse schwannomas, in neurofibromas axons are seen to transverse the tumour mass. Neurofibromas frequently have a variable myxoid stroma in which fine wavy fibrils can be

found. Neurofibromas with myxoid changes may be difficult to differentiate from the myxomas that involve facial bones. Histologically, neurofibromas consist of interlacing bundles of elongated cells with wavy and dark-stained nuclei, wire-like strands of collagen, and myxoid stroma dotted with occasional mast cells and lymphocytes (1) (Fig. 4).

Figure 5

Figure 4: Hematoxylin-eosin-stained section of neurofibroma.



Immunohistochemically, neurofibroma shows immunoreactivity of S-100 protein, neuron specific enolase (NSE), and vimentin but not for desmin, or smooth muscle actin what may be useful in differentiating between neurofibroma and other tumors.

Benign Schwann cell tumours, arising in the upper respiratory passage, may cause bone erosion available to demonstrate by CT examination. Neurofibromas can infiltrate locally even into bone and can lead directly to bone resorption. Therefore bone erosion does not necessarily indicate the presence of a malignant lesion. High resolution CT scanning in various projections is thought to be the best imaging investigation for neurofibromas. Preoperative evaluation CT, however, allows us to reveal the pushing borders of the tumors, rather than the invasive character of malignancy. MRI with gadolinium contrast is indicated in areas with intraorbital or intracranial extension, and for more exact delineation of the tumor from the normal soft tissue (9). Furthermore, MRI is helpful in differentiating the neoplasm from retained secretions or inflammatory changes within the sinuses and nasal cavity. In patients with multiple neurofibromatosis known as von Recklinghausen's disease, the diagnosis of Schwann cell tumour is indicated clinically.

The mainstay of the treatment is complete surgical excision of the tumour because neurofibromas may infiltrate extensively. When resecting neurofibromas from the upper respiratory tract radical surgical resection is rather not required. Benign neoplasms arising from the lateral nasal wall and the paranasal sinuses are treated by surgical procedures such as lateral rhinotomy, extended ethmoidectomy or partial maxillectomy. The type of operation employed is dependent on the extent and the location of the tumour. During the operation functional and cosmetic effects should be considered, however, in locally advanced cases, extensive operation should be performed. Transnasal endoscopic resection is useful if the neurofibroma is solitary and located in the nasal cavity and the origin can be identified. Some authors have published very good outcomes after endoscopic surgery with no signs of recurrence (5, 6). It is important to visualize the origin of the tumour, which allows macroscopic complete resection under endoscopy. However, if the operative findings make it impossible to excise the neoplasm completely by endoscopic means, the surgeon should be prepared to convert to open surgical procedures. If not excised completely, neurofibromas may recur locally and require further local resection. Recurrence of this tumour is rather rare, although more common than schwannoma.

CORRESPONDENCE TO

Marcin Fraczek Dept & Clinic of Otolaryngology Wrocław

Medical University Chalubinskiego Street 2 51-368
Wrocław, Poland e-mail: raucedo@wp.pl Tel.:
+48717842512; fax: +48713270950

References

1. Batsakis JG. Tumours of the peripheral nervous system. In: Batsakis JG, ed. *Tumours of the Head and Neck, Clinical and Pathological Considerations*. 2nd edn: Baltimore: Williams and Wilkins 1976;313-333.
2. Wilson JA, McLaren K, McIntyre MA, von Haacke NP, Maran AGD. Nerve-sheath tumours of the head and neck. *Ear Nose Throat* 1988;67:103-10.
3. Agarwal MK, Gupta OP, Samant HC, Grupta S. Neurofibroma of the maxillary antrum. *Oral Surg* 1979;48:150-152.
4. Annino DJ Jr, Domanowski GF, Vaughan CW. A rare cause of nasal obstruction: a solitary neurofibroma. *Otolaryngol Head Neck Surg* 1991;104(4):484-488.
5. Hirao M, Gushiken T, Imokawa H, Kawai S, Inaba H, Tsukuda M. Solitary neurofibroma of the nasal cavity: resection with endoscopic surgery. *J Laryngol Otol* 2001;115(12):1012-4.
6. Yong DK, Chang HB, Jang SS, Kei WS. Transnasal endoscopic excision of an isolated neurofibroma of the nasal septum. *Rhinology* 1997;35:89-91.
7. Robbins SL, Cotran RS, Kumar V. The nervous system. In: Robbins SL, Cotran RS, Kumar V, eds. *Pathologic Basis of Disease*, Philadelphia: WB Saunders Co 1984;1432-3.
8. Perzin KH, Panyu H, Wechter S. Nonepithelial tumors of the nasal cavity, paranasal sinuses and nasopharynx. A clinicopathologic study. XII: Schwann cell tumors (neurilemoma, neurofibroma, malignant schwannoma). *Cancer* 1982;50(10):2193-202.
9. El-Saggan A, Olofsson J, Krossnes B. Sinonasal schwannoma: two case reports and review of literature. *International Congress Series* 2003;1240:503-507.

Author Information

Marcin Fraczek, Ph.D.

Department & Clinic of Otolaryngology, Wroclaw Medical University

Maria Zalesska-Krecicka

Professor, Department & Clinic of Otolaryngology, Wroclaw Medical University

Tomasz Zatonski, Ph.D.

Department & Clinic of Otolaryngology, Wroclaw Medical University

Tomasz Krecicki

Professor, Department & Clinic of Otolaryngology, Wroclaw Medical University