

Bilateral Congenital Capitate-Trapeziod-Trapezium Fusion

J Ogunlusi, R St. Rose, T Davids

Citation

J Ogunlusi, R St. Rose, T Davids. *Bilateral Congenital Capitate-Trapeziod-Trapezium Fusion*. The Internet Journal of Radiology. 2007 Volume 8 Number 2.

Abstract

This case report is about an 18year old male patient with mild left wrist pain of no known preceding aetiology. Through and general examination of the patient shown normal vital signs and no bony or visceral anomaly. Anterio-posterior X-ray view of the left wrist shown capitate-trapeziod-trapezium fusion. A comparative X-ray views of the right wrist shown capitate-trapeziod-trapezium fussion.

This is a very rare fusion which has not be previously reported in any English literature and tells the importance of evaluating the both wrists radiologically even when there is no history of trauma in order no to miss the diagnosis of rare carpal fusions.

INTRODUCTION

Carpal bone coalition is uncommon and occurs as normal variations in about 0.1% of the population. ¹ Carpal coalition results from incomplete cavitation of a common embryologic carpal precursor during the fourth to eighth weeks of intrauterine life. ² The osseous centers of the involved bones coalesce at variable ages usually between six and 15 years of age. ¹ It is commoner in the African and African descends. ^{2,3}

The mode of inheritance is through genetic factors, the trait being transmitted as Mandelian dominant. ³ Presentation could either the asymptomatic and detection is usually incidental or it could be associated with other syndromes and anomalies. Below is a rare presentation of bilateral capitate-trapezoid-trapezium carpal fusion in a young African descend.

CASE REPORT

An 18 year old male presented in the accident and emergency with a two day history of left wrist pain. There was no history of trauma and no history of any known preceding factor. Aggravating factor was movement and this was the first episode. Through and general examination of the patient did not reveal any bony or visceral anomaly and the vital signs were normal. There was no swelling but mild tenderness on the volar surface of the wrist. Anterio-posterior X-ray view of the left wrist shown capitate-trapeziod-trapezium fusion. A comparative X-ray views of the right wrist shown similar capitate-trapeziod-trapezium fusion. He was treated with analgesic to which he responded

satisfactorily. The X-rays of both wrists are shown in the figures 1 and 2 below.

Figure 1

Figure 1: Left wrist showing the fusion

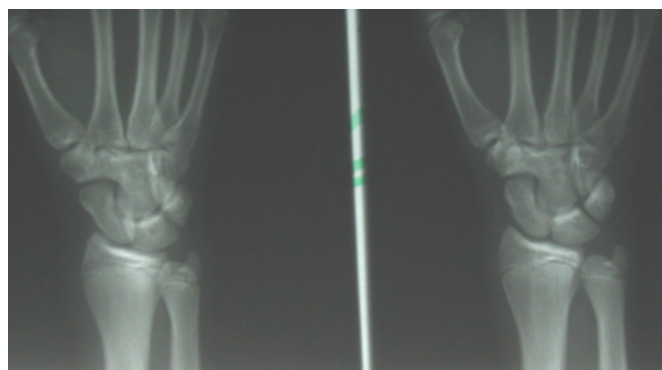
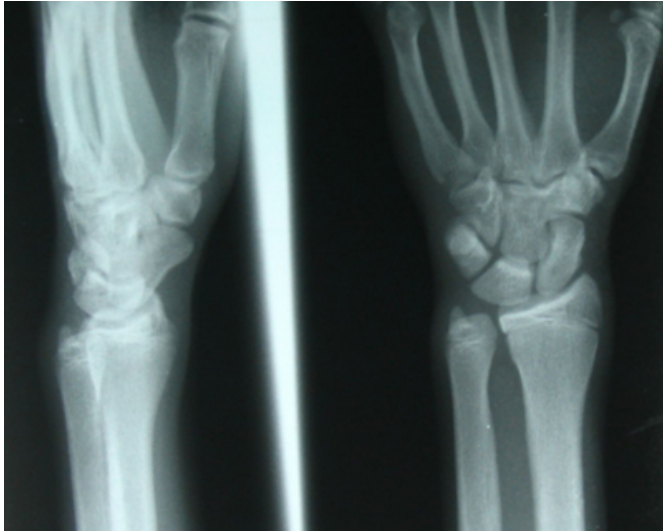


Figure 2

Figure 2: Right wrist showing the fusion



DISCUSSION

Capitate-trapeziod-trapezium fusion is a rare carpal fusion type of carpal fusion and the bilaterality of this case makes it quite interesting and reportable. Review of English literature did not show similar reported case. Unilateral combination of scaphoid, trapezium, trapezoid and capitate fusion was the closest that was found on literature review.⁴ This case report was in a West Indian who is of African descent which support the authors^{2,3} that stated that carpal fusion are commoner in Africans and African descends.

Congenital of carpal bones fusion is usually a chance finding discovered on radiographs obtained for unrelated reasons seen in otherwise normal people. Symptomatic presentations have also been noted as carpal tunnel syndrome and ulnar nerve neuropathy especially pisiform- hamate fusion.^{5,6} Most cases of isolated carpal coalition are asymptomatic although pain has been observed in some cases.¹ This patient is one of the few that could present with pain due to the coalition although the contralateral wrist was symptom free. The diagnosis of this very rare pathology was made possible by the simple X-ray of both hands. The X-ray of the symptom free wrist shown capitate-trapeziod-trapezium fusion thus we suggest that both wrist should always be X-rayed in order not to miss the carpal coalitions.

Presentation is commonly as an isolated entity but may occur as part of syndrome or may be associated with metabolic disorders.³ In this patient this was an isolated finding and there were no associated congenital anomalies in this young and healthy looking man. Congenital carpal bone coalition has been associated with different types of

syndromes which are Ellis-van Creveld Syndrome, Holt-Oram Syndrome, Turner's syndrome, Nievergelt's Syndrome, Arthrogryposis Multiplex, Congenita Symphalangism, Oto-Palato Digital Syndrome, Hand-Foot-Uterus Syndrome, Osteochondritis Dissecans, Diastrophic Dwarfism, Tarsal coalition, acrocephalosyndactyly syndrome and Kabuki make-up syndrome.³ Carpal coalition is also sometimes associated with ray anomalies in the hand and spondylocarpotarsal synostosis syndrome (SSS).^{3,7} This patient nor any member of his family do not suffers from any form of above syndromic pathologies, thus carpal coalition even bilateral coalitions can occur as isolated cases.

There are different types of the carpal bone coalition, these are as mentioned below

Lunate-Triquetral Fusion - This is the most common fusion anomaly of the carpal bone coalition.² Among the various population groups studied the highest incidence is seen in people of African descent with a greater predilection of female to male (2;1) and strong familial tendency. In the African continent the maximum incidence is on the West coast, particularly Nigeria. In the American population the estimated incidence falls between 0.08% - 0.13%.⁸ Other rarer types in order of frequencies are Capitate-Hamate Fusion which is far more frequent in Negroes and is more frequently bilateral, Capitate-Trapezoid Fusion and Pisiform-Hamate Fusion.^{1,3} An unusual case of congenital complete entire carpal coalition with massive carpometacarpal coalition has also been reported.⁹ The capitate-trapeziod-trapezium fusion is quite rare and rarer is it bilaterality, thus this case report.

Conclusively we want to say that it is important to evaluate the wrists radiologically even when there is no history of trauma in order not to miss the diagnosis of rare carpal fusions.

CORRESPONDENCE TO

Johnson Dare Ogunlusi Consultant Accident and Emergency / Orthopaedic Surgeon & Traumatologist, Victoria Hospital, Castries. St Lucia. West Indies. E mail: gbemidare@yahoo.com

References

1. Hosalkar HS, Shaw BA, Carrie LC, Read H. Bilateral congenital capitate-hamate fusion. *Images in radiology*. 2001 Vol. 47(3) 208-9
2. Delaney TJ, Eswar S. Carpal coalitions. *J Hand Surg (Am)*. 1992 Jan;17(1):28-31.

3. Singh P, Tuli A, Choudhry R, Mangal A. Intercarpal Fusion- A Review: J Anat. Soc. India. 2003;52(2):183-188
4. Ingram C, Hall RF, Gonzalez M. Congenital fusion of the scaphoid, trapezium, trapezoid and capitate. J Hand Surg [Br]. 1997 Apr;22(2):167-8.
5. Tsionos I, Drape JL, Le Viet D. Bilateral pisiform-hamate coalition causing carpal tunnel syndrome and tendon attrition. A case report. Acta Orthop Belg. 2004 Apr;70(2):171-6
6. Berkowitz AR, Melone CP Jr, Belsky MR. Pisiform-hamate coalition with ulnar neuropathy. J Hand Surg [Am]. 1992 Jul;17(4):657-62.
7. Breitling M, Lemire EG, Rabin M. Spondylocarpotarsal synostosis syndrome: MRI evaluation of vertebral and disk malformation. Pediatr Radiol. 2006 Aug;36(8):866-9.
8. Szaboky, GT, Muller J, Melnick J, Tamburro R. Anomalous fusion between the lunate
9. Journal of Bone and Joint Surgery [Am]. 1969;51: 100-1004.
10. Tuncay I, Akpınar F, Unal O, Aydinlioglu A. Total bilateral carpal coalition with carpometacarpal fusion: one case. Rev Chir Orthop Reparatrice Appar Mot. 2001 Nov;87(7):724-6

Author Information

Johnson Dare Ogunlusi, FMCS (Ortho)

Consultant Accident and Emergency / Orthopaedic Surgeon & Traumatologist, Victoria Hospital

R. St. George B. St. Rose, FRCS (Edin)

Consultant Orthopaedic Surgeon, Victoria Hospital

Tamunotoyen Davids

Medical Officer, Victoria Hospital