

Thalo Navicular Arthrodesis Of Steinhæuser In Senegal

E CAMARA, A Bousso, M TALL

Citation

E CAMARA, A Bousso, M TALL. *Thalo Navicular Arthrodesis Of Steinhæuser In Senegal*. The Internet Journal of Orthopedic Surgery. 2009 Volume 15 Number 2.

Abstract

INTRODUCTION

An isolated arthrodesis from the line space of Chopart results from experimental study carried out by Steinhæuser and its implementation/practice as described in the book he wrote in 1978. It has proven the significance of the line space of Chopart in the restoration from foot malformations/deformities.

When Chellius (1), repeated the cadaveric experimentation of Steinhæuser, he could draw the conclusion that blockade of talo navicular articulation /joint is sufficient to lock the back of the foot /back foot, and that calcaneo cuboidian blockade does not have any additional effect. These conclusions are confirmed by a clinical study carried out by . (ASENCIO and all.?) (2)

Chopart arthrodesis has two major indications in Africa: In Africa the arthrodèse/artthrodesis of Chopart finds two principal indications: the painful post-traumatic foot and the distorted poliomyelitic paralytic foot.

MATERIAL

From 1997 through 2003, 55 navicular tolo arthrodesis also called Chopart arthrodesis were performed. The age range of patients is 16 to 40 years and the average, 18 years. At total of 40 males and 15 female patients underwent the procedure.

Characteristics of two categories of patients:

35 post traumatic arthrodesis;

20 neurological feet

Only the talo navicular arthrodesis is performed in case of traumatic lesions while athrodesis of all the line space of Chopart is performed in case of neurological feet, in/within/on the sequelae of former acute poliomyelitic.

METHOD

The technique is simple and is performed under a loco-

regional anaesthesia with rachis anaesthesia in case of adhering iliac graft or with a poplite bloc, pneumatic garrotes on the calf. A dorso-median longitudinal incision is made between the anterior tibial tendon and extensors.

A second latero-longitudinal incision is necessary for the calcaneo cuboidienne arthrodesis

Figure 1

Photo I : chopart's internal access

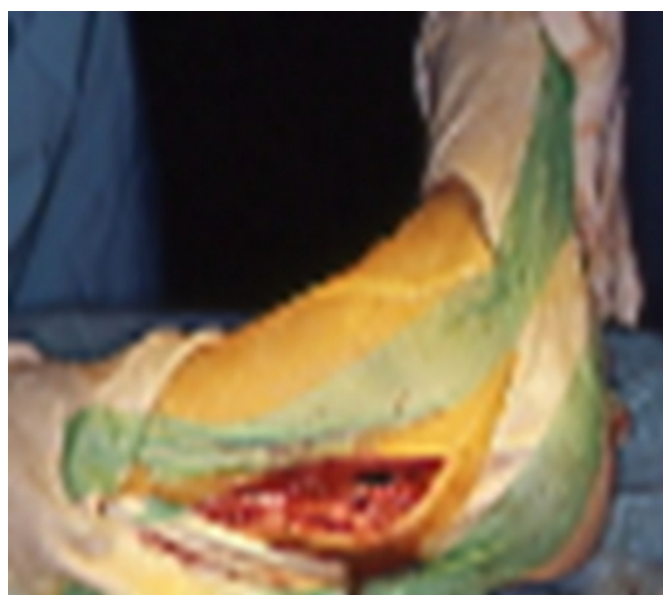
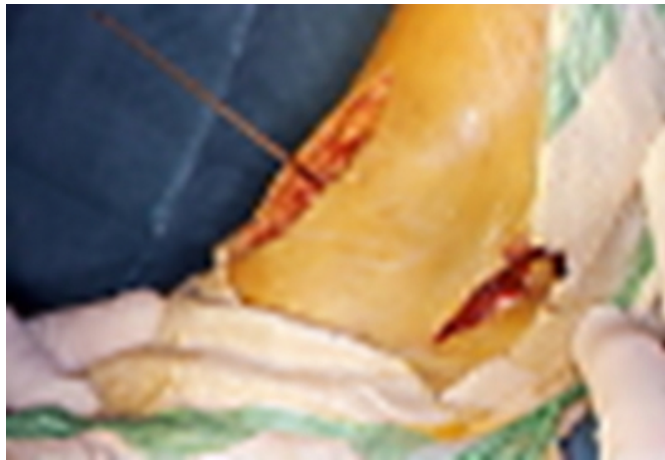
Figure 2

Photo II : chopart's double Extension by internal and external access with fixing of location

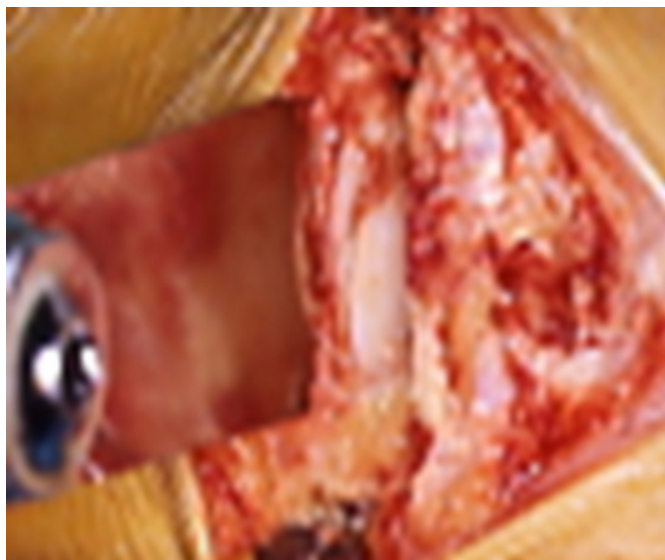

The radiographic location by pin/ on the line space of Chopart is necessary because of the local modifications of the talo navicular articulation/joint. In fact, the naviculo cuneiforme joint/articulation is the only one that possesses most common features with the talo navicular joint.

It is better to make a cut with an/the oscillating saw, rather than only a joint revivement the fusion of which is appears doubtful .

Figure 3

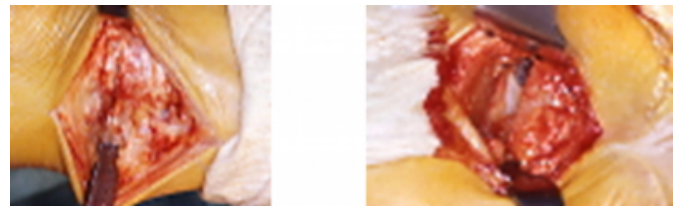
Photo III : chopart's osteotomy of correction



In the talo naviculaires arthrodesis, we filled the resection space 18 times with a graft in order to maintain the length of the first ray

Figure 4

Photos IV and V : External and internal view after with oscillating saw reducing the deformity by fixing an iliac graft



In the large/great majority of cases (of arthrodesis cases) concerning all the line space of Chopart, we do not use any graft. In fact, the corrective cuneiform (wedge-shaped) resection goes into contact with two flat surfaces which fuse, obviously with a shortening of the affected foot.

In case of equinism sub-cutaneous tenotomy procedure allows the lengthening of the “ tendon d'Achilles”, enabling its correction/restoration/bringing back to normal

Figure 5

Photo VI : Achilles tendon's



After the surgery procedure, immobilization is maintained in a plaster. The duration of immobilization has gradually

reduced to become six weeks with pressure allowed on the 15th day with no relaxation (lost of stability) of fixing that is provided by the use of a staples

RESULTS

In 15 cases of talo naviculaire arthrodesis, parallel resection enabled bone fusion without interposition of the graft and without calcaneo cuboidian repercussion.

Indolence is observed in all post-operational cases. Two cases of painful recoveries with inflammatory push were observed, however. Correction of club-feet was properly achieved with interposition of iliac graft.

COMPLICATIONS

We observed 8 cases of cutaneous necrosis which were healed with a local therapy /treatment.

Arthrodesis fusion is completed in 80% of cases. We also noted absence of fusion in club-feet varus equin post-poliomyelitic in six cases. This was very likely associated to poor blood supply/vascularization.

FUNCTIONAL RESULTS

The functional results were judged on the base of residual pains and the walking perimeter, the criteria defined by TOMENO (3), (although they were associated with tibio tarsian arthrodesis, and on the quantified quotation of DUQUENNOY (4). Overall, 75 to 78% of good functional results was observed.

Normal shoe wearing was satisfactory in the majority of cases, three of which were associated with an orthopedic sole. Three patients continued to wear the orthopedic shoe they have been using before the procedure, with correction to the incorporated plantar orthosis, however.

Walking on a leveled ground is satisfactory in only 15 out of 55 cases of arthrodesis. This is associated with a constraint due to loss of the function of adaptation to the ground by the torque, and reciprocal play of the dynamic astragalian foot, and the static calcaneal foot.

DISCUSSIONS

Some authors TOMENO (3) EL BAOR (5) use the median approach to avoid cutaneous necrosis with articular surface revivment. For us we remain faithful to the dorso-median way, talo navicular and lateral calcaneo cuboidian which allow better adjustment of resection and correction of deformities/. Radiological location is essential as confirmed/testified/proven by FOGEL (6).

Despite the good stabilization of the torque by the talo navicular arthrodesis, therefore, micro-movement may persist as recalled by ASENSIO (2), with no evolutionary malformation of the back foot, according to some authors, with a retreat ranging between 5 and 9 years (5,6).

According to Steinhäuser, inconvenience associated with arthrodesis is due to its efficacy. In fact it totally stiffens the back foot which interferes with (affect) foot adaptation on leveled ground, as it is the case with all surgical techniques/protocols employed in this type of pathology.

CONCLUSIONS

Talo navicular arthrodesis or that of the all the line space of Chopart, makes it possible to obtain a correction of malformation in case of post poliomyelitic affected foot and, indolence in case of painful post-traumatic foot.

References

1. Chellius ph. Gerard Y. le blocage des mouvements de l'articulation sous astragalienne par arthrodèse astragalo scaphoïdienne REV CHIR ORTHOP SUPPL -1986, II 72 104-108
2. Ascencio., Roeland A. Megy B., Bertin R., Fougue E. et Leclerc V. Stabilisation de l'arrière pied par arthrodèse astragalo scaphoïdienne. Résultats à propos de 50 cas. REV. CHIR. ORTHOP. 1995 81 691-701
3. Tomeno B., Broquin J., Emani A., Maurer P. Arthrodèses tibio tarsienne. Complications et tolérance a propos de 134 cas. REV. CHIR. ORTHOP 1979, 65, 393-401
4. Duquenois A., mestdagh H. Tillie B et stahl ph propos de 52 cas. Revue REV. CHIR. ORTHOP 71, 251-261
5. ELbaor J.E THOMAS WH, WEINFELD M.S, Porter T.A, Talo Navicular arthrodesis for rheumatoid of the hindfoot. ORTHOP CHI North, AM 1976, 7 – 821-826
6. FOGEL G.R, Katon Y., Rand J.A, CHAO EYS – talo navicular arthrodesis for isolated arthrosis : 9,5 year results and gait analysis. Foot ankle 1982, 13, 105-113

Author Information

El Hadj Souleymane CAMARA

Senior Lecturer, Orthopedic and Traumatology Department, General Hospital of Grand-Yoff

Abdoulaye Bousso

Orthopedic and Traumatology Department, General Hospital of Grand-Yoff

Mouhamed TALL

Orthopedic and Traumatology Department, General Hospital of Grand-Yoff