

# Testicular Metastasis From Adenocarcinoma Of The Prostate

S Chhabra, M Singh, A Bal, H Mohan

## Citation

S Chhabra, M Singh, A Bal, H Mohan. *Testicular Metastasis From Adenocarcinoma Of The Prostate*. The Internet Journal of Surgery. 2006 Volume 9 Number 1.

## Abstract

Secondary testicular tumors are very rare. Metastatic deposits in the testes from prostatic adenocarcinoma, although rare, have been reported. Other common primary sites include lungs, kidneys, colon, and stomach. We report a case of testicular metastasis from adenocarcinoma of the prostate.

## INTRODUCTION

Metastatic spread to the testis from prostatic adenocarcinoma is rare. Usually cancer of the prostate spreads to the regional lymph nodes, bones, liver and lung.<sup>1</sup> The English literature reveals only 76 cases of adenocarcinoma of the prostate metastasising to the testis until 2000, eventually there have been isolated case reports.<sup>2,3</sup>

## CASE REPORT

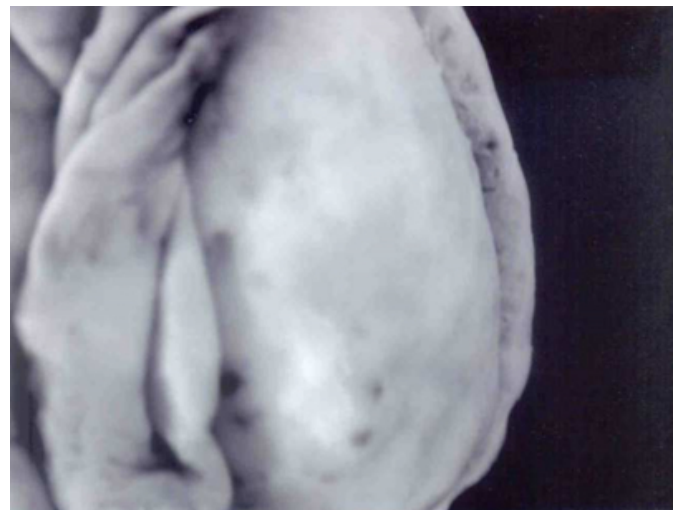An 82 year old man of Indian origin was admitted in the hospital with complaints of urinary retention, swelling in the right inguinal region and slight enlargement of the right testis. On ultrasound and CT scan, diagnosis of carcinoma of the prostate was suggested. Serum P.S.A levels were 49.5 ng/ml (normal 4 ng/ml). Needle biopsy of prostate on histopathological examination revealed adenocarcinoma of the prostate. Subsequently, therapeutic bilateral orchiectomy was done.

## PATHOLOGICAL FINDINGS

On gross examination the right testis measured 5 x 3.5cm and was externally nodular. Cut section showed multiple tiny gray white areas scattered diffusely in the testicular parenchyma (Fig.1).

## Figure 1

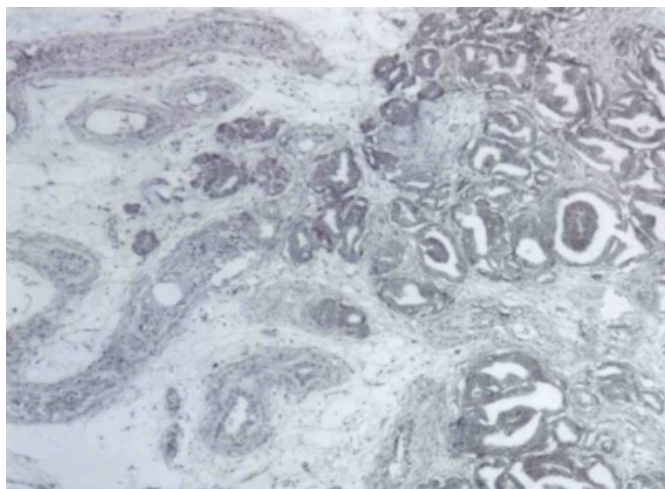
Figure 1: Gross photograph showing nodular external surface of the testis.



Left testis measured 4 x 2.5 cm and was unremarkable externally as well as on cut section. On histological examination, the right testis showed atrophy of the testicular parenchyma and presence of areas of well to moderately differentiated adenocarcinoma in the interstitium (Fig.2 & 3). Histological examination of left testis showed atrophied parenchyma but no metastatic tumor deposits were identified.

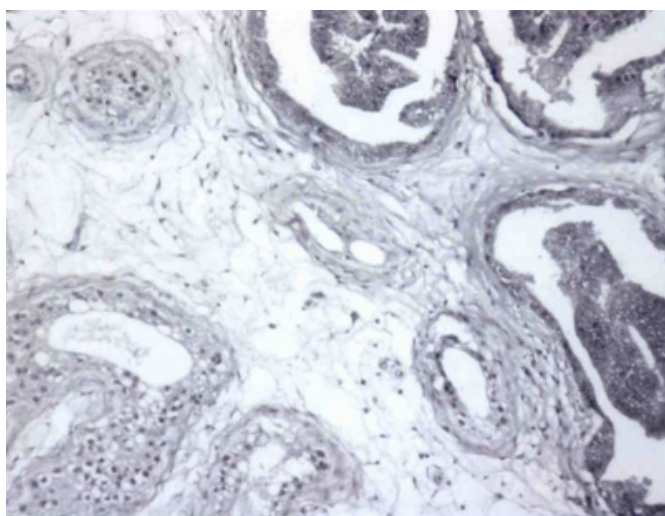
**Figure 2**

Figure 2: Photomicrograph showing metastatic prostatic adenocarcinoma in testis (H & E, x100).



**Figure 3**

Figure 3: Photomicrograph showing metastatic adenocarcinoma in the testis, while one area shows atrophied seminiferous tubules (H & E, x400).



### DISCUSSION

Tumor metastasis to the testes is extremely uncommon. In the literature there have been 236 case reports of different cancers metastasising to the testes. Of these 76 (32%) were

from prostatic adenocarcinoma<sub>2</sub>. Semans (1938) was the first to describe metastasis of prostatic carcinoma to the testis<sub>4</sub>. Clinical picture of the testis showing metastatic adenocarcinoma from the prostate is inconsistent. There are often no symptoms and signs of the spread and diagnosis is often made on histopathological examination of therapeutic bilateral orchiectomy specimen or at post-mortem examination<sub>5</sub>. In our case the patient had right inguinal swelling and the right testis was slightly enlarged.

Five possible routes have been proposed by which the prostate cancer spreads to the testis: arterial embolism, retrograde venous extension, retrograde lymphatic spread, direct extension and through the lumen of vas<sub>6</sub>.

Whatever the route of spread, testicular metastatic deposits from adenocarcinoma prostate are accepted as a sign of advanced disease<sub>7</sub>. In asymptomatic cases, histopathological examination confirms the diagnosis.

### CORRESPONDENCE TO

Dr. Harsh Mohan, Professor and Head Department of Pathology, Govt. Medical College, Sector-32-A, Chandigarh-160030, India. Phone 91-0172-2665375 E-mail drharshmohan@yahoo.com Fax: +91-172-2665375

### References

1. Kirkali Z, Reid, Deane RF, Kyle F. Silent testicular from carcinoma of the prostate. B'r J Urol 1990; 66: 205-07.
2. Berkman F, Ayyildiz A, Ardicoglu A. Testicular metastasis from adenocarcinoma of the Prostate: review of literature and report of two cases. The Prostate Journal 2000; 2: 42-44.
3. Gunlusoy B, Arslan M, Selek E, Cetinel M, Ayder AK Cicek S. Prostatic carcinoma with metastasis to the testicle: a case report. Int Urol Nephrol 2003; 36(1): 63-64.
4. Semans IH. Carcinoma of the prostate with metastasis to the testis. J Urol 19J8: 40: 524-27.
5. Moskowitz B, Kerner H, Levin DR. Testicular metastasis from carcinoma of the prostate. Urol Int 1987; 42: 79-80.
6. Johansson JE, Lannes P. Metastasis to spermatic cord, epididymis and testicles from carcinoma of the prostate-five cases. Scand J Urol Nephrol 1983; 17: 249-51
7. Denes FT, Brito AH, Santos AMD. Subcutaneous and testicular metastasis from prostatic adenocarcinoma with neuroendocrine differentiation. Braz J Urol 2001; 27:52-54.

**Author Information**

**Seema Chhabra, M.D.**

Department of Pathology, Govt. Medical College

**Monica Singh, M.D.**

Department of Pathology, Govt. Medical College

**Amanjit Bal, M.D.**

Department of Pathology, Govt. Medical College

**Harsh Mohan, M.D>**

Department of Pathology, Govt. Medical College