

# Use Of SPECT In Diagnosis And Follow-Up After Steroid Treatment Of Retroperitoneal Fibrosis

C Sala-Mateus

## Citation

C Sala-Mateus. *Use Of SPECT In Diagnosis And Follow-Up After Steroid Treatment Of Retroperitoneal Fibrosis*. The Internet Journal of Internal Medicine. 2004 Volume 5 Number 2.

## Abstract

Retroperitoneal fibrosis is an entity with an unknown cause. It is characterized by inflammation of the retroperitoneal structures and fibrosis. This case report demonstrates the use of SPECT imaging in the early noninvasive diagnostic work-up and follow-up evaluation after steroid therapy.

## INTRODUCTION

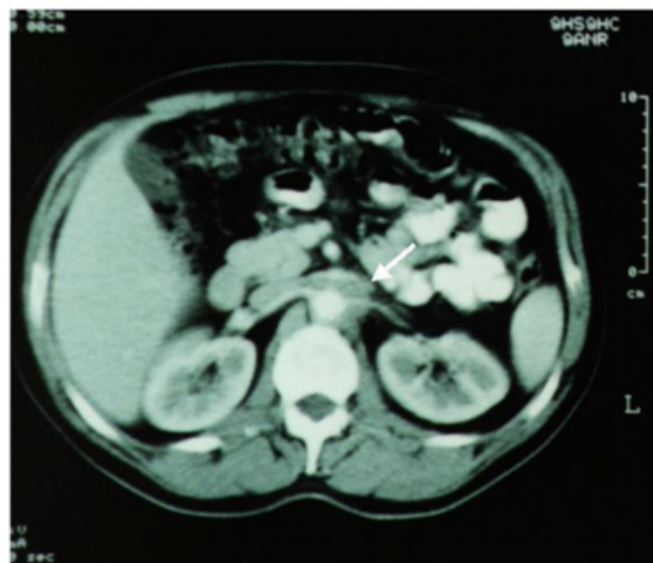
Retroperitoneal fibrosis is an uncommon condition, which has been described for many years. There is not a single diagnostic test with high specificity. Ga-67 scan will show intense periaortic activity in a number of inflammatory process. Its use in collaboration with findings on computed tomographic (CT) imaging can be diagnostic (<sub>1,2,3</sub>), and may be helpful in the follow-up after a trial of steroid therapy (<sub>4,5</sub>). This case suggests all this. However, this needs to be studied in a larger number of cases.

## CASE REPORT

A 46-year-old man was studied for evaluation of 3-month history of poorly localized back pain, with a good response to non-steroidal anti-inflammatory agents. He smoked one pack of cigarettes daily, he rarely drank alcohol, and there was no important medical history. General examination was normal. The routine laboratory tests showed mild elevated erythrocyte sedimentation rate (35 mm/h), C-reactive protein level (20 mg/L) and alkaline phosphatase (350 U/L). The remainder of the liver and renal function tests were normal, including the WBC count. Antinuclear antibodies, rheumatoid factor and antineutrophil cytoplasmatic antibodies were negative. HLA B-27 antigen was negative. Radiographs of the chest and abdomen were normal. Abdominal ultrasound study was report normal. A contrast CT study (fig.1) of the abdomen revealed a periaortic soft tissue attenuation mass surrounding aorta, at level of the renal vessels, with no discrete soft tissue masses and no evidence of an abdominal aortic aneurysm.

## Figure 1

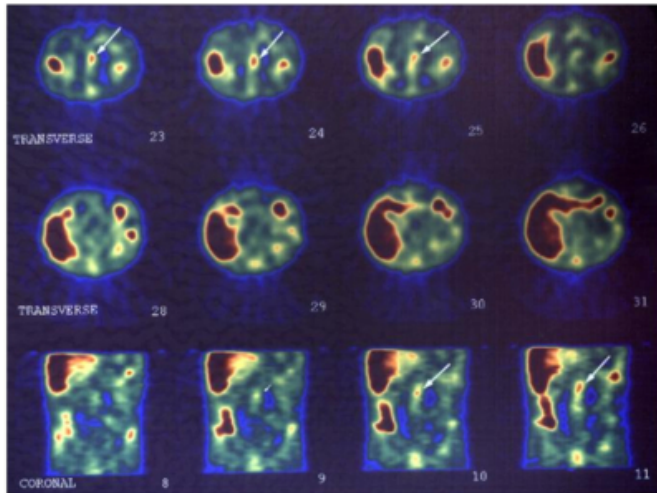
Figure 1: CT abdominal. The arrow show periaortic soft tissue attenuation mass surrounding aorta, at the level renal vessels.



Ga-67 imaging demonstrated midline abdominal focal activity on planar images at 48 hours, and in the SPECT images (fig.2) was localized at the aorta area, at the level kidneys.

**Figure 2**

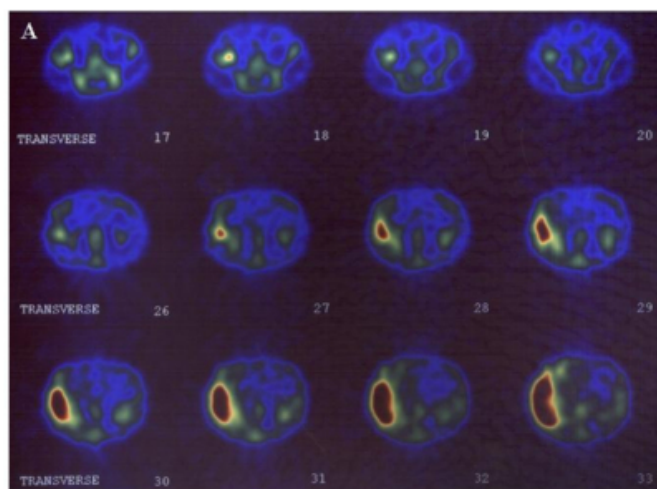
Figure 2: SPECT of the Ga-67 scan. The arrow show focal increased uptake.



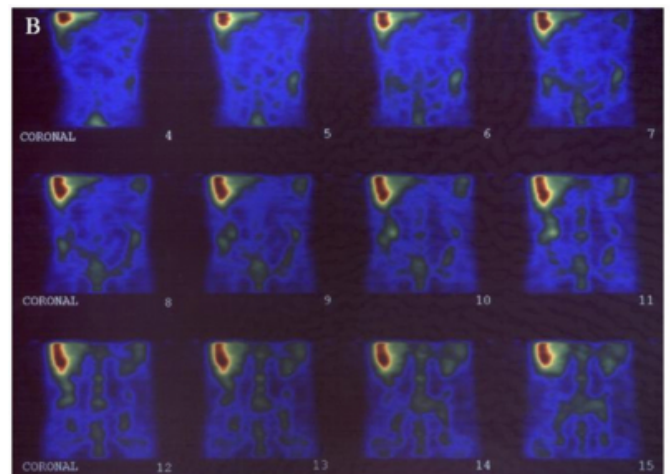
Both findings favoured the diagnosis of retroperitoneal fibrosis. The patient was considered a candidate for a trial of steroid therapy that consisted of prednisone with a dosage of 0,5 mg/kg/day the first month, and progressive reduction to anti-inflammatory dosage later. Clinically, the patient demonstrated dramatic improvement. Three months later, CT abdominal study showed evidence of a decrease in the retroperitoneal process, and SPECT images (fig.3, A and B) demonstrated resolution of the previously described increased uptake. Because surgery was not performed, tissue was not obtained for a pathologic diagnosis.

**Figure 3**

Figure 3: SPECT of the Ga-67 scan three months later (A: transverse, and B: coronal images).



**Figure 4**



## DISCUSSION

The exact aetiology of RPF, also called Ormond's disease, is unknown. About two-thirds of all cases of RPF seem to be idiopathic. The remaining one-third has been ascribed to other causes, such as drugs, haemorrhage, surgery, trauma, infection, aneurysm and certain tumours. A wide variety of theories has been proposed as a cause for idiopathic RPF. Various authors have equated RPF with an immune-mediated connective tissue disease, with fibrosis developing in response to leakage of ceroid from atheroma into periaortic tissue.

Retroperitoneal fibrosis is 2 to 3 times more frequent in males than females with a peak age distribution of between 30 and 60 years. The clinical presentation is protean (3). The symptoms are related to entrapment and compression of retroperitoneal structures. The commonest is poorly localized back pain. Other clinical findings include dull abdominal pain, nausea, weight loss, mild fever and malaise. The diagnosis is usually made late. The condition may at first be suspected during radiographic imaging of the retroperitoneum or abdomen. Retroperitoneal fibrosis usually involves the abdominal aorta and may extend beyond the aortic bifurcation at the origin of the common iliac vessels. This may extend into the true pelvis and superiorly into the mediastinum.

Previous reports of Ga-67 and CT imaging in retroperitoneal fibrosis demonstrate Ga-67 findings depicting increased radionuclide uptake within the retroperitoneum, indicating an inflammatory process in which the CT study showed a periaortic soft tissue mass with attenuation values similar to that of muscle. There may be enhancement after contrast administration (1,2,3,4), and it is not necessary with nuclear

magnetic resonance imaging (6).

Similar findings were demonstrated in this case, in which the patient was treated with corticosteroids with dramatic clinical improvement. The subsequent follow-up SPECT study showed resolution of the previously described increased uptake within the retroperitoneum. We believe that SPECT imaging is a useful and non-invasive radiologic procedure, not only in diagnosing the presence of retroperitoneal fibrosis, but also evaluating its response to corticosteroid therapy.

### **ACKNOWLEDGMENTS**

We thank Dr. M. Escobar, from the Servei de Radiologia of the Hospital Comarcal de Blanes, and Dra. M. Minoves, from the CETIR Centre Mèdic of Barcelona, for help with the radiological evidence.

### **CORRESPONDENCE TO**

Dr. Carlos Sala-Mateus  
C/ de la Cala Sant Francesc, 28  
17300 – Blanes (Catalonia). Spain

### **References**

1. Liebman RM. Positive gallium scan in retroperitoneal fibrosis. *AJR Am J Roentgenol.* 1983; 141: 949-950
2. Leibowich S, Tumei SS. Gallium-67 imaging and computed tomography in early retroperitoneal fibrosis. *Clin Nucl Med.* 1988; 13: 829-830.
3. Tomita Y, Morishita H, Saitoh R. Successful treatment of idiopathic retroperitoneal fibrosis with steroid administration in a patient with a positive gallium scan. *Clin Nucl Med.* 1993; 18: 1042-1044.
4. Talati SJ, Abghari R, Kochkodan JJ, Helmer SR. Use of Ga-67 Imaging in Diagnosis and Follow-Up After Steroid Treatment of Retroperitoneal Fibrosis. *Clin Nucl Med.* 1995; 20: 995-997
5. Vivas I, Nicolás AI, Velázquez P, Elduayen B, Fernández-Villa T, Martínez-Cuesta A. Retroperitoneal fibrosis: typical and atypical manifestations. *Br J Radiol* 2000; 73: 214-222
6. Hricak H, Higgins CB, Williams RD. Nuclear Magnetic Resonance Imaging in Retroperitoneal Fibrosis. *AJR Am J Roentgenol* 1983; 141: 35-38

**Author Information**

**Carlos Sala-Mateus, M.D.**

Unitat de Recerca, Corporació de Salut del Maresme i la Selva