

Chondroid Syringoma of the Nose: Histopathological diagnosis of a rare case

R Bindra

Citation

R Bindra. *Chondroid Syringoma of the Nose: Histopathological diagnosis of a rare case*. The Internet Journal of Dermatology. 2009 Volume 8 Number 1.

Abstract

Chondroid syringomas are rare, usually benign tumors occurring predominantly in the head and neck area. They are also known as mixed tumors of skin.

INTRODUCTION

Chondroid syringomas or mixed tumors of skin is a rare subcutaneous tumor that may be confused with various skin lesions.⁽¹⁾ The incidence of chondroid syringoma is low, and has been reported at 0.01-0.098%.⁽²⁾ Lesions are typically located on the head and neck and are non-ulcerating, slow growing, subcutaneous or dermal nodules.

CASE REPORT

A 30 YEARS OLD MALE presented with a painless skin coloured nodule measuring 1x1cms. present on the dorsa of nose since one and half year. The tumor was completely excised under local anaesthesia. No recurrence of the tumor has been observed 12 months after surgery.

HISTOPATHOLOGICAL EXAMINATION

Showed cords, nests and tubuloglandular structures composed of well differentiated tumor cells embedded in a hyalinized stroma with abundant chondroid matrix and the diagnosis of chondroid syringoma was established. No features suggested a malignancy was observed.

Figure 1

Fig 1: Low power showing tubular glands embedded in chondroid matrix

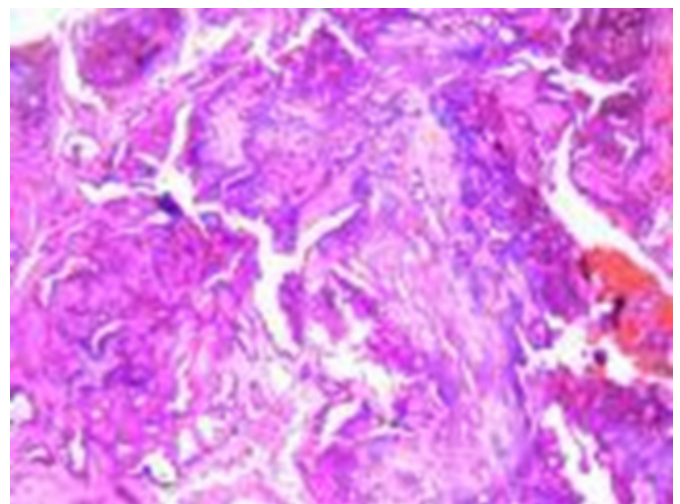
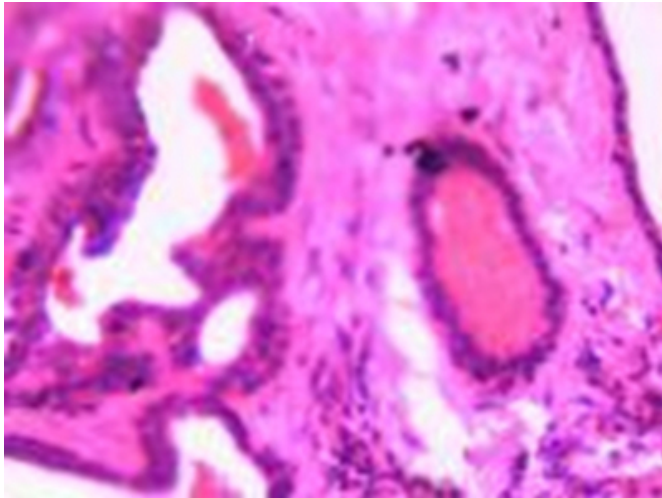


Figure 2

Fig 2: High power view showing Tubular glands in hyalinized stroma.



DISCUSSION

Chondroid Syringoma, also known as mixed tumors of the skin, are composed of both epithelial and mesenchymal components. Chondroid syringomas affect middle-aged men more than women.⁽³⁾ Chondroid syringomas share similarities with pleomorphic adenomas, which are mixed tumors that arise from the salivary glands.⁽⁴⁾ Headington divided chondroid syringomas into variants based on histological differences in luminal morphology, but there remains debate as to their exact origin.⁽⁵⁾

Hirsch and Helwig gave them the appellation chondroid

syringoma because of the presence of sweat gland elements set in a cartilaginous stroma. They proposed the following five histological criteria for diagnosis: (a) nests of cuboidal or polygonal cells, (b) intercommunicating tubuloalveolar cords or more rows of cuboidal cells with ductal structures composed of one or two rows of cuboidal cells, (c) occasional keratinous cysts varying in composition. Chondroid syringomas may have all five characteristics or manifest only some.⁽⁶⁾

Mills suggests that mixed tumors are monoclonal neoplasms with replicating cells that have the ability to differentiate toward epithelium or mesenchyme, and histologic variability of mixed tumors of the skin.⁽⁷⁾ Optimal treatment of benign chondroid syringomas is surgical excision. Examination of excised tissue is most reliable in establishing a definite diagnosis.⁽⁸⁾

References

1. Dermatol Surg 2003;29:179-81
2. Yavuzer R, Basterzi Y, Sari A, Bir F, Sezer C. Chondroid Syringoma: a diagnosis more frequent than expected. Dermatol Surg 2003;29:179-81.
3. Stout AP, Gorman JG. Mixed tumors of the salivary gland type. Cancer 1959;12:537-43.
4. Satter EK, Graham BS. Chondroid Syringoma. Cutis 2003;71:49-52.
5. Headington JT. Mixed tumors of skin: eccrine and apocrine types. Arch Dermatol 1961;84:989-96.
6. Chondroid Syringoma. Mixed tumor of skin; Salivary gland type. Arch Dermatol 1961;84:835-47.
7. Mills SE. Mixed tumors of the skin: a model of divergent differentiation. J Cutan Pathol 1984;11:382-6.
8. Agarwal V, Gupta RL, Kumar S, Mishra K, Agarwal S. Malignant Chondroid syringoma. J Dermatol 1998;25:547-9.

Author Information

Rubi Bindra

Senior Resident, Pathology Department, I.G.M.C. Shimla. Bindra cottage, Panthaghati, Kasumpti, Shimla