

Clinical Trial Of Praziquantel And Prednisone In Rural Patients With Neurocysticercosis Presenting With Recurrent Epileptic Attacks

H Foyaca-Sibat, L Ibañez-Valdés

Citation

H Foyaca-Sibat, L Ibañez-Valdés. *Clinical Trial Of Praziquantel And Prednisone In Rural Patients With Neurocysticercosis Presenting With Recurrent Epileptic Attacks*. The Internet Journal of Neurology. 2001 Volume 1 Number 2.

Abstract

Most of epileptic patients with Neurocysticercosis (NCC) respond very well to phenytoin or carbamazepine for control of their seizures. We select a group of patients with NCC and uncontrolled seizures and found that patients under one day antiparasitic/steroids therapy revealed a faster response to anticonvulsant drug therefore based on our findings, to associate antiepileptic treatment and antihelminthic medication in the management of patient with NCC and recurrent seizures could be advisable. We also found that most of those patients also were HIV seropositive with a past history of pulmonary tuberculosis and some of them had been reinfected by *Taenia Solium* from time to time therefore to be treated with anti-parasitic drugs and steroids regularly until an efficient health education program will be implemented is also recommended. Some of our patient default treatment in order to "continue having seizures" and keep their disability grand pension creating and bioethical dilemma between well control of fits, reduce frequency of brain damage or lost of an alternative way for alleviation of poverty. The best management of patients with NCC is the prophylaxis of recurrent infection based on adequate primary health care system.

INTRODUCTION

Neurocysticercosis (NCC) is an infection of central nervous system (CNS) caused by the larval stage (*Cysticercus cellulosae*) of the pig tapeworm *Taenia Solium*. This is the most common helminth to produce CNS infection in human being. The occurrence of acquired epilepsy or the syndrome of raised intracranial pressure in a person living in or visiting a region where taeniasis is endemic or even in one living in close contact with people who have taeniasis should suggest a diagnosis of cysticercosis; the NCC may remain asymptomatic for months to years and commonly a diagnosis is made incidentally when neuroimaging is performed, many symptomatic forms can predominate. Symptoms and signs are related both to the parasite which can show a different biological behavior from one place to another and to the inflammatory-immunological response of the host. Most of epileptic patients taking phenytoin for a proper control of their seizures, respond very well.

Diagnostic criteria for NCC have been well-established recently, Based on these studies, categories of Absolute criteria (patognomonic) is acceptable when the histological demonstration of the parasite from biopsy of the brain or spinal cord lesion is made, or cystic lesion showing the

scolex on CT or MRI, or when sub retinal parasites can be visualized by fundoscopy examination; however in places where CT scan is not available, plain X rays of muscular tissues in the limbs showing "cigar shape" calcifications or plain skull X rays with intracranial calcifications (between 1 to 10 mm of diameter) can be useful to confirm the diagnosis; other options such as Major, Minor or Epidemiological criteria's can be reviewed in the Del Bruto's article 1. According to the International League Against Epilepsy, cysticercosis is the single most common cause of acquired epilepsy in the developing world, where prevalence rates of active epilepsy are twice those of developed countries 2.

PATIENTS AND METHOD

One hundred eighty-nine patients fulfilling the clinic criteria of uncontrolled epilepsy probably due to NCC were identified prospectively for the study among patients referred to neurology clinic in Umtata General Hospital from rural clinics during two years period. Most of those patients presented with an associated HIV seropositive, pulmonary tuberculosis (PTB) and history of hematuria due to schistosomiasis.

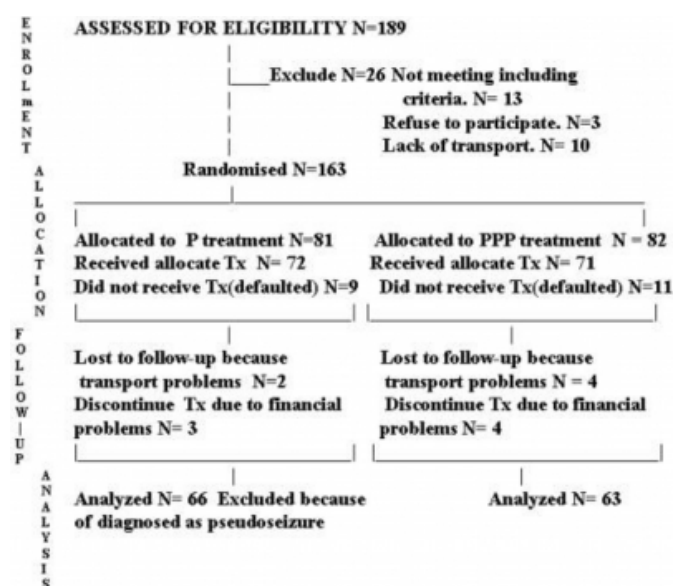
After the CT scan of the brain, eligible patients (n=163) had active and/or chronic forms of NCC without clinical signs of raised intracranial pressure and uncontrolled tonic-clonic generalized motor seizures in spite of regular antiepileptic treatment (phenytoin 300 mg per os at night). An experienced neurologist evaluated all patients, none patients had no previous history of any other neurological disease apart from epilepsy and those with concomitant disorders such: metabolic disorders, cerebrovascular diseases, meningoencephalitis, and head injuries were excluded. No patients receiving treatment for any other disease requiring immunomodulatory agents within the past six months were admitted to the study. Other exclusion criteria included alternative cause for intracranial calcifications or suspicion of tuberculomas, pyogenic brain abscesses, mycotic granulomas, and primary or metastatic brain tumors (See the flow chart). Apart from antiepileptic drugs, steroids medications and antiparasite treatment, other concomitant treatment was prohibited for patient while participating in the study. CT Scan of the brain for all of them was done.

STUDY DESIGN

The study was designed as a double blind, randomized trial over a redesigned 1-years period. The patients were assigned to receive 400 mg of phenytoin at night daily plus 40 mg of prednisone orally during five days and 100 mg/Kg/day of praziquantel divided in four 25 mg/kg doses, each dose of praziquantel was given at 1 or 2 hourly intervals for one day only or a single dose of 400 mg of phenytoin at night during the same period of time by block-randomization procedure.

Figure 1

Flow diagram of the progress through the phases of randomized trial



OUTCOME MEASURES

Response to antiepileptic medication and an associated anti-parasite treatment were assessed with the Neurology UGH scale in which 0 is the lowest: no change, I: equivalent to decreased frequency of seizures II: diminished frequency and duration of seizures III: the highest free of seizures Each patient received the same supporting treatment and was encouraged to eat a rich carbohydrate meals and were evaluated throughout the study by the same personnel.

STATISTICS

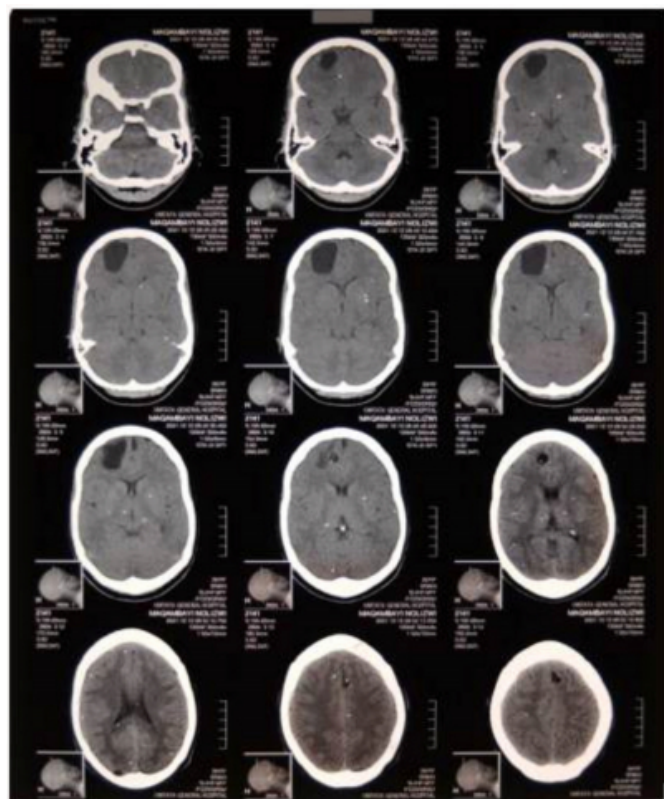
Two-side t. test were used to analyses the primary outcome measure between baseline and the end of the treatment.

RESULTS

Absolute criteria for NCC based on neuroimaging findings were present in all selected patients considering the cystic lesion with scolex as patognomonic.

Figure 2

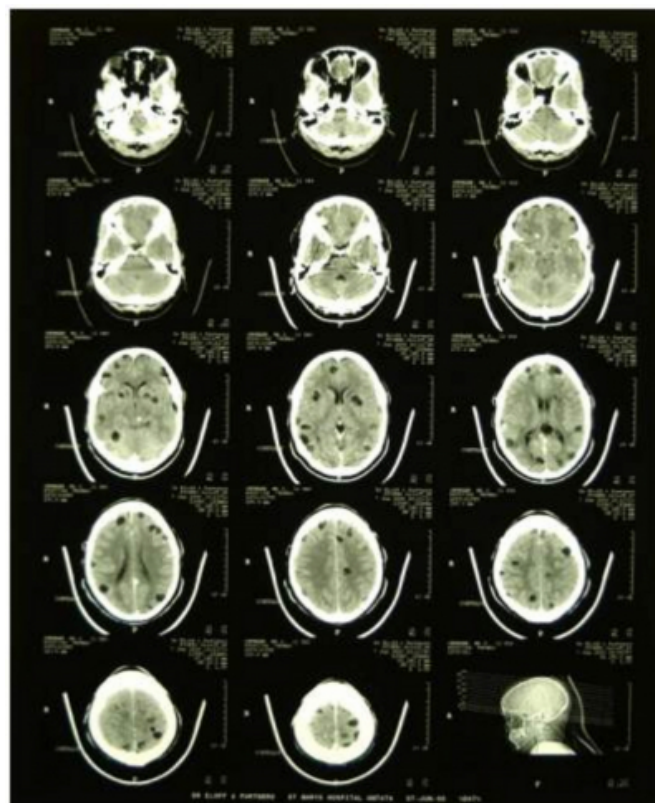
Figure 1: Cystic lesions showing the scolex on CT brain scan.



The scolex is visualized as a bright nodule within the cyst, producing the so-called “hole-with-dot” imaging in some vesicular cysts located in the brain parenchyma, intraparenchymal viable cysticercus and an associated calcified lesions (1 to 10 mm of diameter) were the most common forms of presentation Figure 2, cysts bigger than 20 mm were also seen, other locations such as subarachnoid and intraventricular were no seen in this study. Almost all patients (89.9 %) were HIV seropositive (CD4 count > 300 cells), 72.4 % had past history of PTB, and 38 % past history of hematuria due to schistosomiasis.

Figure 3

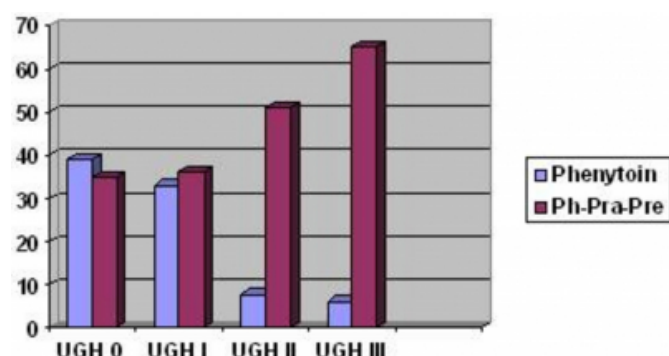
Figure 2



Efficacy analysis included 71 patients (36 women and 35 men, mean age 38,27, years, range 13 to 59) treated with Phenytoin/praziquantel/prednisone (PPP) and 72 (32 women and 40 men, mean age 49.28 years, range 13 to 62) with phenytoin (P) only. A mild improvement on both groups at the beginning was observed but at baseline no difference in UGH scale was found between group treated with PPP and group treated with P (PPP 0.06 ± 1.02 versus P 0.02 ± 0.09 , $p=0.56$). One month after the treatment with praziquantel, improvement was seen when comparing UGH scale results between two different groups (mean SE, 0.74 ± 0.14 versus -0.2 ± 0.2 , 0.63 ± 0.25 , mean difference \pm SE; $p=0.005$). In the PPP group 73 % improved in frequency and duration of epileptic attacks. Using parameter of Meta analysis we found that odds ratio of 0.74 in P group, and 0.43 in PPP with 82 % of confidence interval (See table I)

Figure 4

Table I: Respond to Phenytoin and Phenytoin-praziquantel-prednisone. No changes, I- Decreased frequency of seizure, II- Decreased Frequency and duration, III-free of seizure



DISCUSSION

The total UGH scores at baseline in both groups were similar securing adequacy of randomization and the mild improvement observed was in relation with increased dosage of phenytoin. Our report provides documentation that PPP are effective in patients with NCC and recurrent seizures. Using a UGH score as the primary outcome variable, we found statistically significant difference between PPP and P therefore we have hypothesized about the advantages to combine the antiepileptic drug and antiparasite medication for patients with recurrent seizures and NCC; Clinical manifestation of NCC are related with the inflammatory-immunological response of the patient when the parasite is degenerating or dying as result of cysticidal therapy (without associated steroids medication) influenced by the number of viable cysts, size and stage of the lesions, site of the cyst in the intracranial region, and the amount of re-infections along the time. However many patients remain asymptomatic and the risk of intracranial infection after *T. solium* egg or proglotides ingestion depend of the combination of immunological status of the patient, the biological characteristic of the parasite, geographical and atmospheric conditions. Its also serve to explain clinical differences and different results with the same treatment from one place to another. In places like former Transkei where combination of NCC, CNS Schistosomiasis, PTB and retroviral infections can be present, regular cycles of praziquantel and prednisone (also kills *Schistosoma mansoni*) should be done until this picture will be changed by a good primary health care system.

Studies about treatment for NCC in human beings has shown an increased level of IgG, interleukin-2, and neopterin in the CSF of those patients after being treated with praziquantel.

Elevated eosinophil and interleukin-5 in serum and elevated interleukin-5 and interleukin-6 concentrations in the CSF has been reported also.

NCC in our region has some particularities and differs from others in different regions. In China subcutaneous cysticercosis is common, in India subarachnoid cysticercosis and multiple lesions are much less common than our region and Latin America, in Guatemala there is neurocysticercosis but seizures disorders are also less common; ocular neurocysticercosis is rare in most regions. We are experienced an increasing number of patients because access to: employment, cash income, safe and clean water, proper toilet facilities, proper refuse disposal, electricity, telecommunication and medical services are extremely low in our region and there is some tendency to increase, this combined factors are perpetuating its dissemination within a vicious circle; the incidence and prevalence of tuberculosis and HIV/AIDS are also gradually increasing. The probable link with HIV infection and PTB is that chronic parasitic infection downregulates the cellular immune response that is needed to prevent infection by HIV and *Mycobacterium tuberculosis*. We also believe that blood cells from patient with NCC are more susceptible to infection by HIV therefore if we consider that in South Africa HIV/AIDS accounted for 40% of death in adults aged 15-49 in 2000 and will probably kill between 5 and 7 million people by 2010, then the prophylaxis of NCC is being an important priority among other public health problems. Some epileptic patients under treatment are discontinuing the treatment or taking their medication irregularly for continues getting seizures and to keep their disability pension, it is another problem that should be changed.

Maslinska reported the accumulation and phenotype heterogeneity of mast cell (MC) contained immunoreactive tryptase in human brains with NCC. MC are the multifunctional effectors cells of the immune system, MC synthesize and secrete numerous powerful mediators such as endorphins, serotonin, histamine, heparin, kinins, leukotriens, prostaglandins, vasoactive intestinal peptide, proteolytic enzymes, cytokines and phospholipases which are well known to have significant pathophysiological effects on vascular and neuronal tissues. The role of MC accumulated in the CNS regarding host immune tolerance is clear but regulating factors for MC accumulation are not certain. Because MC provide a source of multifunctional cytokines and other potent mediators has been proposed that

MC participate in control of cerebral blood flow and the integrity of the blood-brain-barrier. Perilesional edema in calcified lesion is probably related with histamine concentration from MC, inducing vasopermeability.

The severity of the infection in patients with more than fifty viable cysticercus, associated calcified lesions with perilesional edema, and increased number of re-infections suggest additional course of praziquantel or regular cycles; our proposal is one day treatment every month for six month, regular assessment and reconsider further courses. In immunodepressed patients by HIV infections or any other similar condition the parasite can produce more damage on the nervous tissue because their can remains viable for a longer period of time compare with non-immunodepressed patient. We have hypothesized that in those patients there is one particular stage of the parasite (we call it: “critical stage”) between its vesicular stage and colloid stage, where the releasing of taeniaestatin (serine proteinase inhibitor) is increased or is less destroyed, and the prostaglandins and cytokines production from the glial cells are importantly affected therefore a global cortical neuronal dysfunction is present affecting the mitochondrial activity and its ATP production, disturbance of neuronal membrane metabolism leading to recurrent paroxysmal activity .

Prevention of NCC could be part of the solution to the pandemics HIV/AIDS and PTB but it needs to incorporate poverty alleviation, proper access to clean and safe water supply, effective sanitation, reform of animal husbandry technique, vaccination to pigs against *Taenia Solium*, appropriate health education, and massive deworming programmes controlled by an efficient Primary Health Care System.

CONCLUSIONS

One day of treatment with praziquantel at doses of

100mg/kg/day divided in dosage of 25 mg/kg 3 hourly and 40 mg of prednisone for 4 days can be the treatment of choice for patients with recurrent seizures and mixed forms of NCC. However a recommendation that it be used as “first choice” for those patients with Major or Minor criteria for NCC must be examined in comparison with other available therapeutic approaches.

References

1. Del Bruto OH, Rajshekhar V, White AC, Tsang VCW, et al Proposed diagnosis criteria for neurocysticercosis. *Neurology* 2001; 57:177-1
2. Commission Tropical Diseases of the International League Against Epilepsy. Relationship between epilepsy and tropical diseases. *Epilepsy* 1994; 35:98-93
3. Nilsson L, Tomson T, Farahmand BY, Diwan V, Persson PG. Cause-specific mortality in epilepsy: a cohort study of more than 9,000 patients once hospitalized for epilepsy. *Epilepsia* 1997; 38:1062-1068
4. Johnston SC, Siedenberg R, Min J, Jerome EH, Laxer KD. Central apnea and acute cardiac ischemia in a sheep model of epileptic sudden death. *Ann Neurol* 1997; 42:588-594
5. Foyaca-Sibat H, Ibanez-Valdes LdeF, Awotedu A, Fernandez-Mena C Neurocysticercosis in the former Transkei. 7Th Internet World Congress for Biomedical Sciences, INABIS2002, April 14-20, 2002. http://www.inabis2002.org/poster_congress/area_01/01011/0117.pdf
6. Rolfs A, Muhlschlegel F, Jansen-Rossek R, et al. Clinical and immunologic follow-up study of patients with neurocysticercosis after treatment with praziquantel. *Neurology* 1995;45:532-538.
7. Evans CWE, Garcia HH, Hartnell A, et al. Elevated concentrations of eotaxin and interleukin-5 in human neurocysticercosis. *Infect Immun* 1998;66:4522-4525.
8. McMichael AJ, Rowland-Jones SL. Cellular immune response to HIV. *Nature* 2001; 410:980-986.
9. Dorrington R, Bourne D, Bradshaw D, Laubscher R, Timaeus IM. The impact of HIV/AIDS on adult mortality in South Africa: Burden of Disease Research Unit, Medical Research Council, 2001, ISBN 1-919809-14-7. (website: <http://www.mrc.ac.za/bod>).
10. Masilinska D, Dambska M, Kalieska A, Maslinsmi S. Accumulation, distribution and phenotype heterogeneity of mast cell (MC) in human brains with neurocysticercosis. *Folia Neuropathol.* 2001; 39(1):7-13

Author Information

H Foyaca-Sibat, MD

Department of Neurology, Faculty of Health Sciences, University of Transkei

Lde F Ibañez-Valdés, MD

Faculty of Health Sciences, University of Transkei