

Adrenal Carcinoma With Tumor Extending To Right Atrium: A Case Report With Review

S Rege, K Das, K Ashish, A Chitaranshi, O Rohondia

Citation

S Rege, K Das, K Ashish, A Chitaranshi, O Rohondia. *Adrenal Carcinoma With Tumor Extending To Right Atrium: A Case Report With Review*. The Internet Journal of Surgery. 2006 Volume 9 Number 1.

Abstract

Malignancy of the adrenal cortex is a rare but aggressive and grows rapidly and metastases to liver, lungs, kidneys, bones. Very rarely tumor thrombus may extend through the inferior vena cava to the right atrium. This may be picked up by Computerised tomography (CT scan) of the abdomen and further supported by a transesophageal echocardiography. We represent a case report of a patient who presented insidiously with abdominal lump and was subsequently diagnosed as adrenal tumor with tumor extension to right atrium. A combined abdominal and cardiac surgery was undertaken. The presence of intravascular extension should not be considered as a contraindication to surgery, in contrast it provides the only hope of long term survival.

INTRODUCTION

Adrenal malignancy is rare with presentation of lump in abdomen or rarely hyper functioning tumor. Tumor extension in the right atrium is rare. We present a case of right adrenal malignancy with extension into the right atrium treated by combined abdominal and cardiac approach.

CASE REPORT

A 40 year old man, farmer by occupation attended our hospital with progressive abdominal distension, heaviness in the right hypochondrium, bilateral pedal edema, and shortness of breath on exertion. He complained of weight loss. Patient was a chronic smoker, nonalcoholic, had a history of pulmonary tuberculosis 10 years ago treated with antitubercular chemotherapy. There was no history of giddiness or blackouts. On examination, patient was conscious and oriented with pallor and had no icterus, cyanosis or lymphadenopathy. Jugular venous pulse and heart sounds were normal. There was bilateral pedal edema. Laboratory parameters pointed to anemia, hypoalbuminemia, and normal renal and liver function tests. Abdominal ultrasound revealed a large lesion on the right adrenal gland consistent with a tumor along with hepatomegaly and mild ascites. Computerised tomography (CT scan) of abdomen pointed to a diagnosis of adrenal carcinoma with extension of tumor thrombus into right atrium (Figure 1&2).

Figure 1

Figure 1: CT scan of the abdomen of the patient showing large right adrenal mass extending into the retrohepatic region with thrombus in the inferior vena cava.

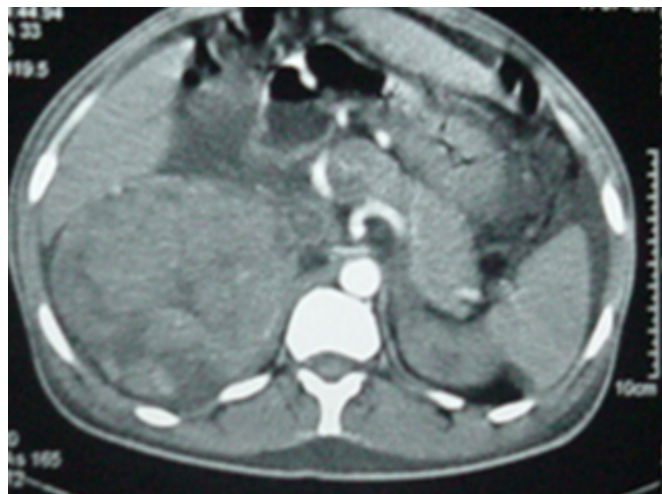
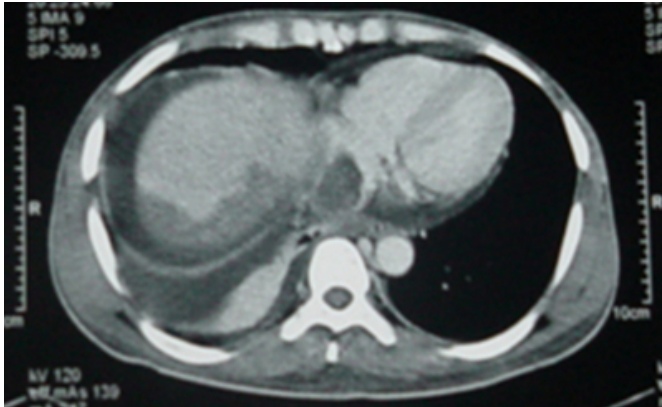


Figure 2

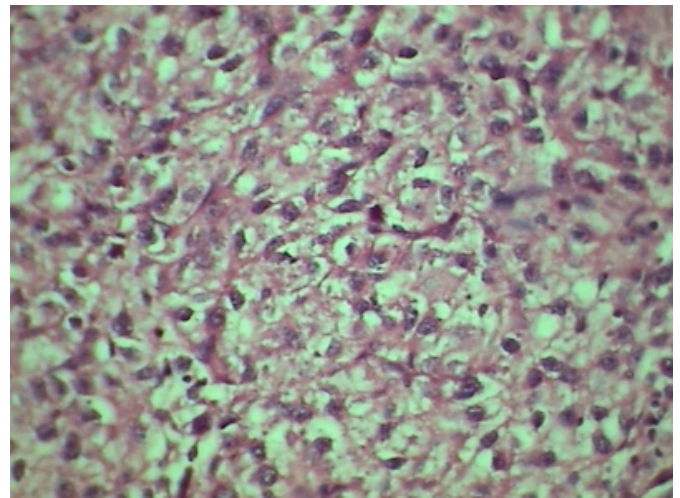
Figure 2: CT scan of lower thorax showing tumor thrombus into the right atrium.



Echocardiography revealed a normal size and function of the left side structures and a large uniform, echodense, immobile mass attached to the interatrial septum was seen in the right atrium. The inferior vena cava (IVC) was mildly enlarged and an elongated mass attached to its wall was seen. The patient was operated with the aid of cardiopulmonary bypass and hypothermia - a combined cardiac and abdominal procedures were performed, monitored by transesophageal echocardiography. She underwent right adrenalectomy and nephrectomy. Inferior vena cava and right atrium were exposed and a large mass extending from the hepatic portion of the inferior vena cava to the right atrium was delineated and was removed. Patient had torrential bleeding from the IVC just after the closure of the abdomen and could not be resuscitated from the hypovolemic shock and disseminated intravascular coagulation. Patient died few hours later. Histologic examination revealed an adrenal carcinoma and a large thrombus containing malignant cells. (Figure 3)

Figure 3

Figure 3: Photomicrograph of the adrenal mass showing hyperchromatic nuclei with mitosis > 5 per field and vascular invasion.



DISCUSSION

Cancer of the adrenal cortex (adrenocortical carcinoma) is a rare but aggressive malignancy, accounting for 0.05% to 0.2% of all cancers, and 0.2% of all deaths caused by cancer.⁽¹⁾ The neoplasm arises in women twice as often as men, usually in the third to fifth decade of life. Another peak incidence is noted in children <6 years of age, and girls are affected twice as common as boys.⁽²⁾ The right adrenal is affected with the same frequency as the left adrenal. Approximately 50% of adrenal cortical carcinomas are functioning and produce hormonal and metabolic syndromes leading to their discovery. The other 50% are silent and discovered only when they attain large size and produce localized abdominal symptom or metastasis ⁽³⁾. Adrenocortical carcinoma grows rapidly and tends to metastasize to the liver and lungs and to invade the kidney, renal veins and the inferior vena cava.⁽⁴⁾ Dissemination of the tumor occurs in 82% of the patients with a median survival of 14.5 months.⁽⁵⁾ About 70% of patients have advanced disease at the time of presentation, usually stage III or IV disease (with local invasion +/- metastasis) ⁽⁶⁾.

The adrenal glands are highly vascular-the venous drainage being more constant than arterial supply. The right adrenal vein courses directly into the vena cava which explains the potentiality of a right adrenocortical carcinoma to the inferior vena cava, usually accompanied by a thrombus.⁽⁷⁾ Right atrial involvement is very rare ⁽⁷⁾. Other forms of cardiac involvement include infiltration of the inter-atrial septum and a malignant pericardial effusion ^(8, 9).

Pathogenesis of adrenal carcinoma may be related to loss of heterozygosity at loci on the short arm of chromosome 11₍₁₀₎. The clinical and histological criteria of malignancy is not well established, however venous invasion, more than 20 mitoses per 50 high power fields, aneuploidy, abnormal production of androgens, and 11-deoxysteroids predict a poorer outcome ₍₁₁₎. Immunostaining with vimentin, may distinguish adrenal neoplasms from other carcinomas, especially renal cell carcinoma (negative stain with vimentin), which may also have similar presentation ₍₁₂₎. The main clinical manifestation of vena caval and right atrial extension of the tumor include peripheral edema, ascites and hepatomegaly. Sudden death, presumably due to right ventricular inflow obstruction was also reported. ₍₁₃₎ Due to tendency of the tumor to disseminate, a precise pre-operative assessment is essential. Evaluation should involve CT, Venography and MRI ₍₇₎. The management includes en block radical resection of tumor with ipsilateral nephrectomy with excision of intravascular extension under the aid of cardiopulmonary bypass and hypothermia. Following complete excision, adjuvant therapy with Mitotane should be considered to prevent recurrences, which is also drug of choice for inoperable recurrent metastatic disease ₍₁₄₎.

Tumors that affect the right atrium include primary neoplasms and secondary tumors such as Hypernephroma, Hepatoma, Adrenocortical carcinoma, Testicular sarcoma, and Melanoma ₍₁₅₎. Early diagnosis and radical surgery appears to be the best method of palliation and only hope for long-term survival. Nonetheless, aggressive therapeutic considerations in the management of adrenocortical carcinoma should take a balance between the benefits of radical surgical intervention and increased potential complications. Importantly, intravascular tumor extension should not be a contraindication to surgical exploration in a case of adrenocortical carcinoma!

ACKNOWLEDGEMENT

We thank our Dean, Dr N. A. Kshirsagar for allowing us to publish the hospital data.

CORRESPONDENCE TO

Dr Sameer A Rege C-201, Gagangiri Park Co-operative Hsg.

Society, Samata Nagar, Thane (W) 400606. India

Telephone: 91-22-25385353 Mobile: 09869178040 Email: samrege@yahoo.com

References

1. Brennan MF. Adrenocortical Carcinoma. *CA Cancer J Clin.* 1987; 37: 348-65.
2. Norton JA, Levin B, Jensen RT. Cancer of the endocrine system: the adrenal gland. In: DeVita VT Jr., Hellman S, Rosenberg SA (eds), *Cancer: Principles and Practice of Oncology*. Philadelphia, PA: JB Lippincott; 1993:1352-71.
3. Page DL, DeLellis RA, Hough AJ. Tumors of the adrenal (monograph) In: *Atlas of Tumor Pathology*, Washington D.C.: AFIP; 1986
4. Francis IR, Smid A, Gross MD, Shapiro B, Naylor B, Glazer GM. Adrenal masses in oncologic patients: Functional and morphologic evaluation. *Radiology* 1988; 166 :353-6.
5. Lutin JP, Cerdas S, Billiaud L, Thomas G, Gilhaume B, Bertagna X, Laudat MH, Louvel A, Chapuis Y and Blondeau P. Clinical features of adrenocortical carcinoma, prognostic factors, and the effect of mitotane therapy. *N Engl J Med* 1990; 322: 1195-1201.
6. Schteingart D.E. Adrenal Cancer; *Endocrinology Vol 6.*: Pg.1767-71.
7. Schrameck P, Durser E, Bhargabha A, Hruby W and Umek H. Adrenal Cortical Carcinoma: Preoperative demonstration of right atrial extension by sonography and computed tomography. *J Uro* 1985; 133:260-2.
8. Bilge A, Pierre LA and Kulbertus HE. Isolated cardiac metastasis of adrenal carcinoma: Transesophageal echocardiographic features. *Am Heart J* 1996; 132: 1066-8.
9. Nakata A, Yagi S, Oyaka K, Kida H, Sugioka G. Adrenocortical carcinoma with a giant pericardial mass. *Intern Med* 1993; 32:438-40.
10. Yano T, Linehan M, Anglard P, et al. Genetic changes in human adrenocortical carcinomas. *J Natl Cancer Inst* 1989; 81: 518-23.
11. Henry I, Grandjovans S, Couillin P, et al. Tumor specific loss of 11p15.5 alleles in del 11p13 Wilms tumor and in familial adrenocortical carcinoma. *Proc Natl Acad Sci USA* 1989; 86: 3247-51.
12. Wick MR, Cherwitz DL, McGlennen RC, Dehner LP. Adrenocortical carcinoma, an immunohistochemical comparison with renal cell carcinoma. *Am J Pathol* 1986; 122: 343.
13. Dickens P, Roon CS, and Wat MS. Sudden death associated with solitary intracavitary right atrial metastatic tumor deposit. *Forensic Sci Int* 1992; 57: 169-73.
14. Haak HR, Herman J, Van de Velde CJH, et al. Optimal treatment of adrenocortical carcinoma with mitotane: results in a consecutive series of 96 patients. *Br J Cancer* 1994; 69: 947-51.
15. Weyman A. Right ventricular inflow tract. In *Principles and Patterns of echocardiography* (edited by: Weyman AE) Lea and Febiger, a Waverly Co. Second edition 1994; 824-62.

Author Information

Sameer A. Rege, MS, DNB

Department Of Surgery, Seth G S Medical College & KEM Hospital

Krishanu S. Das, MBBS

Department Of Surgery, Seth G S Medical College & KEM Hospital

Katewa Ashish, MS

Department Of Surgery, Seth G S Medical College & KEM Hospital

Anurag Chitaranshi, MBBS

Department Of Surgery, Seth G S Medical College & KEM Hospital

Omprakash S. Rohondia, MS, DNB

Department Of Surgery, Seth G S Medical College & KEM Hospital