

An Unusual Form Of Post-Tubercular Kyphosis: Case Report And Review Of Literature

J Jerome

Citation

J Jerome. *An Unusual Form Of Post-Tubercular Kyphosis: Case Report And Review Of Literature*. The Internet Journal of Neurosurgery. 2005 Volume 3 Number 1.

Abstract

Tubercular spondylitis of long-standing cases shows paradiscal body destruction. One or more vertebral bodies are involved and they are usually collapsed and wedged, besides the diminution of disc space. We present a case of tuberculosis of 15-year follow up treated conservatively with an unusual presentation of 100-degree kyphosis.

INTRODUCTION

Tubercular spondylitis of the vertebral bodies usually heals on treatment by osseous replacement of the disc space, regeneration of vertebral bodies and formation of block vertebra. Multiple vertebral involvements during active growth period are responsible for progression of kyphotic deformity. Increase of kyphosis is observed in dorso-lumbar lesions. Most of these patients show neurological complication after 5 to 10 years of follow up due to the severity of the deformity.

We report a case of 15-year follow up of tuberculosis of dorsal spine with a progressive kyphosis of 100 degree with no neurological deficit.

CASE REPORT

A 24-year-old lady came to our department with severe deformity in the upper back. She was a follow up case of tuberculosis of dorsal spine treated by 'middle path' regimen at the age of nine years. She had a kyphotic deformity of 40 degree at the time of presentation. She was given a Taylor's brace and advised to wear. She had been in our regular follow up every year. Her measurement of kyphosis at the time of each visit showed an average increase of 5-10 degrees. However she did not showed any neurological complication in spite of her progressive deformity.

Photographs at the time of last visit (Fig 1) showed a severe kyphosis in the upper dorsal spine with restriction of all movements in neck. Radiographs showed (Fig 2) an end-on view of the proximal vertebral canal and severe kyphosis (Fig 3). Magnetic resonance imaging showed cord edema

from D2-11 with changes of myelomalacia and syrinx formation (Fig 4). She had a kyphosis of 100 degree. She had no neurological deficit at present. She was not operated considering various risk factors, severe degree of kyphosis with intact neurological system and dreadful complications after surgery. She was also warned about the possibility of progressive neurological deficit in future. Patient is now under regular follow up every month.

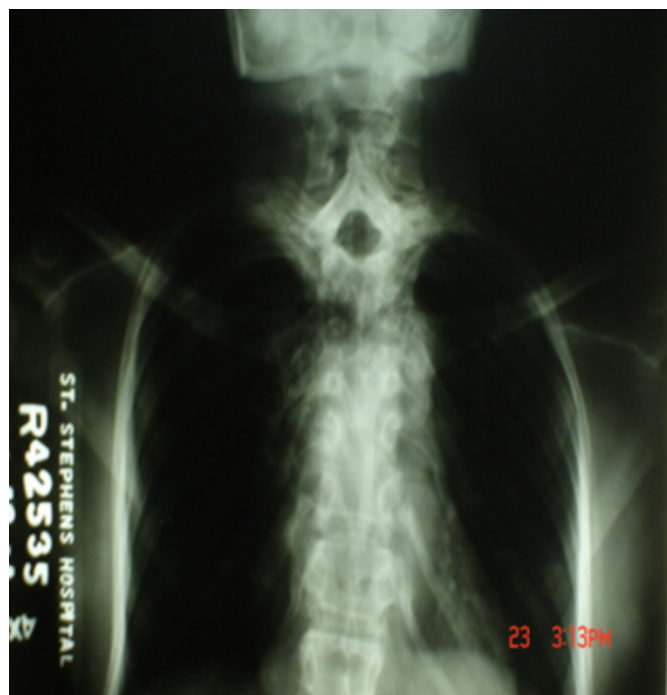Figure 1

Figure 1: Shows the severe kyphotic deformity in the upper dorsal spine.



Figure 2

Figure 2: Shows the end-on view of the proximal vertebral canal



DISCUSSION

The use of modern anti-tubercular drugs has, however changed the outcome of the treatment drastically. When tubercular spondylitis diagnosed early and treated adequately, healing takes place, leaving behind no radiological deformity or defect except a moderately diminished space^{21,22,23}.

Multiple vertebral bodies involvement, active growth and situation of the lesion in the dorsal spine are responsible for excessive increase in kyphosis²². Increase of kyphosis was observed in 67 percent of dorso-lumbar lesions, 55 percent of dorsal spine lesions and 33 percent of lumbar lesions²².

The conservative treatment in conjunction with triple or dual drug therapy does not prevent the progress of kyphosis^{4,5,10,16,22}. However, even solid posterior spinal fusion has shown progress in kyphosis during the follow up of patients. Similar observations regarding increase in kyphosis have been reported by other workers in their series treated by direct surgical extirpation of the vertebral lesions^{13,14}.

Tubercular spondylitis with involvement of dorsal spine showed progressive kyphosis and are subjected to the greatest degree of angulation^{5,18,22}. Destruction of a dorsal vertebral body results in a posterior displacement of the

center of motion, subluxation at the level of the articular facets and increase in the weight to be borne by the anterior part of the body¹⁸. Patients with kyphosis more than 30 degree in dorsal spine have 3 or more vertebral body involved.

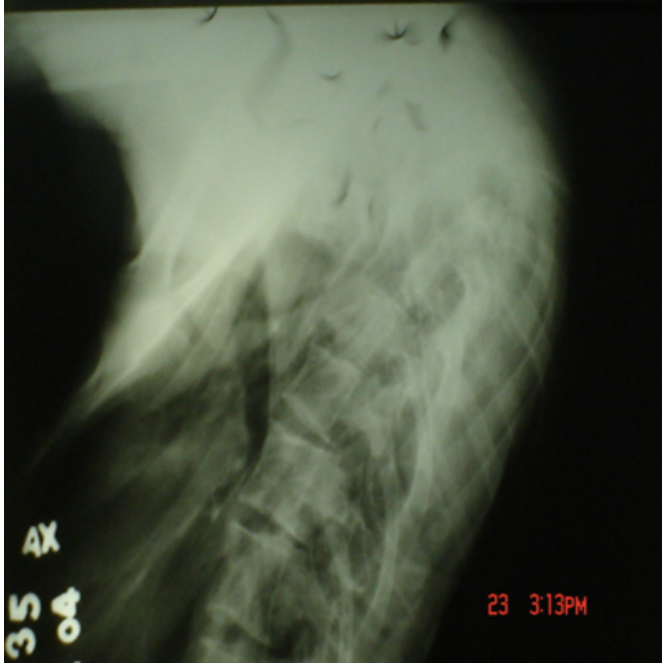Kyphosis more than 45 degree put posterior spinal muscles to a mechanical disadvantage and further adding to the deformity. The whole deformity takes place during the phase of active spinal growth with or without active disease. Development of severe kyphotic deformity after the clinical healing of the disease and completion of growth of the vertebral column seems to be uncertain. The only non-operative way to minimize the progressive increase in kyphosis seems to be recumbency in early active stage and prolonged protection with suitable brace in the late stages^{18,22}.

Upadhyay et al²⁴ stated that there is no rate of disproportionate unrestricted growth of posterior elements in the typical tubercular spondylitis responsible for severe kyphotic deformity. Unfortunately, however, majority of their pediatric patients had the disease between D11 to L5 and they excluded the cases that had 3 or more vertebral involvement. Chen et al³ obtained an average correction of kyphotic deformity by 10 degrees in adult patients treated by anterior debridement combined with anterior and posterior fusion.

There is no difference in regard to the behavior of kyphosis on whether patient is treated by universal excisional surgery or by non-operative medicinal therapy or by following 'middle path' regimen^{21,22,23}. Rajesekaran and Shanmugasundaram¹⁹ calculated the progression of kyphotic deformity in tuberculosis of the spine using the formula $Y = a + bx$, where x is the initial loss of vertebral body/ies and constants $a = 5.5$, $b = 30.5$.

Figure 3

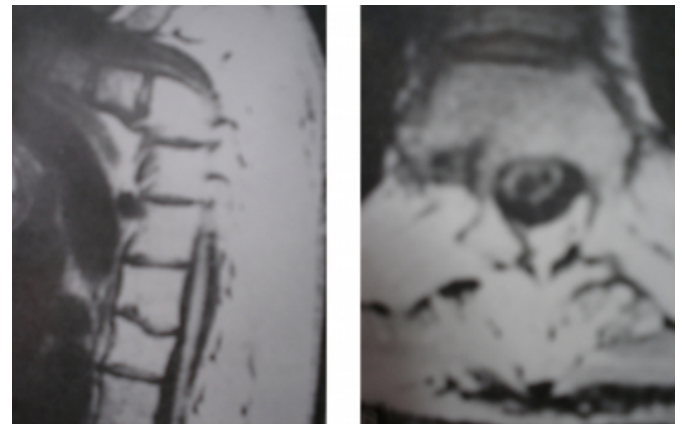
Figure 3: Lateral radiographs showed a severe kyphotic (100 degree) in Dorsal spine (D4-9). Since the disease and deformity occurred during the growing period, and the absence of normal stress on the vertebral column, the part of spine distal to the deformity has vertebra



The only operative procedure that has been claimed to prevent increase of kyphotic deformity is the radical excision and bone grafting performed in Hong Kong by the pioneers of the radical operation by themselves^{13,14}. At present scenario, young children having thoracic lesions with involvement of 3 or more vertebra, recumbency in prone position in early active stage, and operative debridement (anteriorly), if the disease is not healing by drugs, and bone grafting (posteriorly) for panvertebral stabilization may minimize the development of progressive kyphotic deformity^{22,23}.

Figure 4

Figure 4(a,b): MRI of the dorsal spine shows severe kyphotic deformity with presence of syrinx and early changes of myelomalacia.



The safest method of preventing severe kyphotic deformity is to identify the potential cases at high risk (active disease in patients younger than 10 years, dorsal lesion, involvement of 3 or more vertebra²² and subject them to a panvertebral operation including fusion of the posterior elements of the disease vertebra^{22,23}. It is unwise to rely solely on the anterior graft to prevent further collapse and increased kyphosis in patients in whom the length of the graft or the extent of the disease exceeds 2 disc spaces. Additional measures such as an extended period of recumbency (about 6 months) prolonged use of brace (for 6 to 12 months), and concomitant or delayed (additional) posterior arthrodesis may improve the results²².

Yau²⁶ pointed out that the kyphotic deformities may be unstable and progressive, particularly in childhood, and they believed that a severe deformity in the presence of active disease should be an absolute indication for decompression, correction and stabilization, as late reconstruction of a tuberculous kyphos was a difficult and dangerous procedure. Any significant correction of fixed kyphotic deformities involves many staged operations; the operative procedures required are anteriorly at the site of disease, osteotomy of the posterior elements at the deformity and halo-pelvic or halo-femoral traction post-operatively.

The resultant correction rarely improves cosmetics, some loss of correction during follow up is common, and the operation is fought with dangerous complications including permanent paralysis. Of the patient treated by debridement surgery or radical operation (Hodgson's technique in Hong Kong) not much difference in the outcome of deformity was, however, observed in cases followed for more than 6

months²⁴.

Anterior transposition of the cord with rotation and retraction of theca through antero-lateral approach, with laminectomy, anterior fusion and sacrifice of intercostals nerves was done for treatment of paraplegia in severe kyphosis^{6,9}. Surgical correction of severe kyphotic deformity includes osteotomy on the concave side of the curve and wedge to open, rove wedge on the convex side and close the wedge. Hodgson⁷ performed this procedure by anterior transpleural approach. Louis¹¹ advocated correction of spinal deformity (gibbus) in tuberculosis of vertebral column by surgical correction of deformity for dorsal and lumbar, fusion for cervical spine, osteotomy for severe cases with slow traction and corrective plaster casts before the operation.

Halofixation²⁵ combined with pelvic traction¹⁵ or tibial traction²⁰ or with sacral bars has been safely employed in the treatment of severe deformities. Louw¹² used vascularised rib graft after decompression for neural deficit, preoperative kyphosis of 56 degrees was corrected to 27 degrees after surgery. Tuli²³ recommended not to operate in cases of fixed deformities proximal to L2 vertebra. They advice to prevent the development of severe deformity if it is anticipated, and subsequently do panvertebral fusion. Deformities, which are not fixed, can be corrected by halo-pelvic or halo-femoral traction before surgery. The maximum limit of traction used was 13 kgms through skull and 6 1/2 kgms for femur, provided traction increased gradually and watched closely for the neurovascular status of the patients. All correction occurs within 3 to 4 weeks of traction and surgery is done with intra-operative neurophysiological monitoring of the spinal cord²².

Various surgical techniques require experience, thorough knowledge of the operative techniques in spinal and thoracic surgery. These techniques are associated with death, extensive blood loss, loss of correction, paralysis, bowel and bladder disturbances, and embarrassment of various long tracts of spinal cord^{21,22,23}.

CONCLUSIONS

1. When tubercular spondylitis diagnosed early and treated adequately, healing takes place, leaving behind no radiological deformity or defect except a moderately diminished space
2. There is no difference in regard to the behavior of kyphosis on whether patient is treated by universal

excisional surgery or by non-operative medicinal therapy or by following 'middle path' regimen.

3. The safest method of preventing severe kyphotic deformity is to identify the potential cases at high risk (active disease in patients younger than 10 years, dorsal lesion, and involvement of 3 or more vertebra) and subject them to a pan-vertebral operation.
4. Many experienced authors concluded not to operate in cases of severe and fixed deformities proximal to L2 vertebra, as they are always associated with risk of developing permanent paralysis.
5. Anterior transposition of the cord with rotation and retraction of theca through antero-lateral approach, with laminectomy, anterior fusion and sacrifice of intercostals nerves can be done for treatment of paraplegia in severe kyphosis.

CORRESPONDENCE TO

Dr. J.Terrence Jose Jerome, M.B.B,S Post graduate in orthopedics, Department of Orthopedics, St Stephen's Hospital, Tiz Hazari, Delhi.54, India. Phone 911-09868086916 Email: terrencejose@gmail.com Fax number: Fax 911-23932412

References

1. Baklim, G. Tuberculosis spondylitis: A clinical study with special reference to the significance of spinal fusion and chemotherapy. Acta Orthop Scand. (Suppl), 47,1960.
2. Cauchoix, J., Binet, J.P. Anterior surgical approaches to the spine. Ann.R.Coll.Surg.Engl.,21,237-43,1957.
3. Chen, W.J., Chen, C.H., Shich, C.H., Surgical treatment of tuberculous spondylitis. 50 patients followed for 2-8 years. Acta Orthop. Scand., 66,137-42,1965
4. Dickson, J.A.S. Spinal Tuberculosis in Nigerian children: A review of ambulant treatment. J Bone Joint Surg., 49B, 682-94,1967.
5. Friedman, B. Chemotherapy of tuberculosis of the spine. J Bone Joint Surg., 48A, 451-74,1966.
6. Griffiths, D.L., Seddon, H.L, Roaf, R. Pott's paraplegia. Oxford University press London, 1956.
7. Hodgson, A.R., Yau, A.C.M.C. Anterior surgical approaches to the spinal column, in Recent Advances in Orthopedics. Ed. Apley, A.G 289-323.J and A. Churchill, London, 1969.
8. Hodgson, A.R., Wong, W., Yau, A.C.M.C. X-ray appearance of tuberculosis of the spine. Charles C.Thomas. Illinois, 1969.
9. Hyndman, O.R. Transplantation of the spinal cord. Surg. Gynecol. Obstet., 84,460-64,1947.
10. Konstam, P.G., Blesovsky, A. The Ambulant treatment of the spinal tuberculosis. Br.J.Surg.,50,26-38,1962.
11. Louis, R., Conty, C.R., Pouye, I. Operation of pott's

- disease with correction of gibbosity. *J.Chir.*99, 401-16,1970.
12. Louw, J.A. Spinal tuberculosis with neurologic deficit. *J Bone Joint Surg.*, 72B, 686-93,1990.
13. Medical Research Council. 5-years assessments of controlled trails of ambulatory treatment, debridement and anterior spinal fusion in the management of the tuberculosis of spine. Studies in Bulawayo (Rhodesia) and in Hong Kong: VI report. *J Bone Joint Surg.*, 60B, 163-77,1978.
14. Medical Research Council. 10-years assessment of a controlled trial comparing debridement and anterior spinal fusion in the management of the tuberculosis of spine in patients on standard chemotherapy in Hong Kong: VIII report. *J Bone Joint Surg.*, 64B, 393-98,1982.
15. O'Brien, J.P., Yau, A.C.M.C., smith, T.R., Hodgson, A.R. Halo Pelvic traction. *J Bone Joint Surg.*, 53B, 217-29,1971.
16. Paus, B. Treatment for tuberculosis of the spine. *Acta Orthop.Scand.* (Suppl), 72,1964.
17. Prabhakar, R. A controlled trial of short-course regimens of chemotherapy in patients receiving ambulatory treatment or undergoing radical surgery for tuberculosis of the spine. *Ind. J. Tud. Supp.*, 36,1989.
18. Puig Guri, J. The formation and significance of vertebral ankylosis in tuberculous spine. *J Bone Joint Surg.*, 29, 136-48,1947.
19. Rajasekaran, S., Shanmugasundaram, T.K. prediction of the angle of gibbus deformity in tuberculosis of the spine. *J Bone Joint Surg.*, 69A, 503-08,1987.
20. Schmidt, A.C. Halo-tibial traction combined with Milwaukee brace. *Clin. Orthop.*, 77,73-83,1971
21. Tuli, S.M. Results of treatment of spinal tuberculosis by 'middle path regime'. *J Bone Joint Surg.*, 57B, 13-23,1975.
22. Tuli, S.M. severe kyphotic deformity in tuberculosis of the spine. *Current concepts. Int. Orthop.* 19,327-31,1995.
23. Tuli, S.M., Srivastava,T.P., Verma, B.P., sinha, G.P. Tuberculosis of the spine. *Acta Orthop. Scand.*, 38,445-58,1967.
24. Upaday, S.S., Saji, M.J., Sell, P., Sell, B., Hsu L.C.S. spinal deformity after childhood surgery for tuberculosis of the spine. (A comparison of radical surgery and debridement). *J Bone Joint Surg.*, 76B, 91-98,1994.
25. Welply, W.R., Pieron, A.P. Halo traction. *Acta Orthop. Beig.*, 38,147-56,1972.
26. Yau. A.C.M.C., Hsu, L.C.C., O'Brien, J.P., Hodgson, A.R. Tuberculous kyphosis: correction with spinal osteotomy, halopelvic distraction, and anterior and posterior fusion. *J Bone Joint Surg.*, 56A, 1419-34,1974.

Author Information

J. Terrence Jose Jerome

Stephen's Hospital