

Co-existing Abdominal Tuberculosis and Colon Carcinoma: Case Report with Review of Literature

M Husain, P Sachan, S Khan, N Chauhan, S Kishore

Citation

M Husain, P Sachan, S Khan, N Chauhan, S Kishore. *Co-existing Abdominal Tuberculosis and Colon Carcinoma: Case Report with Review of Literature*. The Internet Journal of Surgery. 2006 Volume 13 Number 2.

Abstract

Coexisting abdominal tuberculosis and colon carcinoma is a rare entity. We had a patient who was diagnosed as a case of caecal carcinoma infiltrating the right abdominal wall. He was planned for laparotomy and right hemicolectomy was done. Histopathology showed features of both malignancy and tuberculosis. We reviewed the literature and found that very few cases have been reported and most of them have some common features. These cases belong to the younger age group with right-sided colonic involvement and predominantly a mucinous type of adenocarcinoma.

INTRODUCTION

Carcinoma and tuberculosis of the bowel are very common conditions but the sites of predilection differ with carcinoma being more common in the distal large bowel and tuberculosis in the terminal ileum or ileocaecal junction. Both occurring at the same site is a very rare entity [1,6,7]. Although few cases have been reported in the literature, no cause-effect relation could be defined. The aim of reporting the case and reviewing the literature is to answer the following questions: 1) Does malignancy appear early in the presence of tuberculosis? 2) Is any specific type of malignancy associated with tuberculosis? 3) Is there any site predilection of malignancy if coexistent with tuberculosis? 4) Does carcinoma facilitate the entry of tubercle bacilli? 5) Does tuberculosis predispose to malignancy?

CASE REPORT

A 35-year-old male patient, referred to us from medicine OPD, had been on anti-tubercular treatment for the last three months for intestinal tuberculosis. As he was not showing signs of improvement, he was advised Barium meal follow-through which showed features suggestive of malignancy. When he presented to us, he had a history of recurrent subacute intestinal obstruction with significant loss of weight and appetite. On examination, a hard lump was detected in the right iliac fossa measuring around 5x5cm in size, fixed, non-tender and with irregular surface. Investigations revealed: Hb 11.5gm%; LC 7800; DLC: N 52%, L 46%, E 2%; ESR 45. Chest X-ray was within normal limits, FNAC yielded adenocarcinoma of the caecum, CECT

showed a growth measuring 7x7cm in size at the ileocaecal junction invading the lateral abdominal wall with multiple enlarged mesenteric and para-aortic lymph nodes.

The patient was planned for laparotomy and right hemicolectomy was done. All operative findings were consistent with the CECT findings.

Histopathological Examination: Mucin producing carcinoma of the ileocaecal region with free surgical margins without any evidence of malignancy in lymph nodes, however most of the lymph nodes showed epithelioid granulomas and multinucleate giant cells suggestive of tuberculosis.

The patient received 6 cycles of chemotherapy in the form of 5-Fluorouracil, Leucovorin and Oxaliplatin. At present, he is doing well and is on antitubercular treatment which started simultaneously with the chemotherapy.

Figure 1

Figure 1: Tumor cells with mucin lakes

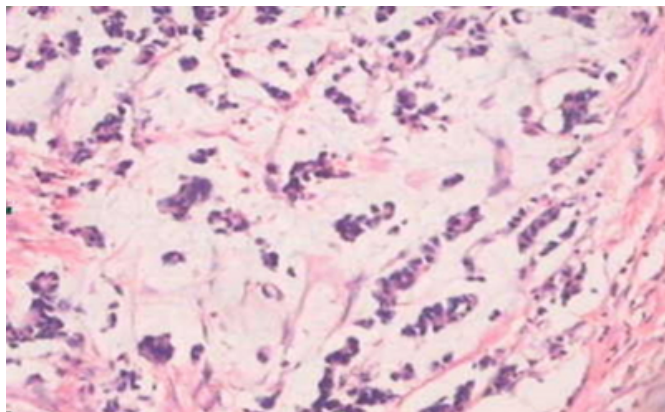
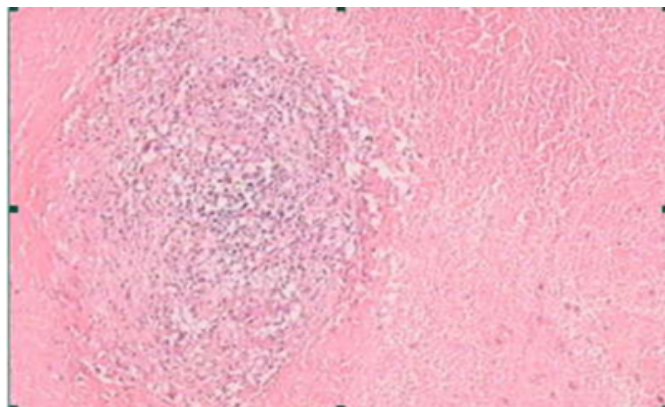


Figure 2

Figure 2: Caseation necrosis in lymphnodes



DISCUSSION

Abdominal tuberculosis is more common among young adults and there is slight female preponderance. Terminal ileum and ileocaecal junction are the two most common sites affected by tuberculosis. The site of predilection is dictated by abundance of lymphoid tissue, rate of absorption of intestinal content, prolonged stasis and reduced digestive activity. Basically, there are three types of intestinal tuberculosis: ulcerative, hyperplastic and sclerotic.

Tuberculosis may spread to the abdomen by various routes: 1) Ingestion of contaminated food - primary intestinal tuberculosis. 2) Swallowed infected sputum - secondary tuberculosis. Peritoneum and mesenteric lymph nodes may become infected during the bacteremic phase of primary pulmonary tuberculosis. When the intestine becomes infected by retrograde lymphatic spread from the mesenteric lymph nodes, the nodal disease is considered to be primary and intestinal involvement is regarded as secondary. This is supported by the fact that the early intestinal lesion is usually found in the submucosa with the overlying mucosa

being normal. In addition, more advanced lesions with caseation are found often in the mesenteric nodes rather than in the bowel [2].

Colorectal carcinoma is the most common malignancy of the gastrointestinal tract. It has a negligible overall predominance of female patients; mean age at presentation is around 70-75 years [3]; 40-45% of colorectal cancers are located in the rectum (10-15%) or sigmoid colon (40%) and 25-35% in the caecum or ascending colon whereas the remainder is equally distributed through the rest of the colon. The predominant histological variant is adenocarcinoma (90-95%), followed by mucinous adenocarcinoma (10%) and others like signet ring cell and small cell carcinoma.

Co-existence of abdominal tuberculosis and colon carcinoma is a rare entity. It is not clear whether they are a predisposing factor for each other or it is just a coincidence, but there are certain points, which are common in most of the cases.

Most of the cases of coexisting tuberculosis and colon carcinoma reported in the literature showed that the patients belong to the younger age group. Sushama et al. reported a case of a 23-year-old female while the patient of Maheswari et al. was a 30-year-old male. Our patient was also a 35-year male.

Almost all studies showed that the majority of patients with colon malignancy coexistent with tuberculosis had right-sided colonic involvement. Tanak et al. analyzed 26 cases with 17 involving the right side of the colon. Three out of 4 cases of colon carcinoma coexistent with tuberculosis had right-sided disease as shown by Jain et al. The patients described by Maheshvari et al. and Sushama et al. as well as our patient also had right sided colonic malignancy.

As far as histopathology is concerned, most of the coexistent malignancies are of mucinous type as reported by Tanak et al., Jain et al., and Sushama et al. Our patient also had a mucinous variety of adenocarcinoma. Microscopically, at least 50% of the tumour must be mucinous to be labeled as a mucinous carcinoma [7]. It has the worst prognosis because the pockets of mucin can mechanically dissect along the planes of the bowel wall, thus facilitating the spread of malignancy.

Though chronic diseases like ulcerative colitis and Crohn's disease are known to predispose to malignancy, there is no evidence to indicate a higher incidence of colon carcinoma in tuberculosis. One view is that carcinoma may facilitate the entry of tubercle bacilli with development of secondary

infection [8]. This view might be correct in only those cases in which tuberculosis is occurring at an unusual site like left-sided colon or at an unusual age like in older patients. But most of the cases reported in the literature belong to the younger age group with involvement of the right-sided colon. This indicates that it may be the tuberculosis, which is a predisposing factor for malignancy, either by lowering immunity or because of chronic ulceration.

But still no definitive cause-effect relation could be ascertained and a lot of study and awareness is needed to detect an association between these two diseases.

References

1. Jain BK, Chandra SS, Narsimhan R, Ananthkrishnan N, Mehta RB. Coexisting tuberculosis and carcinoma of the colon. *Aust N Z J Surg* 1991; 61(11): 828-31.
2. Rangabashyam N. Abdominal tuberculosis. In: Peter J Morris, Ronald A Malt, editors. *Oxford Text Book of surgery*. Vol II. USA: Oxford University Publications 1994; 2484-2491.
3. Andreas M Kaiser, Joseph W, Robert W. Tumours of the Colon. In: Michael J Zinner, Stanley W Ashley, editors. *Maingots Abdominal Operations*. 11th Ed. USA: The McGraw-Hill Companies 2007; 625-659.
4. Sushama Desai, Sunil Jagtap, Hemant Janugade: Coexisting Tuberculosis and Mucinous carcinoma of Caecum - A case report. *MJAFI* 2005; 61: 197-199.
5. Maheshwari V, Alam K, Indu, Tyagi SP. Ileocaecal tuberculosis associated with adenocarcinoma of the caecum and colon. *J Indian Med Assoc* 1995; 93(10): 392-3.
6. Tanaka K, Kondo S, Hattori F, et al. A case of colonic carcinoma associated with intestinal tuberculosis and an analysis of 26 cases reported in Japan, *Gan No Rinsho* 1987; 33: 1117-23.
7. Juan Rosai. Gastrointestinal tract, large bowel. In: Juan Rosai, editor. *Ackerman's Surgical Pathology* 8th Ed. Vol I. USA: Harcourt Brace and Company Asia Pte. Ltd; 729-799.
8. Sane SY, Nimbkar SA. Carcinoma colon with tuberculosis. *J Postgrad Med* 1980; 26930: 199-200.

Author Information

Musharraf Husain, MS, DNB, MRCSEd

Asst. Prof., Department of Surgery, Himalayan Institute of Medical Sciences

P.K. Sachan, MS Gen. Surgery

Professor, Department of Surgery, Himalayan Institute of Medical Sciences

Sabina Khan, MD Pathology

Asst. Professor, Department of Pathology, Himalayan Institute of Medical Sciences

Neena Chauhan, MD Pathology

Assoc. Professor, Department of Pathology, Himalayan Institute of Medical Sciences

Sanjeev Kishore, MD Pathology

Professor, Department of Pathology, Himalayan Institute of Medical Sciences