

Gastrointestinal Trichobezoar: A Case Report and Review of the Literature

S Chaganti, M Immadisetty, R Botchu, K Chari

Citation

S Chaganti, M Immadisetty, R Botchu, K Chari. *Gastrointestinal Trichobezoar: A Case Report and Review of the Literature*. The Internet Journal of Surgery. 2007 Volume 15 Number 2.

Abstract

We report a case of gastrointestinal trichobezoar in an 18-year-old girl who presented to the surgical out-patient clinic with a painless palpable lump in her epigastrium. The patient was fit and healthy otherwise without any gastrointestinal symptoms and her past medical history was non-contributing. Our case is the second reported case of trichobezoar in the literature in a healthy young woman without any history of psychiatric disorder or gastric surgery. She was investigated with a barium swallow and CT scan followed by endoscopy which confirmed the diagnosis of a gastrointestinal trichobezoar extending up to the distal ileum. She underwent gastrotomy and the trichobezoar was removed. The patient was referred to the psychiatry team for further assessment. There was no recurrence after a period of follow-up for 2 years. The mode of presentation and the appearance on ultrasound and CT scan are discussed.

INTRODUCTION

Bezoars are conglomerates of foreign material or indigestible organic substances in the alimentary tract of humans and certain animals like ruminants. There are various types of bezoars of which trichobezoar is one. Though most of the gastric bezoars occur as a complication of gastric or ulcer surgery, gastric bezoars may also be seen in the normal stomach as a result of ingestion of various objects which do not pass through the pylorus such as hair, paper and cotton.

CASE REPORT

An 18-year-old girl presented to the surgical clinic complaining of a lump in her abdomen, without any psychiatric background or medical problem.

The palpable lump in her epigastrium was 8 x 10cm in size, non-tender, mobile, non-pulsatile, not reducible, and non-compressible. Ultrasound of her abdomen revealed a mass and the echogenicity was difficult to interpret. She was hence subjected to a Barium swallow which showed a filling defect in the stomach (Figure 1). In view of this finding, she had a CT scan of the abdomen which demonstrated a free floating mass within the stomach. Endoscopy of the gastrointestinal tract was performed which confirmed the mass to be a trichobezoar with extension beyond the pylorus.

Hence she was subjected to surgery. Through a midline

incision a gastrotomy was performed. The mass was identified and the tail was seen to have gone through the duodenum and jejunum to the terminal ileum. The tail was tracked and the trichobezoar was removed in a retrograde fashion (milking from distal to proximal) (Figure 2). The patient had an uneventful recovery. Psychiatric consultation was sought before the patient was discharged.

Figure 1

Figure 1

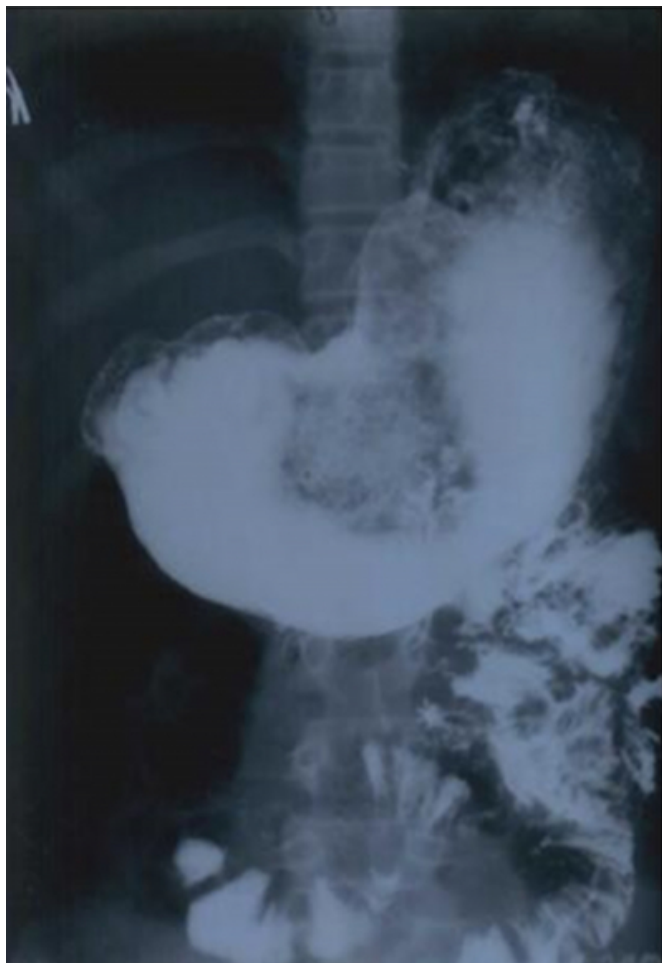
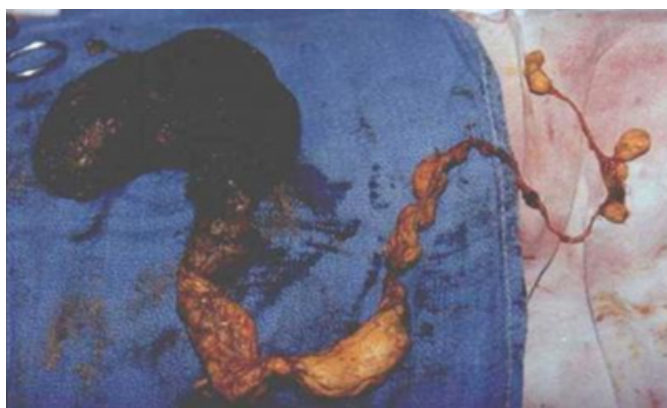

Figure 2

Figure 2



DISCUSSION

Bezoars are foreign bodies in the gastrointestinal tract that increase in size by accretion of non-absorbable food or fibre because of large particulate size, indigestibility, gastric outlet obstruction or intestinal stasis. The term “bezoar” is

derived from Arabic “badzehr” or from Persian “panzehr”, both meaning counter poison and antidote. ¹ The first description of a post-mortem human bezoar was given by Swain in 1854. ²

Trichobezoars are bezoars consisting of hair, are less common than phytobezoars, are seen most commonly in young people with normal gastrointestinal function and usually result from underlying behavioural disorders and mental retardation. In the classic review by DeBakey and Ochsner ³, 80% of trichobezoars were found in patients younger than 30 years of age.

The common complaints include abdominal pain, nausea and bloating, early satiety and weight loss. ⁴ In our case, there were no gastrointestinal symptoms apart from a non-tender epigastric swelling. Our case is similar to the case described by Coulter et al. ⁵ with respect to the age of presentation, absence of psychiatric or psychological problems and no history of previous surgery, except that there were no gastrointestinal symptoms apart from the non-tender epigastric swelling.

Both ultrasonography and CT are reliable methods of diagnosing gastrointestinal bezoars. Ultrasound is the primary imaging modality for evaluation of an upper abdominal mass in children and demonstrates a superficially located broad band of high-amplitude echoes along the anterior wall of the mass with sharp, clean posterior acoustic shadowing. ^{6,7} Plain abdominal CT usually shows a mobile intragastric mass consisting of compressed concentric rings with mixed density pattern. The demonstration of normal gastric wall and the free mobility of the mass on rescanning, after alteration of the patient's position and administration of oral contrast medium, rule out the origin from the gastric wall. ⁷ The definitive diagnosis of bezoars is established by endoscopy which helps to assess the extension of the tail of bezoars (Rapunzel syndrome). ⁷

Small bezoars may be amenable to nasogastric lavage or suction, clear liquid diet and the use of prokinetic agents. ⁸ Most trichobezoars, however, require surgery for removal. The standard treatment is a gastrotomy and extraction of the bezoar ⁵, as was the case in our patient except that the tail extended to the distal ileum which required removal in a retrograde fashion by milking.

CONCLUSION

Bezoars require a high index of suspicion for diagnosis and should be considered in the differential diagnosis of

asymptomatic epigastric swellings in young patients.

Trichobezoars are most commonly seen in patients with normal gastrointestinal tract function but with behavioural disturbances like trichophagia, trichotillomania and mental retardation. It is very difficult to explain the cause of trichobezoars in such patients without a known psychiatric history but we believe behavioural disturbances are linked with this. So we strongly recommend psychiatric referral in such patients.

CORRESPONDENCE TO

Chaganti S, Royal Gwent Hospital, Newport, UK e-mail: drchaganti2002@yahoo.co.uk

References

1. Williams RS. The fascinating history of bezoars. *Med J Aust* 1986; 145: 613-614
2. Chisholm EM, Leong HT, Chung SC, Li AK. Phytobezoar: An uncommon cause of small bowel obstruction. *Ann R Coll Surg Engl* 1992; 74: 342-344
3. DeBakey M, Ochsner A. Bezoars and concretions: A comprehensive review of the literature with analysis of 303 collected cases and a presentation of 8 additional cases. *Surgery* 1939; 5: 132-160
4. Lee J. Bezoars and foreign bodies of stomach. *Gastrointest Endosc Clin N Am* 1996; 6: 605-619
5. Coulter, Rachel; Antony, Martin Thomas; Bhuta, Prajesh; Memon, Muhammed Ashraf. Large Gastric Trichobezoar in a Normal Healthy Woman: Case Report and Review of Pertinent Literature. *Southern Medical Journal* 2005; 98: 1042-1044
6. McCracken S, Jongeward R, Silver TM, Jafri SZH. Gastric Trichobezoar: Sonographic findings. *Radiology* 1986; 161: 123-124
7. Narinder K Kaushik, Yash P Sharma, Asha Negi, Amal Jaswal. Images: Gastric Trichobezoar. *Indian J Radiol Imaging* 1999; 9: 137-139
8. Phillips MR, Zaheer S, Drugas GT. Gastric Trichobezoar: Case report and literature review. *Mayo Clinic Proc* 1998; 73: 653-656

Author Information

S. Chaganti

Royal Gwent Hospital

M. Immadisetty

Guntur Medical College

R. Botchu

Royal Gwent Hospital

K.S.N. Chari

Guntur Medical College