

Case Of The Month: Case 2/2001

J Nates

Citation

J Nates. *Case Of The Month: Case 2/2001*. The Internet Journal of Surgery. 2000 Volume 1 Number 2.

Abstract

HISTORY

A 44 year-old white male was admitted to the Neuro-ICU of our institution 4 days after a MVA. His only injury was a fracture/dislocation of L4-L5 vertebrae, and no motor deficits were evident after the lesion had been surgically stabilized. The post-operative period was uneventful until the morning of his ICU admission when, he had vomited and aspirated gastric contents. On arrival to the unit he was pale and sweating profusely; he had clear signs of respiratory distress, distended abdomen, hypoactive bowel sounds and abdominal tenderness. Because of his presentation and physical examination, x-rays of chest and abdomen were requested (see below).

Figure 1

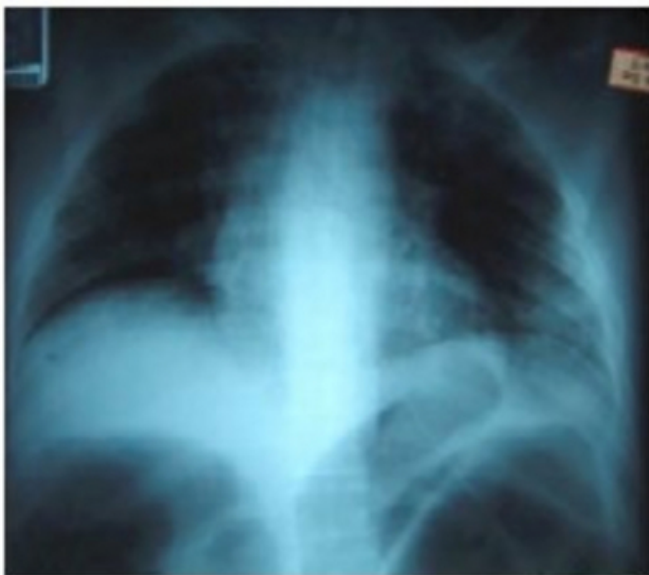
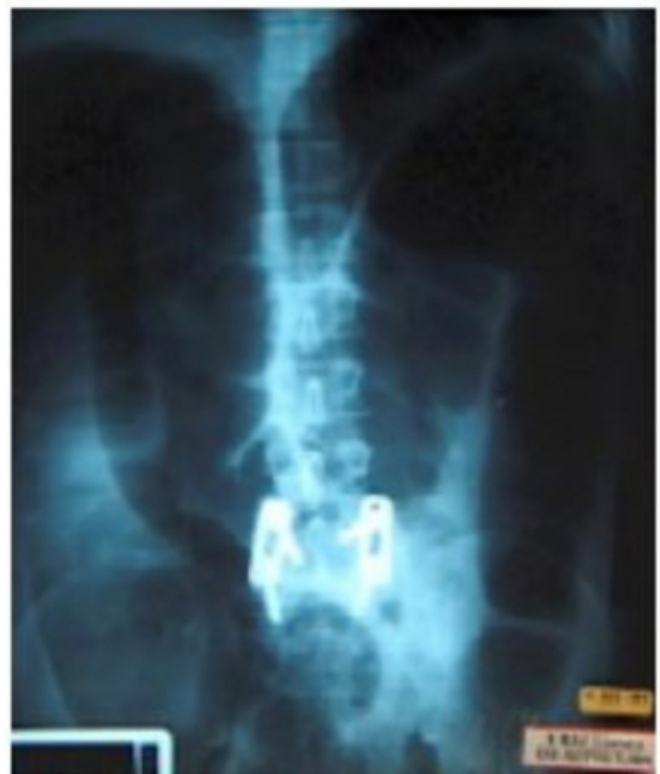
Figure 2

ABDOMEN 1 view



QUESTIONS

ANSWERS

1. What is your diagnosis?

Answer: This is an acute colonic pseudo-obstruction also known as Ogilvie's syndrome because; it was Sir Heneage Ogilvie that first described the syndrome in 1948 (1). Its etiology is unclear but it is thought that the acute colonic dilatation, without evidence of mechanical obstruction, is caused by an imbalance between parasympathetic and sympathetic innervations of the intestine. Some authors suggest that this is more of an excessive large bowel parasympathetic suppression rather than sympathetic overactivity (2). However, the syndrome has been associated

with many different conditions such as burns, sepsis, electrolyte abnormalities, myocardial infarction, orthopedic surgeries, pancreatitis, drugs and others (3,4,5). This specific patient silently developed the syndrome; because of the pseudo-obstruction his abdomen became distended and vomiting lead to the aspiration of gastric content and respiratory distress that brought him to ICU. The above patient was discharged in excellent condition after receiving conservative management a few days later.

2. What other tests would you request to confirm your diagnosis?

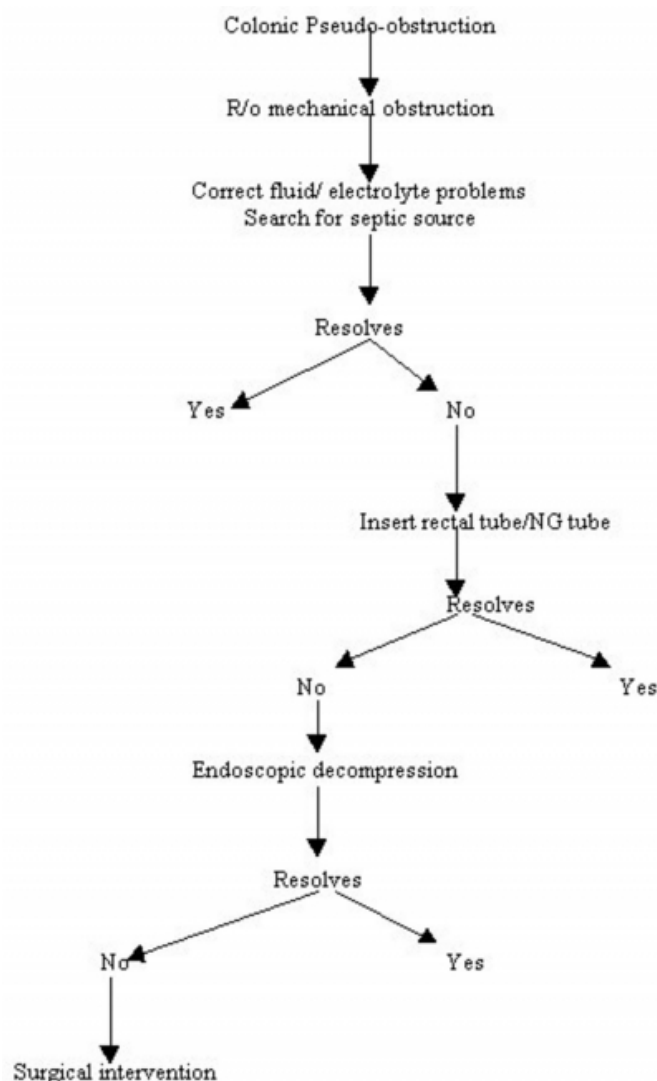
Answer: Although, the diagnosis of acute colonic pseudo-obstruction is one of exclusion, true mechanical obstruction should be ruled out. The investigation includes CT of abdomen with contrast, it is necessary to rule out fecal impaction, colonic or rectal tumor, volvulus, and even toxic megacolon (5).

3. What is the management of this condition?

Answer: A conservative approach is recommended after ruling out mechanical obstruction. Strict rest of the bowel starting parenteral nutrition, if necessary, should be followed by the insertion of a nasogastric tube for decompression while the patient is NPO. Intravenous fluids replacement, correction of electrolytic abnormalities, sometimes a low rectal tube, and if not effective endoscopic placement of a long tube as far as proximal colon, are all part of the usual management (5,6). The use of neostigmine and erythromycin has been advocated to stimulate bowel activity (7,8). Surgery is left for patients that do not respond to the above measures and develop signs of ischaemia, worsening abdominal signs with increase white cell count, fever, or cecal dilatation equal or greater than 12 cm (9). The following treatment algorithm was developed by J. Cross and R. Marvin (5):

Figure 3

TREATMENT OF COLONIC PSEUDO-OBSTRUCTION



If at any point the patient develops signs of perforation or impending perforation, proceeding to operative decompression or resection may be warranted.

References

1. Ogilvie, H. Large-intestine colic due to sympathetic deprivation: a new clinical syndrome. *Br Med J* 1948; 2:671-673.
2. Stephenson, BM, Morgan, AR, Salaman, JR, Wheeler, MH. Ogilvie's syndrome: a new approach to an old problem. *Dis Colon Rectum* 1995; 38: 424-427.
3. Vanek, V, Al-Salti, M. Acute pseudo-obstruction of the colon (Ogilvie's syndrome): an analysis of 400 cases. *Dis Colon Rectum* 1986; 29:203-210.
4. Kadesky, K, Purdue, GF, Hunt, JL. Acute pseudo-obstruction in critically ill patients with burns. *J Burn Care Rehabil* 1995; 16:132-135.
5. Cross J and Marvin R. Acute Colonic Pseudo-Obstruction in a patient with a Significant Closed Head Injury. *The Internet Journal of Emergency and Intensive Care Medicine* 2000; 4 (1): <http://www.ispub.com/journals/IJEICM/Vol4N1/ogilvie.htm>

- 1
6. Stephenson, KR, Rodriguez-Bigas, MA. Decompression of the large intestine in Ogilvie's syndrome by a colonoscopically placed long intestinal tube. *Surg Endosc* 1994; 8: 116-117.
7. Ponc, RJ, Saunders, MD, Kimmey, MB. Neostigmine for the treatment of acute colonic pseudo-obstruction. *NEJM* 1999; 341: 137-141.
8. Rovira, A, Lopez, A, Cambray, C, Gimeno, C. Acute colonic pseudo-obstruction (Ogilvie's syndrome) treated with erythromycin. *Int Care Med* 1997; 23: 798.
9. Ponsky, JL. Ogilvie's syndrome. In Cameron, JL, editor: *Current Surgical Therapy*, 1998, Mosby, Inc.; pp190-191.

Author Information

Joseph L. Nates, MD, Assistant Professor

Director Neurosciences ICU, Neurosurgery, University of Texas Medical School Houston