

Spontaneous Enterocutaneous Fistula In An Appendicectomy Scar

M Pancholi, M Wadhwani, P Lubana, D Jain

Citation

M Pancholi, M Wadhwani, P Lubana, D Jain. *Spontaneous Enterocutaneous Fistula In An Appendicectomy Scar*. The Internet Journal of Surgery. 2007 Volume 15 Number 2.

Abstract

We are reporting a rare case of enterocutaneous fistula which appeared 5 years after an appendicectomy. This patient, a 30-year-old male, presented with the history of swelling developing in the right inguinal region 5 months back, which soon ruptured to yield fecal matter continuously from the wound. The only significant past history was that of appendicectomy done 5 years back for acute appendicitis. Subsequent histology proved the etiology to be tubercular. Treatment was provided successfully in form of fistulectomy with right hemicolectomy with ileo-transverse anastomosis and the patient was given full 9 months of a four-drug antitubercular regimen. The patient has done well in the last two years' follow-up.

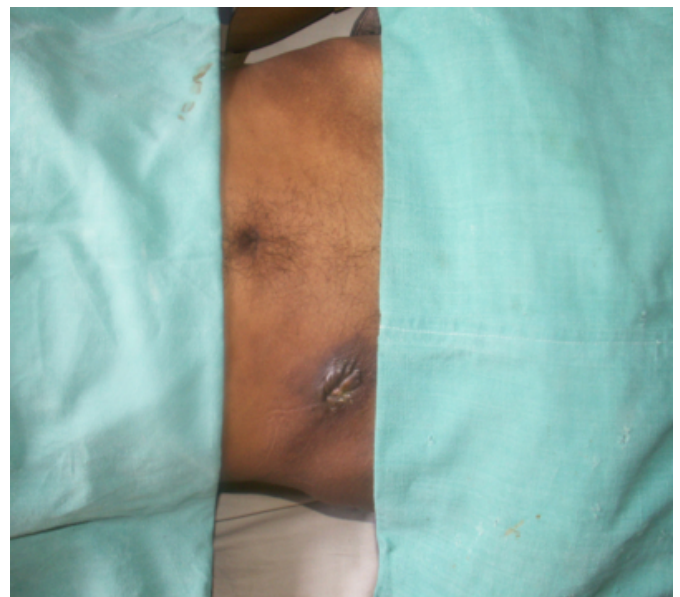CASE

This patient, a 30-year-old male, presented to surgery OPD at our institute with complaints of fecal matter coming from the right lower abdomen since 5 months. Initially, he developed a small swelling in the right iliac fossa which, after 5-6 days, ruptured to yield faecal material from the wound. The faecal matter kept coming continuously from that wound since then soiling the clothes and the patient had to change his clothes frequently for this reason. Fever of moderate degree accompanied the swelling initially for 4-5 days, but it subsided after that. This patient did not complain of usual symptoms of weight loss or evening rise of temperature. On inquiring about past treatment received, he revealed to have undergone appendicectomy 5 years back. He was a smoker since the last 15 years and consumed alcohol occasionally. Family history also was not suggestive of any significant medical or surgical disease.

On examination, the patient was moderately built and nourished. His vital parameters were stable. On local examination, the abdomen was found to be soft, non-tender, and all quadrants moved equally to respiration. An appendicectomy scar (gridiron incision) was seen in the right iliac fossa. A fistulous tract was seen over the scar with faecal soiling in the region (figure 1). Per rectum examination was normal.

Figure 1

Figure 1



On investigation, the patients had mild anaemia with normal blood cell counts. X-ray of the abdomen was normal and abdominal sonography also was normal except minimal fluid collection around bowel loops in the right iliac fossa. A barium meal follow-through series and a fistulogram were obtained for the patient, which revealed a long-segment terminal ileal stricture involving also the ileocaecal junction and a fistulous tract communicating from terminal ileum to skin in the right iliac fossa (figures 2 & 3).

Figure 2

Figure 2

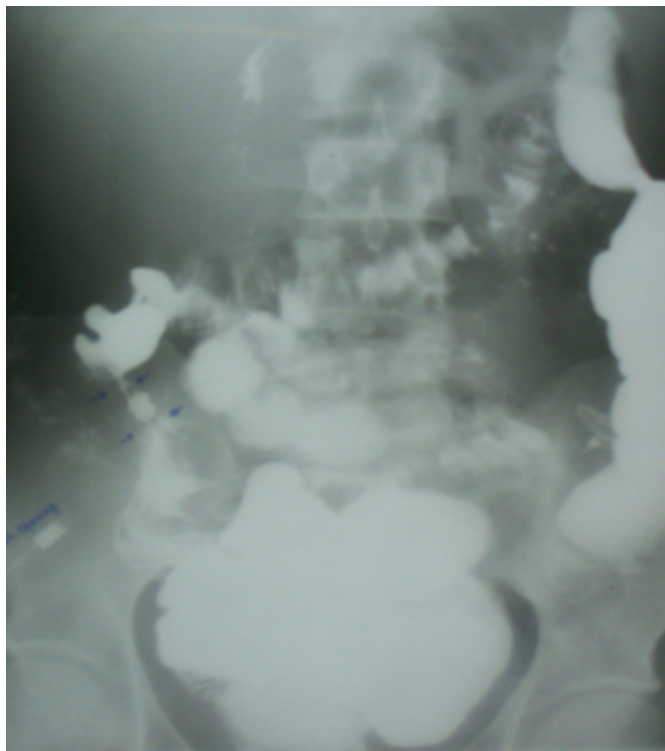
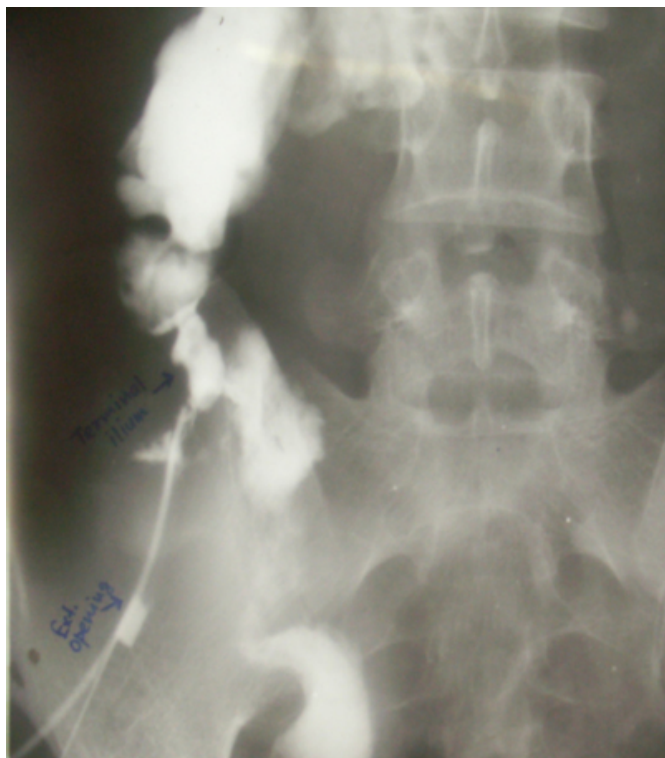

Figure 3

Figure 3



After complete bowel preparation, this patient was operated and fistulectomy with right hemicolectomy was performed

along with ileo-transverse anastomosis. Histopathologically, this fistulous tract showed transmural dense chronic inflammatory cellular infiltration and histiocytic proliferation with Langhans' type giant cell reaction. The features were that of tubercular enteritis, sections from lymph nodes biopsied showed features of tuberculosis. The patient was put on a directly observed short-course chemotherapy regimen for tuberculosis.

DISCUSSION

Though not spontaneous in strict sense, spontaneous enterocutaneous fistula is defined as fistula occurring 30 days after the primary therapy, i.e. either surgery or radiotherapy, is instituted ¹.

Events like cancer ², post- or pre-operative radiotherapy ³, Crohn's disease ⁴, typhoid fever ⁵ and intestinal tuberculosis ⁶ have commonly been associated with fistulae formation. Other causes are iatrogenic, diverticulosis, appendicitis, pancreatitis, trauma or foreign body ⁶. In rare instances, congenital hernias ⁷ and even Littré's hernia ⁸ also are known to be cause of such a fistula.

Enterocutaneous fistulae are classified into four types based on the modified Sitges-Serra classification ¹ proposed by Schein and Decker ⁹. Type I fistulae are esophageal, gastric, and duodenal fistulae, type II fistulae involve small bowel; type III fistulae involve large bowel and type IV fistulae refer to all afore mentioned types draining through a large abdominal wall defect ³.

Based on the output, the fistulae are classified as high- and low-output fistula. Fistulae producing less than 500 cc output per day are classified as low-output fistulae while those with >500 ml per day are classified as high-output fistulae and this has a bearing on the management ¹. High-output fistulae usually require surgical intervention while low-output fistulae in well-preserved individuals may be given a trial of conservative management ³.

In cases with low-output fistula early management with hyperalimentation, octreotide ¹⁰, and omega-3 fatty acids may be attempted but with limited success. Eventually, a large number of patients with low- and most of the patients with high-output enterocutaneous fistulae require surgical management in form of fistulectomy with resection of part of the involved bowel with some form of anastomosis ².

In our patient management was not done in phased manner as the patient was not nutritionally depleted and thus never

required hyperalimentation, which usually is needed for management of such cases. Despite being a low-output fistula, surgical management was planned for this patient as he presented to us 5 months after the fistula formation, and also because the edges of the fistula were completely epithelialised. Also the contrast study had shown a stricture in the terminal small bowel segment.

Tuberculosis sometimes presents in bizarre forms and poses a diagnostic challenge; a high index of suspicion is required especially in endemic countries.

CORRESPONDENCE TO

Dr. Mayank Pancholi, Resident, Department of Surgery, MGM Medical College and MY Hospital, Indore (MP), India PIN 452001 E-mail: coolmay4u@yahoo.co.in Contact no. 0919926412421

References

1. Sitges-Serra A, Jaurrieta E, Sitges-Creus A. Management of postoperative enterocutaneous fistulas: The role of parenteral nutrition and surgery. *Br J Surg*. 1989;69: 147-150.
2. Chamberlain RS, Kaufman HL, Danforth DN. Enterocutaneous fistula in cancer patients: etiology, management, outcome, and impact on further treatment. *Am Surg* 1998; 64: 1204-11.
3. Chintamani, Badran R, Rk D, Singhal V, Bhatnagar D. Spontaneous enterocutaneous fistula 27-years following radiotherapy in a patient of carcinoma penis. *World Journal of Surgical Oncology* 2003; 1: 23.
4. Hollington P; Mawdsley J; Lim W; Gabe SM; Forbes A; Windsor AJ. An 11-year experience of enterocutaneous fistula. *British Journal of Surgery* 2004; 91: 1646-1651.
5. Edeweile BO, Ifeoma CA, and Ifeoma G. Spontaneous enterocutaneous fistula. A rare presentation of enteric fever. *Journal of the National Medical Association, Nigeria* 2006; 98: 1694.
6. Perry J, Pickhardt PJ, Bhalla S, Balfe DM. Acquired Gastrointestinal Fistulas: Classification, etiologies, and imaging evaluation. *Radiology* 2002; 224: 9-23.
7. Leslie MD, Slater ND, Smallwood CJ. Small bowel fistula from a Littre's hernia. *Br J Surg* 1983; 70: 244.
8. Ameh EA, Awotula OP, Amoah JN. Spontaneous scrotal faecal fistula in infants. *Pediatr Surg Int* 2002; 18: 524-5.
9. Schein M, Decker GAG. Postoperative external alimentary tract fistulas. *Am J Surg* 1991; 161: 435-438.
10. Draus JM Jr, Huss SA, Harty NJ, Cheadle WG, Larson GM. Enterocutaneous fistula: are treatments improving? *Surgery* 2006; 140: 570-6.
11. Memon AS, Siddiqui FG. Causes and management of postoperative enterocutaneous fistulas. *J Coll Physicians Surg Pak* 2004; 14: 25-8.

Author Information

Mayank Pancholi, MBBS, MS(Std)
MGM Medical College & MY Hospital

M. Wadhwani, MBBS, MS
MGM Medical College & MY Hospital

Parvinder S. Lubana, MBBS, MS
MGM Medical College & MY Hospital

D.K. Jain, MBBS, MS
MGM Medical College & MY Hospital