

# Minimizing Chondral Damage During Arthroscopic Meniscal Repair Using Portal Guards

D Parikh, D deVilliers, A Ali

## Citation

D Parikh, D deVilliers, A Ali. *Minimizing Chondral Damage During Arthroscopic Meniscal Repair Using Portal Guards*. The Internet Journal of Orthopedic Surgery. 2005 Volume 3 Number 2.

## Abstract

Iatrogenic chondral damage of the knee joint is a likely possibility during knee arthroscopy when sharp tools are used. We report a practical, simple and cost effective technique in order to prevent potential damage to the articular cartilage of the knee during arthroscopic meniscal repair.

A paediatric endotracheal tube, which is readily available in all operating theatres, was used to protect the surrounding soft tissue and cartilage from damage.

This technique does not require ordering any extra instrumentation and reduces the operating time by allowing a quicker, safer and reproducible access to the meniscus during arthroscopic repair.

## INTRODUCTION

Meniscal tears are usually caused by excess axial load or shear stress within the knee joint. Menisci act as shock absorbers in the knee and convert the axial load into radial strain so as to disperse the weight over a larger surface area and prevent chondral damage [18]. Many studies have shown that meniscectomy increases the risk of osteoarthritis [6,8,9,10,12,13,14,15,16]. Several reports however have recommended meniscal repair to be undertaken in all cases of meniscal tear injuries [3]. Despite the controversies regarding the technique used, internal biodegradable devices are increasingly being used for this purpose [5].

However, occasional complications such as cyst formation, chondral damage and transient posterior knee pain have been reported [4,7,11,17,20]. Late reabsorption of the device, inaccurate insertion of rigid absorbable fixators and breakage may lead to chondral damage [1,2,19]. Iatrogenic chondral damage at the time of insertion is another concern; in particular with sharp devices which have no protective sheath for safe insertion.

Only a few devices available in the market today are designed with a plastic cannula or sheath to protect the articular cartilage. However most of the devices have introducers with sharp spikes which could cause a serious injury to the articular cartilage. Cannula sheaths which

function as tissue guards may not be available for this purpose or might be an expensive necessity that has to be ordered preoperatively. Repetitive insertion of this sharp introducer could be hastened with a protective sheath to maintain the orientation and the pathway through the portal hole to the meniscal site.

We use a sterile plastic paediatric endotracheal tube routinely as a tissue guard in our arthroscopic meniscal repair whenever the meniscal repair system is not equipped with a cannula to guard the portal holes.

We present a case where an endotracheal tube was used as a cannula in the portal hole to protect the surrounding structures while advancing the sharp meniscal repair introducer.

## CASE REPORT

A 25 year old male who had sustained a knee injury while playing football, was referred to the Orthopaedic Clinic two weeks later, complaining from a painful locked knee (with active and passive range of knee flexion from 15° to 120°). This was associated with medial joint line tenderness and moderate knee effusion. Medial meniscus tear was diagnosed and urgent therapeutic arthroscopy was performed a week later.

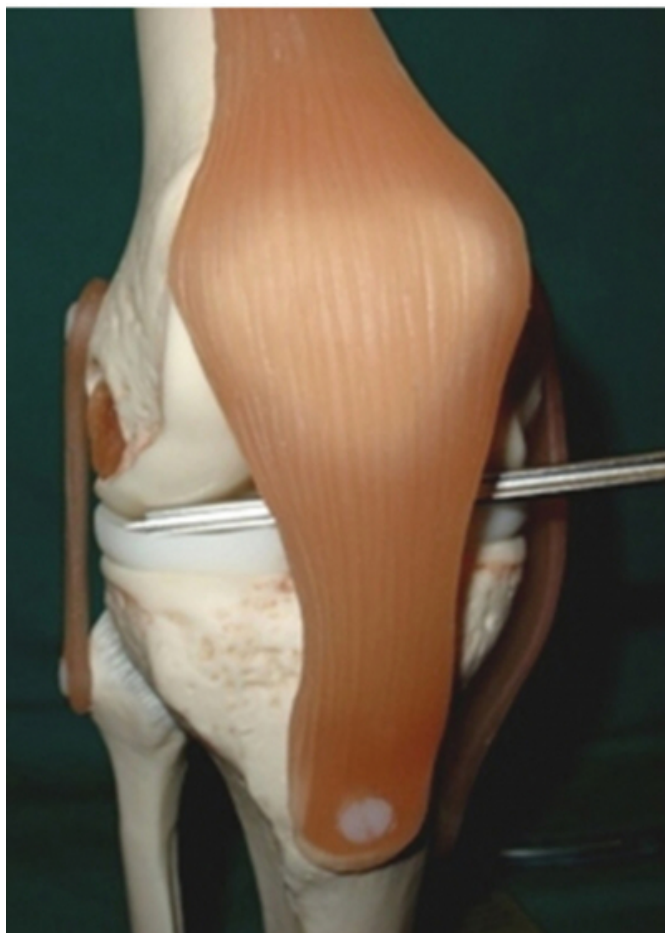A traditional two portal knee arthroscopy was performed

which showed a medial meniscus bucket handle tear. As this was fresh injury with peripheral tear (in the red-red area), this was suitable for meniscal repair which was undertaken arthroscopically as all-inside technique, using bio absorbable meniscal staple

The distal end of a size 6.0 paediatric endotracheal tube was inserted through the medial portal hole and advanced to the site of the tear under direct vision. The size of the tube was large enough to allow the introduction and manoeuvres of different instrumentation (probe, meniscal gun, meniscal rasp) within the knee joint in a controlled fashion. The medial meniscus was prepared for the repair by adequate trimming of the edges to stimulate healing.

**Figure 1**

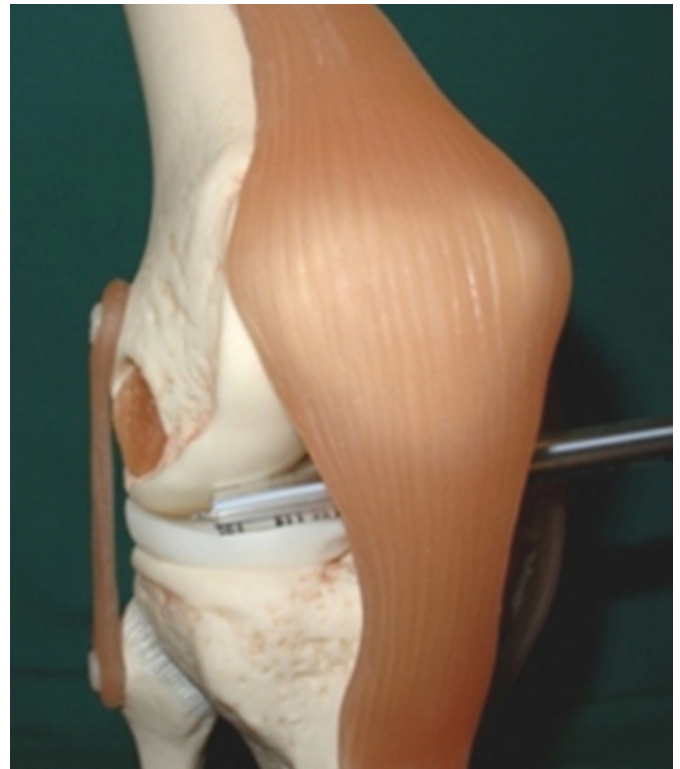Figure 1a: Model reconstruction of arthroscopic repair without guards



The meniscus staple gun was then introduced through the cavity of the endotracheal tube till it touched the meniscus. [Figure – 1(a), 1(b) ] After adequate positioning, the trigger was pulled to allow good approximation of two edges.

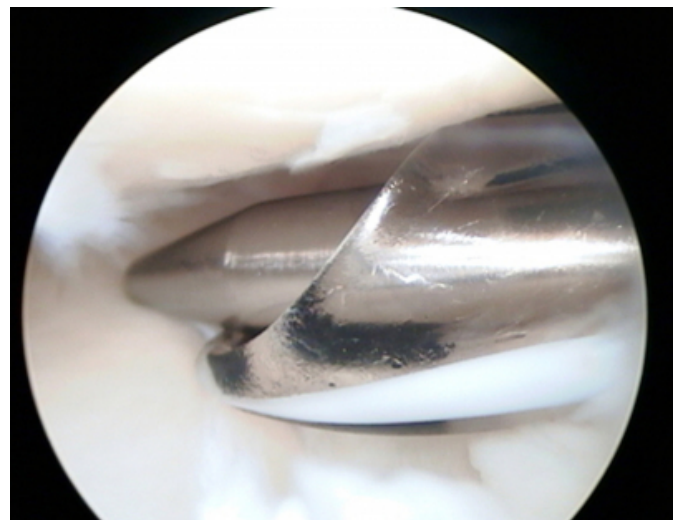
**Figure 2**

Figure 1b: Model reconstruction of arthroscopic repair with guard.



**Figure 3**

Figure 2: Arthroscopic view of actual repair with portal guards applied.



The procedure of introducing the sharp gun through the endotracheal tube was repeated and three more staples were inserted until the meniscus was stable enough to withstand a reasonable mechanical force applied by the probe.

## DISCUSSION

All arthroscopic trocars, probes as well as meniscal trimming and shaving instrumentations are designed to be blunt and smooth in order to minimize articular cartilage damage or scratches. However, in arthroscopic meniscal repair surgery, the sharp instruments are inevitable, as they are essential for accurate insertion of meniscal sutures or fixators. The arthroscopic skills of the operating surgeon are an important prerequisite for safe repair in order to avoid forcible repetitive introduction of these sharp instruments, which can scratch and cut the chondral surfaces. This damage could be avoided by using a soft tube as a guide for the repeated introduction of these tools in a controlled environment.

Some companies are already providing similar guides, but these guides are not always available readily on shelves and they might involve extra costs. Others manufactures do not have any system to protect and facilitate safe insertion of there sharp introducers.

## CONCLUSION

We recommend the use of a sterile paediatric endotracheal tube as a portal tissue guard in arthroscopic meniscal repair whenever the sharp instrumentations are not equipped with a cannula guard. This portal guard functions as protective tissue pathway which maintains the orientation and the passage of the sharp introducer through the portal hole to the meniscal site. The use of this portal guard in association with gentle handling of the sharp instruments within the knee, can guarantee minimal intra-articular chondral damage in addition of decreasing the operating time involved in arthroscopic meniscal repair surgery.

## CORRESPONDENCE TO

Mr Ahmad M. Ali, Consultant Trauma & Orthopaedic Surgeon, Department of Orthopedics and traumatology, Oldchurch Hospital, Waterloo Road, Romford, Essex RM7 0BE, UK. Tel: 00 44 1708 708 478 Fax: 00 44 1708 708 477 E-mail: amali@rcsed.ac.uk

## References

1. Anderson K, Marx RG, Hannafin J et al. Chondral injury following meniscal repair with a biodegradable implant. *Arthroscopy* 2000; 16 : 749-753
2. Asik-Mehmet, Atalar-Ata-Can. Failed resorption of bioabsorbable meniscus repair devices. *Knee Surg, Sports Traumatol, Arthrosc* 2002; 10 : 300-304
3. Boyd-Kevin-T, Myers-Peter-T. Meniscus preservation; rationale, repair techniques and results. *The Knee* 2003; 10 : 1-11
4. Calder SJ, Myers PT. Broken arrow : a complication of meniscal repair. *Arthroscopy* 1999; 15 : 651-652
5. Canal ST. Arthroscopic repair of torn meniscus. *Campbell's Operative Orthopaedics*, 10th Edition, 2003. Vol 3. 2543 - 2555
6. Chatain F, Robinson AHN, Adeleine P et al. The natural history of knee following arthroscopic medial meniscectomy. *Knee Surg, Sports Traumatol, Arthrosc* 2001; 9 : 15-28
7. Cohen Steven B, Anderson Mark W, Miller Mark D. Chondral injury after arthrisopic meniscal repair using bioabsorbable Mitek Rapidloc meniscal fixation. *Arthroscopy* 2003; 19 : 24-26
8. Ellerman A, Siebold R, Buelow J U, Sobau C. Clinical evaluation of meniscus repair with a bioabsorbable arrow : a 2-3 year follow up study. *Knee Surg, Sports Traumatol, Arthrosc* 2002; 10 : 289-293
9. Fairbank TJ. Knee joint changes after meniscectomy. *J Bone Joint Surg* 1948; 30 : 664
10. Johnson M J, Lucas G L, Dusek J K, Henning C E. Isolated arthroscopic meniscal repair : a long term outcome study. *The American Journal of Sports Medicine* 1999; 27 : 44-49
11. Kimura M, Hagiwara A, Hasegawa A. Cyst of the medial meniscus after arthroscopic meniscal repair. *Am J Sport Med* 1993; 21:755-757
12. King D. The function of semilunar cartilages. *J Bone Joint Surg* 1936; 18 : 1069
13. King D. The healing of semilunar cartilages. *J Bone Joint Surg* 1936; 18:333
14. Kruger-Franke M, Siebert CH, Kugler A et al. Later results after arthroscopic partial medial meniscectomy. *Knee Surg, Sports Traumatol, Arthrosc* 1999; 7 : 81-84
15. Maletius W, Messner K. The effect of partial meniscectomy on the long-term prognosis of knees with localised, severe chondral damage. *Am J Sport Med* 1996; 24 : 258-262
16. Schimmer RC, Brulhart KB, Duff C et al. Arthroscopic partial meniscectomy. A 12- year follow-up and two-step evaluation of long term course. *Arthroscopy* 1998; 14 : 136-142
17. Seil R, Rupp S, Dienst M, Mueller B, Bonkhoff H, Kohn D M. Chondral lesions after arthroscopic meniscus repair using meniscus arrows. *Arthroscopy* 2000; 16 : 17
18. Shrive NG, O'Connor JJ, Goodfellow JW. Loadbearing in knee joint. *Clin Orth* 1978; 13:279-287
19. Schneider-Frank, Schroeder-Joerg-H, Labs-Karsten. Failed meniscus repair. *Arthroscopy* 2003; 19 : 8-11
20. Whitman TL, Didruch DR. Transient posterior knee pain with the meniscal arrow. *Arthroscopy* 1998; 14 : 762-263

**Author Information**

**Dharam Parikh, MBBS**

Senior House Officer - Orthopaedics, Department of Orthopaedics and Traumatology, Oldchurch Hospital

**Dennis deVilliers, MB.Ch.B, F.F.A(SA), MBA**

Consultant Anaesthetist, Department of Orthopaedics and Traumatology, Oldchurch Hospital

**Ahmad M. Ali, MD, M.Ch.Orth., FRCS.Orth, FEBOT**

Consultant Trauma & Orthopaedic Surgeon, Department of Orthopaedics and Traumatology, Oldchurch Hospital