

Post appendectomy pain in right iliac fossa: A story of olden days or the problem of recent era

K Sarda, K Kher, D Wagh, M Yeola, M Chauhan, B Wani

Citation

K Sarda, K Kher, D Wagh, M Yeola, M Chauhan, B Wani. *Post appendectomy pain in right iliac fossa: A story of olden days or the problem of recent era*. The Internet Journal of Gastroenterology. 2009 Volume 9 Number 1.

Abstract

Acute appendicitis is essentially a clinical diagnosis supported by haematological and radiological investigation with appendectomy as treatment of choice. But all patients are not relieved off their symptoms following surgery. The aim of this study was to evaluate the patients who continue to visit hospital even after removal of the appendix at Acharya Vinoba Bhave Rural Hospital Sawangi Meghe Wardha during the period from June 2006 to August 2008. Of all 30 patients studied most common cause was ureteric colic in 6 (20%) patients and sub acute intestinal obstruction due to post operative adhesions in 6 (20%) cases, while rest of other causes included Urinary tract infections, Hypertrophied scar, Amoebic Colitis, Psychiatric or functional disorders.

INTRODUCTION

Appendectomy is one of the commonest abdominal operations performed during emergency hours for acute appendicitis. It is the common inflammatory pathology in right lower abdomen. Acute appendicitis is essentially a clinical diagnosis supported by hematological and radiological investigation. If untreated can progress to appendicular perforation & peritonitis. Hence treatment of choice is appendectomy. Postoperative complications following appendectomy are relatively not uncommon and reflect the degree of peritonitis that was present at the time of operation, intra-operative spillage and intercurrent diseases that may predispose to complications. Wound infection is the most common postoperative complication. Late complications include postoperative adhesive intestinal obstruction and right inguinal hernia. But all patients are not relieved off their symptoms following surgery. The large numbers of patients continue to visit surgical OPD for continuous pain in right iliac fossa even after appendectomy being performed.

METHODS AND MATERIALS

The present study was conducted at Acharya Vinoba Bhave Rural Hospital Sawangi (Meghe) Wardha during the period from June 2006 to August 2008. The aim of this study was to evaluate the patients who continue to visit hospital even after removal of the appendix. It was tried to establish the correlate in between relief of pain and histo-pathological

report of appendix. We designed the questioner to find out exact cause of pain or postoperative complications that leads patient to visit surgical OPD often. Other pathologies if were overlooked in previous surgery may cause persistent pain in right iliac fossa. After appendectomy when patients come for follow up we could find out certain causes those were not detected at the time of previous surgical intervention, or were found out after persistence of pain after appendectomy. Various reasons for persistent pain in right iliac fossa those after thorough evaluation were associated with some significant pathology that required definitive management. The patients, who had been operated for appendicitis but who continue to visit for pain in right iliac fossa, were studied. The patients of either sex and of any age were studied and investigated to establish organic cause for pain in right iliac fossa. All such patients, who on investigations were not showing any organic causes, were subjected to psychological evaluation.

OBSERVATION AND DISCUSSION

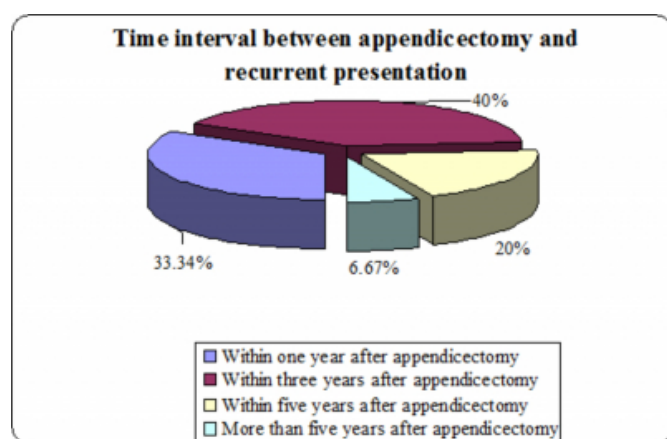
This study included 30 cases who were operated for appendicitis, continue to visit hospital for continuing pain in abdomen especially right iliac fossa for more than 4 weeks. Out of 30 cases, 18 patients (60%) were female and 12 (40%) were males. Piper et al¹ have shown that the diagnostic accuracy for appendicitis is low in female patients than in males. Their study of 1018 cases showed that the diagnosis was correct in 77.7% of the males and 58% of the

females with error in diagnosis of 22.3% with males and as high as 42% with females. The overall diagnostic accuracy was low in female's patients. The main reason for it, they concluded, was presence of gynecological disorders in as high as 15.5% of cases. In our study 60% female patients presented with recurrent symptoms as against 40% of male patients suggesting diagnostic accuracy was less in females; with as high as 4 (13.33%) patients with gynecological problems in form of urinary tract infection.

Thus of the 30 cases, 24 patients (80%) were in the age group 20-40 years. The preponderance of patients in this age group can be explained by the fact that this is the age group in which patients are subjected to maximum stress and strains of life and hence more prone for psychological trauma. Same findings were given by Ingram et al, they stated that out of 118 young patients who were subjected to appendectomy, only 24% of them got relief of symptoms. Thus either doubting clinical diagnostic accuracy in this age group or association of other pathologies. Piper et al ¹ have also shown that diagnostic accuracy falls to 52.7% in the patients in the age group 10 to 39 years. They found variety of other conditions in 139 patients which included; mesenteric adenitis (63 patients), gynecological disorders (26 patients), gastroenteritis (24% patients) and urinary tract infection or stones (12 patients). Thus larger number of young patients coming with recurrent pain is explainable.

There are many conditions those mimic appendicitis thus clinical diagnostic error has been reported by various authors' varies from 10 to 42% even with recent advances in radiological diagnosis .thus approximate incidence of negative appendectomy is 10%. Jinxing et al ² in 1981 suggested errors in diagnosis around 15%. Per Jess ³ in 1998 reported diagnostic accuracy of around 70%.

Figure 1



Thus, 22 patients (73.34%) presented in first 3 years. Hospital statistics showed that about 150 appendectomies are performed in this hospital per annum. Out of total 30 patients, 20 were operated during emergency hours with diagnosis of acute appendicitis, 10 were operated as elective cases with diagnosis of chronic appendicitis. The continuing symptoms even after removal of inflamed appendix can be explained by. Greene JM ⁴ had shown that incomplete removal of appendix result for failure of the surgeon to locate true appendicocaecal junction due to abnormally situated ileocaecal fold or an inflammatory process that conceals the proximal portion of the appendix. This remaining stump may be a seat for subsequent inflammation. In his study Greene presented three cases who presented either with stump appendicitis and or with perforation. We found one patient (3.33%) with clinical diagnosis of stump appendicitis which on radiological study with barium meal follows through examination also suggestive of query stump appendicitis. Patient presented with acute pain in right iliac fossa following appendectomy and responded to conservative measures.

Inability to recognize associated pathologies and technical mistakes can cause recurrent symptoms. In this hospital the method of invagination of ligated appendicaecal stump with purse sting suture is routinely followed. Goode J V ⁵ has raised the possibility of "Caecal pocket abscess" following this method. The possibility of this can not be ruled out for continuing pain in right iliac fossa. The surgical removal of chronically inflamed appendix is not surety for abolition of symptoms. In our study 10 (33.33%) patients who underwent elective appendectomies came with recurrent pain. Ian McLennan ⁶ studied 413 cases of chronic appendicitis who underwent surgery. Out of it 83.5% female and 74.2% male patients had relief. Rest 16.5% females and 25.8% male patients had continuing pain. He concluded that existing adhesions, kinks and fibrosis renders surgical procedure inaccurate and tedious. In our study the prevalence was 6 females and 4 males who continued with pain even after appendectomy for chronic appendicitis.

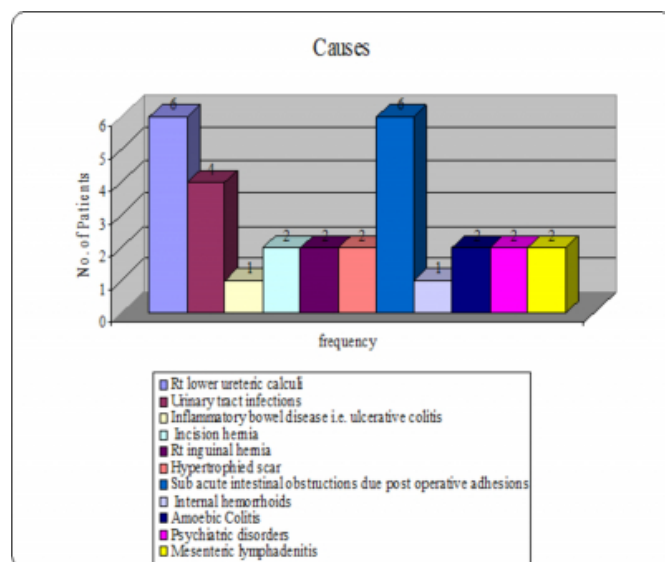
Thus all 30 patients presented with pain in right iliac fossa. This symptom was major criteria for selection of patients. (Figure 2) The urinary complaint in the form of burning in micturation was associated complaint in 14 patients (46.62%). Out of these 14 patients; 8 patients (26.67%) had demonstrable cause for their complaint, 6 (20%) patients had right ureteric calculus in lower third of right ureter. Two (6.67%) patients had changes of hydronephrosis on right

side. This patient had appendicular abscess at initial attack. Retrograde pyelography did not show any stricture distally. American urologists have stressed the fact that minor degree of congenital narrowing of a ureter. Where it crosses pelvic brim, often exists. It generally causes pain in right iliac fossa and explains some cases of failure of appendectomies to relieve pain. Four (13.33%) patients had chronic urinary tract infection and responded to treatment. Piper et al ¹ had shown that in their study cause for persistent right iliac fossa pain was urinary tract infection and stones in 12 out of 139 patients with 8.6% prevalence.

Three patients had associated vomiting. Out of these all three had urinary tract disease. Thus, patients of appendicitis may have associated urinary tract pathologies which should not overlooked. Associated urinary tract disease is cause or effect of appendicitis can not be stated firmly but possibility of either can not be ruled out. The recognition of associated lesion and its treatment can lead to abolishing of future agony. Two patients (6.67%) presented with pain in Right iliac fossa with mucoid stool. On stool examination stool for ova and cyst was found positive, both responded well to medical treatment. Jinxing Yu et al ² in their study suggested radiological features to differentiate it from acute appendicitis. Two patients (6.67%) had bleeding per anus. On examination one had internal piles which responded to conservative treatment.

Figure 2

Figure 2: Distribution of causes of right iliac fossa pain



One (3.33%) on barium study found to have inflammatory bowel disease as ulcerative colitis with loss of haustration pattern and treated on medical line of management. The long

segmental wall thickening of the terminal ileum, the center of inflammation away from the appendix, and circumferential symmetric thickening of the caecum are the major features that differentiate Crohn's disease from appendicitis. Jain KA ⁷ suggested inflammatory bowel disease manifest as right iliac fossa pain keeping in mind as differential diagnosis.

Of 30 patients studied, 22 patients had right McBurnay's incision scar, 5 patients had right lower paramedial scar and one patient had infraumbilical midline scar. 2 underwent laparoscopic appendectomy. (Table 1)

Figure 3

Table 1: Distribution of incision for appendectomy

Sr.No.	Incision	No. Of Cases
1	Mc Burney's	22 (73.33%)
2	Rt. Lower Para Median	5 (16.67%)
3	Infra Umbilical Midline	1 (3.33%)
4	Laparoscopic	2 (6.67%)

Six patients had ragged right McBurney's scar. Out of these six patients two patients (6.67%) had associated incisional hernia at scar site, John Garlock ⁸ found incidence of incisional hernia in 6.4% of cases in study of 624 cases of appendectomies with right Mc Burney's incision. Another 2 patient (6.67%) with ragged right Mc Burney's scar had associated right indirect inguinal hernia. Gue S ⁹ studied 51 cases of indirect inguinal hernia with previous history of appendectomies. Out of these 41 cases had right inguinal hernia, 7 cases had left inguinal hernia and 3 had bilateral hernia. The incidence of right to left was being 6:1. Six patients had more than one scar on their abdomen. Two patients (6.67%) did not have organic cause for their pain, thus were subjected to psychological evaluation and were found to have "psychological pain disorder". Thus it is probably that the patients, who were subjected to multiple operations, are more prone for psychological trauma. Joan Gomez and Peter Dally ¹⁰ evaluated 96 patients complaining of persistent abdominal pain only 15 patients 15.6% had organic disorder. In the reminder, 81 patients (84%) psychological factors were considered primary cause for the pain. But in our study 6.67% patients found to have psychological pain in form of severe depression and anxiety disorder. Two (6.67%) patients had hypertrophied granulation tissue at scar site which was due to a piece of

thread in subcutaneous tissue. Duce AM¹¹ in his study suggested that cause of the first operation wound infection, seroma, the use of catgut to suture the aponeurosis, and interrupted suture to the aponeurotic layer can cause hypertrophied scar. In our study prevalence was 6.67%. Four patients underwent diagnostic laparoscopy for persistent pain in right iliac fossa. Intra operative findings were adhesions at the base of appendix and underwent adhesiolysis with electro cautery and got relieved of symptoms. In study Chard SA¹² suggested that post operative intestinal adhesions are the most common clinical entity causing recurrent pain after appendectomy or even after any pelvic surgery. Postoperative adhesiolysis may relieve the pain in most of cases. In our study four patients who got relived of pain after adhesiolysis (13.33%). Two patients (6.67%) with Sub Acute Intestinal Obstruction resolved well with conservative line of management with antibiotic. Two patients (6.67%) had mesenteric lymphadenitis diagnosed on ultra sound examination and found to have symptoms due to non-specific lymphadenitis. Mesenteric adenitis represents a benign infection or inflammation of the lymph nodes within the mesentery that results in abdominal pain, often mimicking appendicitis clinically, Piper et al¹ found variety of other conditions in 139 patients which included, Mesenteric adenitis (63) that turned out to be 45.32% In our study we could manage these two patients with conservative line of management.

Laparoscopic appendectomy having better results than open as in our study only 2 patients presented with postoperative pain after appendectomy as compared to open (28) appendectomy. Greason K L¹³ suggested that Laparoscopic removal of the appendix produces no added morbidity and associated with less post operative co morbidity. In our study we could find histopathologically all the patients were correctly diagnosed for pathology. (Table 2) But post appendectomy pain more commonly found in relation to acute appendicitis on histopath study. Cause may be procedure related in emergency surgery as well prolonged sepsis in acute condition. In our study acute appendicitis on histopathology was seen in 19 cases but chronic was found in 10 cases. One report was acute on chronic appendicitis. Samsi AB¹⁴ in the study of 100 consecutive cases of acute appendicitis with their histopathological findings found no correlation with histopathological diagnosis.

Figure 4

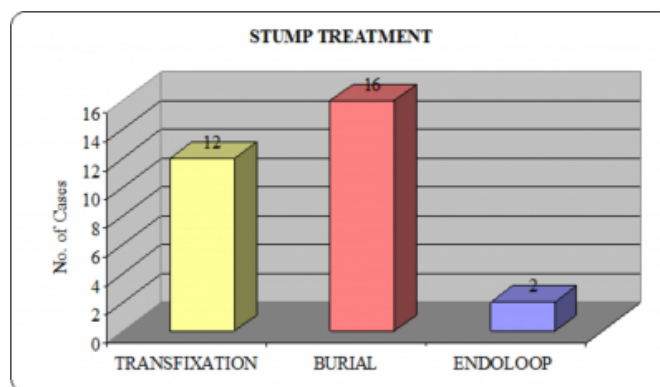
Table 2: Histopathological Correlation

Sr.No.	Histopathological Report	No. Of Cases
1	Acute Appendicitis	19
2	Chronic Appendicitis	10
3	Acute on Chronic Appendicitis	1

In our study previous stump treatment was studied in which we get post operative pain more with stump transfixation with 12 cases, 16 cases with stump burial while 2 patients with endoloop application. (Figure 3)

Figure 5

Figure 3: Post-appendectomy stump treatment



Goode JV⁵ also found that stump treatment with stump invagination leads “caecal pocket abscess” formation which later on present as post operative pain. Thus suggesting transfixation of stump is following lesser complication rate in open appendectomy as compared to stump burial. While endoloop applications having even less complications in case of laparoscopic appendectomy.

In this study we could find out that even after appendectomy as a therapeutic measure for acute or chronic appendicitis some number of patients who repeatedly follow for persistent pain in right iliac fossa should not be neglected. We could find in our study various reasons for persistent pain in right iliac fossa those after thorough evaluation were associated with some significant pathology that required definitive management. We can take preventive measures to avoid further complications if patient is treated in time.

SUMMARY AND CONCLUSION

No patient, who is coming with recurrent pain in right iliac fossa, should be overlooked. Many of them may have organic cause for their symptoms. The maximum stress and

strain of life in young age and female sex could be associated factor. Histopathologically confirmation is not surety for abolishing of symptoms. Urinary tract disease in the form of calculus nephropathy and or associated infection of urinary tract is major cause for symptoms. The patient who visits hospital after one laparotomy should not be subjected to further surgery unless indicated and fully evaluated. The patients with multiple scars on their abdomen are more prone for psychological trauma. Inflammation of remaining stump of appendix is not uncommon technical error during surgery can lead to longer stump which can be future cause for morbidity. Incisional hernia of scar site following right McBurney's incision is not uncommon. The prolong sepsis at wound site is main contributing factor for occurrence of hernia. The patient with recurrent pain in right iliac fossa following appendectomies should be subjected to psychological evaluating if no organic cause is found. Laparoscopic appendectomy having better out come than open appendectomy with less number of post operative complications. Stump treatment in case of open appendectomy is having better out come with transfixation than stump burial as "caecal pocket abscess" formation is the known complication of stump burial.

References

1. Piper R, Kager L. Acute appendicitis: A clinical study of 1018 cases of emergency appendectomy. *Acta Chir Scand* 1982;148:51.
2. Jinxing Yu, Fulcher AS, Turner MA, Halverson RA, Fulcher AS, Turner MA, Halvorsen RA. Helical CT Evaluation of Acute Right Lower Quadrant Pain: Part I, Common Mimics of Appendicitis. *AJR* 2005;184:1136-1142
3. Jess Per. Acute appendicitis prospective trials concerning diagnostic accuracy and complications. *Am J Surg* 1981;141:232.
4. Green JM. Incomplete removal of appendix: its complications. *Journal of Int Col Surg* 1958;29:141.
5. Goode JV. Management of appendiceal stump. *Annals Surgery* 1943;13:956-963.
6. Mc Leanan, Watt JK. Justification for appendectomy in chronic appendicitis. *Br Med Journal* 1954;2:738.
7. Jain KA, Quam JP, Ablin DS, Gerscovich EO, Shelton DK. Imaging findings in patients with right lower quadrant pain: alternative diagnoses to appendicitis. *J Comput Assist Tomogr* 1997;21:693-698.
8. Garlock John et. al. Appendectomy wound repair and hernia. *Annals Surgery* 1992;89:282.
9. Gue S. Development of right inguinal hernia following appendectomy. *Br Med Journ* 1972;59:352.
10. Gomez AL, Peter KS. Psychological mediated abdominal pain in surgical and medical out patients clinic. *Br Med Journ* 1977;1:1451.
11. Duce AM, Lozano O, Villeta R. Acute appendicitis prospective trials concerning diagnostic accuracy and complications. *Am Surg* 2003;134:549-52.
12. Cuadra SA, Khalife ME, Char DJ, Wax MR, Halpern D. Laparoscopic lysis of adhesions for post appendectomy pain. *Surg Endosc*. 2002;16:21.
13. Greason KL, Rappold JF, Liberman MA. Incidental laparoscopic appendectomy for acute right lower quadrant abdominal pain. Its time has come. *Surg Endosc* 1998;12:223-5.
14. Samsi AB, Adarkar NV, Kamat RS. A study of 100 consecutive cases of acute appendicitis with their histopathological findings. *Ind J Surg* 1969;3:574-579.

Author Information

Kaustubh Sarda

Assistant Professor, Department of Surgery, JNMC Sawangi (Meghe)

Kiran Kher

Professor, Department of Surgery, JNMC Sawangi (Meghe)

Dhirendra Wagh

Professor, Department of Surgery, JNMC Sawangi (Meghe)

Meenakshi Yeola

Professor, Department of Surgery, JNMC Sawangi (Meghe)

Mahendra Chauhan

Assistant Professor, Department of Surgery, JNMC Sawangi (Meghe)

Bhushan Wani

Resident, Department of Surgery, JNMC Sawangi (Meghe)