

Case Of The Month: Case 1/2001

P Yeh, D Kim, J Nates

Citation

P Yeh, D Kim, J Nates. *Case Of The Month: Case 1/2001*. The Internet Journal of Anesthesiology. 1999 Volume 5 Number 1.

Abstract

INTRODUCTION

A 55 year-old white male arrived to the Neuro-ICU of our institution with an altered mental status and under the influence of alcohol. The patient had been found in his garage unconscious, and had repeatedly stated that he had tried to kill himself shooting 2 nails in his head with a carpenter's nail pistol. By the time he arrived to the emergency room, he was awake and alert, responsive and conversant. He did not have any cranial nerve palsies, and his peripheral examination was normal, with no motor or sensory deficits.

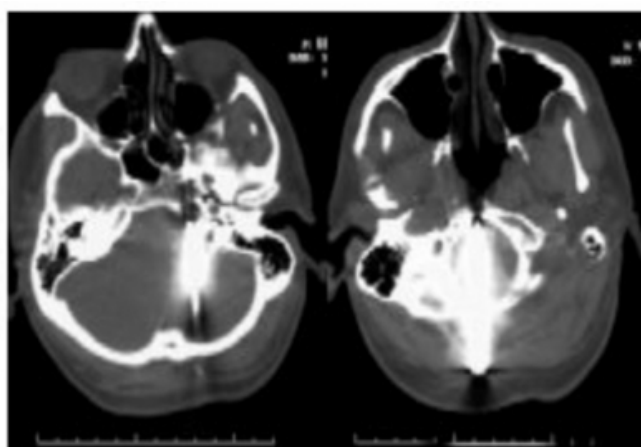
Figure 1

Plain film

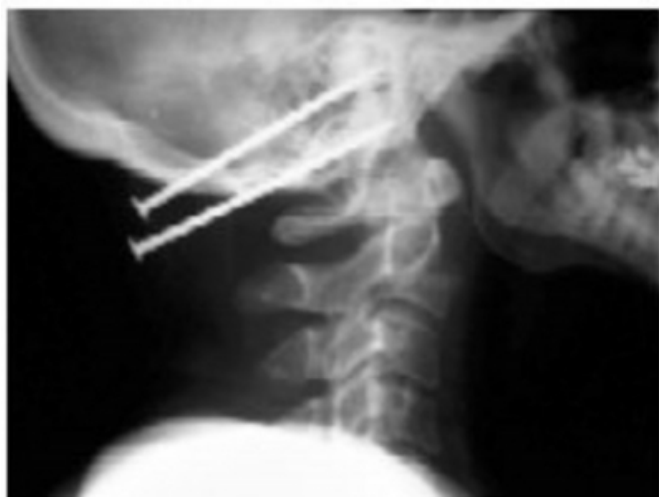

Figure 2

CT-scan of the brain on arrival



QUESTIONS

1. What structures have been injured?
2. What other tests would you request to confirm your diagnosis?
3. What is the management of this condition?
4. What are the possible complications of this injury?
5. What do you think was this patient's outcome?

ANSWERS

1. What structures have been injured?

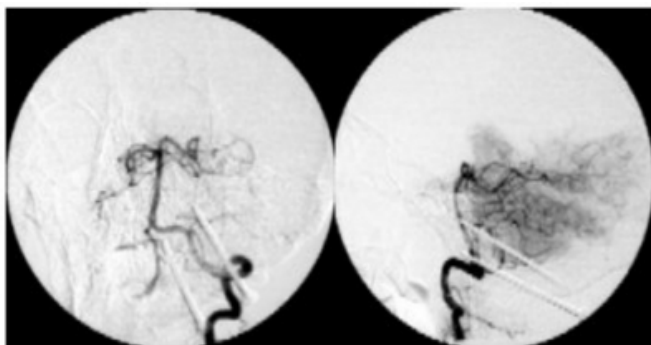
Answer: One of the nails traversed the foramen magnum in the midline penetrating the vermis of the cerebellum and the medulla. The second nail traversed the left cerebellar hemisphere causing a mild hemorrhagic contusion of the left cerebellar peduncle (as seen in CT above).

2. What other tests would you request to confirm your diagnosis?

Answer: Some authors recommend performing angiograms only when a vascular lesion is suspected (1). However, we think that an angiogram can prove to be very useful in surgical planning even if no vascular injury is shown (see picture of angiogram in the above patient below). Of course, MRI is contraindicated in this and other similar cases.

Figure 3

Angiogram: vertebral injection, lateral and oblique views



There is normal filling of the distal vertebral, basilar, bilateral posterior cerebral, superior cerebellar, anterior inferior cerebellar and posterior inferior cerebellar arteries. There is no evidence of acute arterial injury despite 2 nails traversing the posterior fossa.

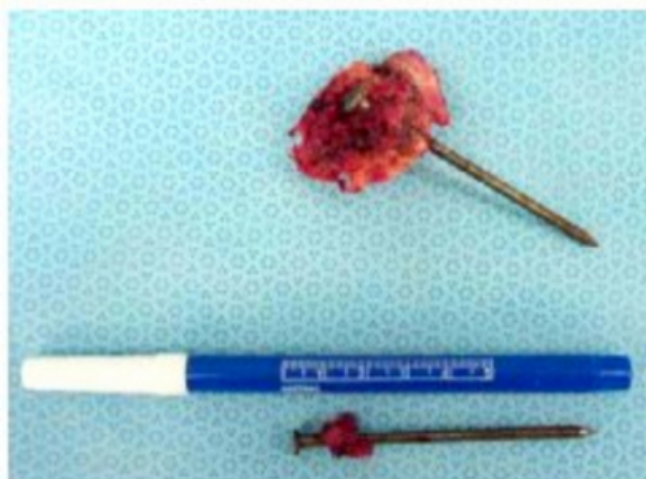
3. What is the management of this condition?

Answer: As in other penetrating brain injuries, the basic treatment should include debridement with removal of the foreign body and detritus (e.g. bone fragments, clots and necrotic tissue)(1). Hemostasis and closure of the dura mater are very important stages of the procedure to avoid intra- or post-operative hemorrhages and CSF leaks (1,2,3,4,5). Preoperatively, the patient was immobilized in a Philadelphia cervical collar. In the OR, after awake fiberoptic intubation and prone positioning as shown below, wide exposure of the suboccipital bone was made to gain access to the petrosal and suboccipital surfaces of the cerebellum, then the nails were removed. The entry site was then debrided and cleaned, and a tight closure performed.

Figure 4

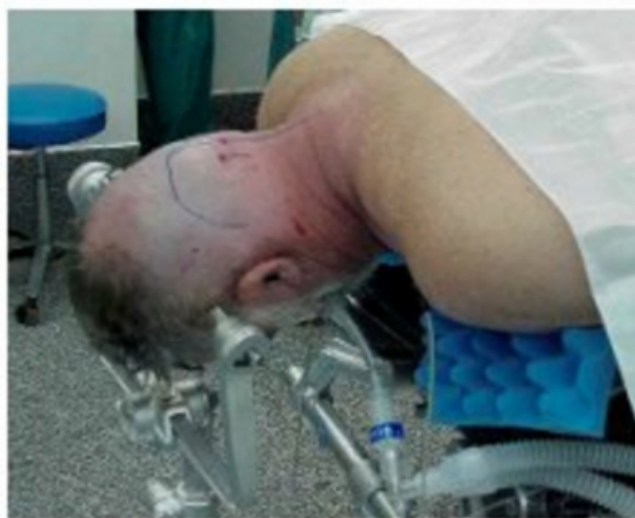

Figure 5



4. What are the possible complications of this injury?

Answer: The most worrisome complication would be hemorrhage within the medulla as the nail is removed. Other possible complications include wound infection, brain abscess, CSF leaks, venous thrombosis, cerebral blood flow reduction, cerebral vasospasm, arterio-venous fistulas, aneurysms, brain infarction, seizures and death (1,2,3,4,5,6,7,8,9).

5. What do you think was this patient's outcome?

Answer: This patient survived with no post-operative complications or neurological deficits!

References

1. López F; Martínez Lage JF; Herrera A; Sánchez Solís M; Torres P; Palacios MI; Poza M. Penetrating craniocerebral

- injury from an underwater fishing harpoon. Childs Nerv Syst, 2000 Feb, 16:2, 117-9
2. Unusual treatment of slaughterer's gun injury. Crevenna R; Homann CN; Ivanic G; Klintschar M Injury, 1999 Oct, 30:8, 537-8
3. Penetrating head injuries caused by a new weapon, the side dome. Sviri GE; Guilburd JN; Soustiel JF; Zaaroor M; Feinsod M. Mil Med, 1999 Oct, 164:10, 746-50
4. VanGurp G, Hutchinson TJ, Alto WA. Arrow wound management in Papua New Guinea. J Trauma 1990; 30:183-188.
5. Taylor AG, Peter JC. Patients with retained Transcranial knife blades: a high risk group. J Neurosurg 1997; 87:512-515.
6. Potapov AA; Yeolchiyan SA; Tcherekaev VA; Kornienko VN; Arutyunov NV; Kravtchuk AD; Shahinian GG; Likhterman LB; Serova NK; Eropkin SV. Removal of a cranio-orbital foreign body by a supraorbital-pterion approach. J Craniofac Surg, 1996 May, 7:3, 224-7
7. Kordestani RK; Martin NA; McBride DQ Cerebral hemodynamic disturbances following penetrating craniocerebral injury and their influence on outcome. Neurosurg Clin N Am, 1995 Oct, 6:4, 657-67.
8. Amirjamshidi A; Rahmat H; Abbassioun K Traumatic aneurysms and arteriovenous fistulas of intracranial vessels associated with penetrating head injuries occurring during war: principles and pitfalls in diagnosis and management. A survey of 31 cases and review of the literature. J Neurosurg, 1996 May, 84:5, 769-80
9. Kordestani RK; Martin NA; McBride DQ. Cerebral hemodynamic disturbances following penetrating craniocerebral injury and their influence on outcome. Neurosurg Clin N Am 1995; 6:4, 657-67.

Author Information

Peter J. Yeh, MD, Assistant Professor

Neurosurgery, University of Texas Medical School Houston

Dong H. Kim, MD, Assistant Professor

Director Cerebrovascular Surgery, Neurosurgery, University of Texas Medical School Houston

Joseph L. Nates, MD, Assistant Professor

Director Neurosciences ICU, Neurosurgery and Anesthesia/Crit. Care, University of Texas Medical School Houston