

# Insulinoma-Associated Acanthosis Nigricans. A Case Presentation

A , L , A , J

## Citation

A , L , A , J . *Insulinoma-Associated Acanthosis Nigricans. A Case Presentation*. The Internet Journal of Endocrinology. 2016 Volume 10 Number 1.

DOI: [10.5580/IJEN.45027](https://doi.org/10.5580/IJEN.45027)

## Abstract

We present a 31-year-old female, obese and hypertensive patient, who presented with recurrent episodes of hypoglycemia. She showed widespread acanthosis nigricans. Her acanthosis nigricans reversed in just few weeks after the removal of a pancreatic insulinoma. This quick regression we considered to be a strong evidence of the role played by hyperinsulinemia in the pathogenesis of this cutaneous condition.

## INTRODUCTION:

Insulinomas are rare endocrine tumors, with an incidence of four cases per million patients per year.<sup>1</sup> They however represent the commonest neuroendocrine tumors (55%) followed by gastrinomas (36%), VIPomas (vasoactive intestinal polypeptide tumor) (5%), and glucagonomas (3%). More than 90 % of them are benign.<sup>2</sup>

Most patients with insulinomas have symptomatic hypoglycemia resulting from neuroglycopenia and increased catecholamine release as a response to hypoglycemia. Neuroglycopenic symptoms include anxiety, dizziness, lightheadedness, personality changes, confusion, blurred vision, seizures, and coma. Some patients learn to avoid or mitigate their symptoms by eating during warning prodromal feelings. Sympathoadrenal signs and symptoms, such as palpitations, tremulousness, diaphoresis, and tachycardia, may also be present. Surgical excision is the treatment of choice and it is curative in most cases. At the time of surgery, the majority of these lesions are found to be solitary, equally distributed throughout the pancreas, and most of them are less than 2 cm in diameter.<sup>1</sup>

Acanthosis nigricans has been reported in few cases of insulinoma; not surprisingly since hyperinsulinemia and insulin resistance are considered key factors in the hyperplastic skin changes that characterize this condition.<sup>3</sup> It has been proposed that high levels of insulin and its binding to Insulin Growth Factor-1 receptors on keratinocytes and fibroblasts leads to proliferation of epidermis resulting in

acanthosis nigricans.<sup>4</sup>

We present a case with insulinoma, obesity and acanthosis nigricans with resolution of symptoms and regression of skin changes after removal of the tumor.

## CASE REPORT:

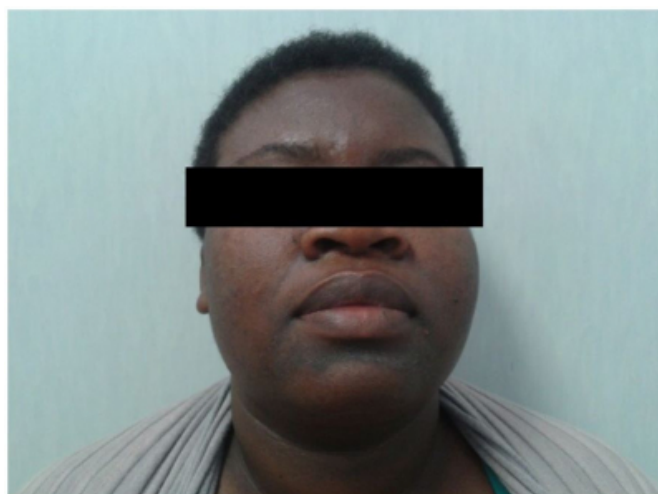A 31 year-old female patient, known hypertensive on treatment (enalapril, hydrochlorothiazide, amlodipine, atenolol and hydralazine) was referred from a district hospital because of a history of recurrent hypoglycemia of five years duration. She complained of recurrent episodes characterized by a sensation of hunger followed by dizziness, sweating and falling. On several occasions she lost consciousness. All these symptoms improved immediately after administration of glucose. She could sense when hypoglycemia crisis was imminent and aborted it, sometimes, by having something to eat. These attacks happened any time but they appeared more frequently in the morning or between meals. Few months prior to admission these episodes had increased to almost every day and even several times per day. She reported an increase in weight of more than 40 kg in the last two years. Two weeks prior to admission a generalized seizure was witnessed at her referring hospital emergency department. A second seizure was observed while already admitted in the Internal Medicine ward. At this time glucose was documented to be 1.5 mmol/L.

She noticed a dark discoloration around the neck, armpits,

back of the chest, fingers, and groins and below the lower lip for a few years (See Picture 1). The patient denied being diabetic or taking any medication except her antihypertensive treatment. She didn't take alcohol or any pill for weight or birth control. Her periods were regular. She denied galactorrhoea or abnormality of vision. She was found to be hypertensive six months ago. Her family history was unremarkable, both parents were alive and healthy as well as her three siblings. She was a single mother of four; currently unemployed.

**Figure 1**

Sublabial acanthosis nigricans.



The physical examination revealed a very obese patient who weighed 142 kg with a height of 165 cm, body mass index 53.26. Blood pressure: 167/91 mm Hg, pulse: 90/min. Her skin showed a dark, leathery, velvety, brownish discoloration that involved the neck right round, axillae, groins, extensor surface of interphalangeal joints and below the lower lip. These skin changes were interpreted as acanthosis nigricans. Cardiorespiratory examination was unremarkable. Abdominal examination was difficult because of the obesity, however there was no organomegally. She had symmetrical mild pitting pretibial oedema.

After a provisional diagnosis of insulinoma, she was admitted for glycemic and insulin levels monitoring and potentially for fasting induction of symptoms. During admission she developed an episode of vomiting, diaphoresis, palpitations and confusion; her glucose was found to be 1.4 mmol/L and an insulin level, taken at the same time, of 22.8 mIU/L (normal 1.9-23). Due to some logistic challenges the specimen for C-peptide level was lost.

The rest of laboratory results can be seen in table 1. An

abdominal ultrasonography showed a mass in the tail of the pancreas of 2.1 cm in diameter, the rest of the organs were normal. A CT scan of the abdomen reported a hypodense mass in the tail of the pancreas of 1.8 X 1.7 cm. A large single left adrenal cyst of 7.6 cm in diameter was also visualized. A 2.6 cm hypodense lesion was noted in the segment 7 of the liver, the possibility of a cyst or metastasis was entertained. The rest of the organs were normal.

**Table 1**

Laboratory results

Test	Normal values	On admission	After operation**
Random Glucose*	< 11,1 mmol/L	1.4 mmol/L	6.2 mmol/L
Insulin*	1.9-23 mIU/L	22.8 mIU/L	10.1 mIU/L
C Peptide	0.8-5.2 µmol/l	Not available	0.7 µmol/l
Cholesterol	< 5 mmol/L	3.0 mmol/L	3.2 mmol/L
Triglyceride	< 1.7 mmol/L	0.84 mmol/L	Not done
TSH	0.5-4.5 mIU/L	3.36 mIU/L	Not done
T4	0.27-4.2 pmol/L	1.4 pmol/L	Not done
Cortisol	185-624 nmol/L	421 nmol/L	Not done

\* Taken at the same time

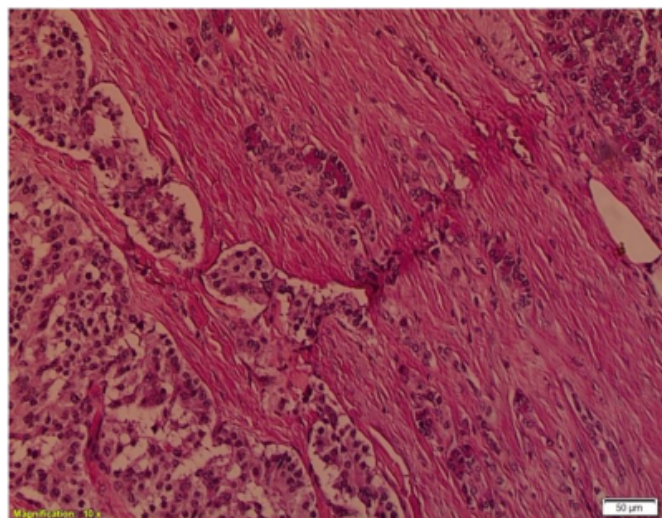
\*\* Three days after operation

A partial pancreatectomy with resection of the tail was performed. No local invasion, enlarged lymph nodes or liver involvement were found. She developed a transient hyperglycemia after the operation; the maximal value recorded was 14 mmol/L, this resolved without treatment in a few days.

The histological report described an encapsulated mass of 2.5 cm in diameter composed of trabeculae of glandular eosinophilic cytoplasm and centrally located round to oval nuclei with distinct nucleolus interpreted as insulinoma (Fig 2 and 3). Fig 2 depicts infiltration of the capsule by the tumoral cells. Mitoses were rare.

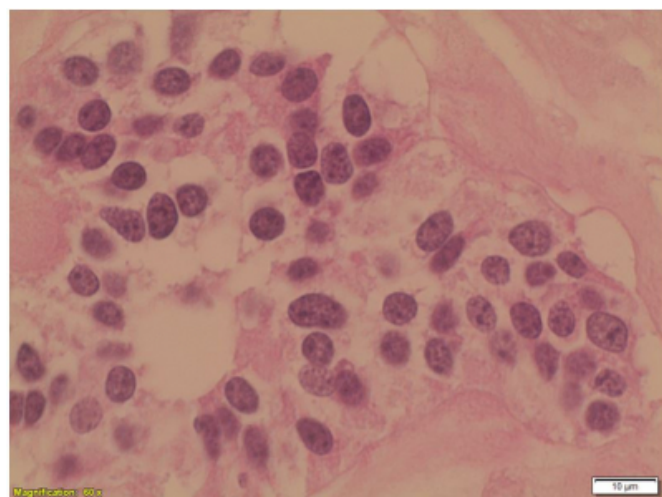
**Figure 2**

Infiltration of the capsule by tumoral cells.



**Figure 3**

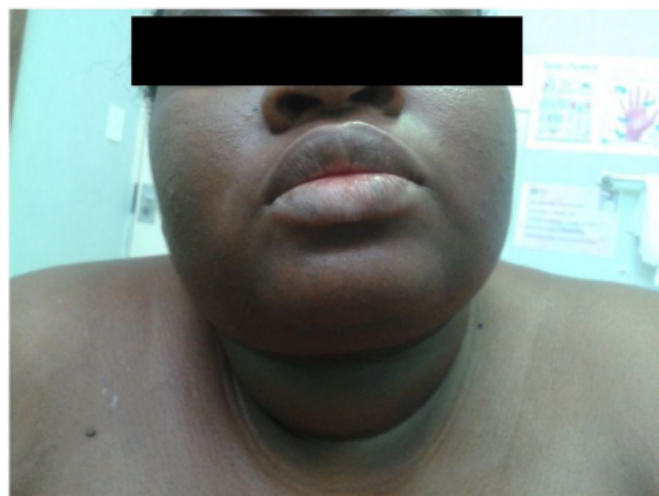Glandular pattern of cuboidal cells.



She was seen again four weeks after the operation, and had developed a left pleural effusion with high level of amylase and a peripancreatic abscess. They were considered direct complications of the surgical procedure. These complications resolved completely after thoracentesis and antibiotics. She had lost 14 kilograms of weight and showed almost total regression of her acanthosis nigricans except for some trophic skin changes and dark discoloration, although lighter than before, they persisted on both axillae and anterior aspect of the neck. The sublabial acanthosis nigricans disappeared entirely (Fig 4).

**Figure 4**

Total disappearance of sublabial acanthosis nigricans.



She remained hypertensive but her blood pressure could be controlled with a simpler combination of antihypertensive drugs. She is currently on hydrochlorothiazide, enalapril and nifedipine.

#### **DISCUSSION:**

The case that we present could be of interest for various reasons. The fact that our patient learned to mitigate, and even abort, hypoglycemic attacks by eating at the time of early warning symptoms of hypoglycemia contributed to both a delayed diagnosis and excessive obesity. We suggest that insulinoma should be considered in the differential diagnosis of the etiology of obesity even if symptoms of hypoglycemia are not present.

As Cruz and Hud have proposed, acanthosis nigricans seen in metabolic syndrome (obesity, hypertension, dyslipidemia and type 2 diabetes mellitus/insulin resistance) is caused by hyperinsulinemia per se and not by whichever mechanism that might be involved in insulin resistance. Our case is supportive of this pathogenic mechanism of acanthosis nigricans because after removing the source of insulin the skin changes regressed in just a few weeks, as have been reported by others. We postulate that probably a genetic predisposition and the time of exposure of hyperinsulinemia on dermal tissue are also needed for acanthosis nigricans to develop, otherwise it is difficult to explain why most patients with insulinoma do not present this skin abnormality.

This case also supports the finding, reported by Sawicki et al, that hyperinsulinemia has no effect in blood pressure since after the normalization of insulin levels she remained

hypertensive, although it has been easier to control due to reduction of her body weight. Certainly this loss of body mass in a short period can be explained by the removal of the source of her hypoglycemia that obliged her to eat excessively.

Most insulinomas show a benign behavior specially if less than 2.5 cm at the time of resection but its real nature cannot be ascertain from the histological appearance. Besides tumour size, the presence of frequent mitosis, metastasis, local or distant, and capsular infiltration can predict a cancerous behavior<sup>1,2</sup>. In our patient metastasis were not found at the time of operation; however, the infiltration of the capsule makes her prognosis uncertain and obliges us to follow her closely in the near future.

### **References**

1. Service FJ, McMahon MM, O'Brien PC, Ballard DJ 1991 Functioning insulinoma: incidence, recurrence, and long-term survival of patients: a 60-year study. *Mayo Clin Proc* 66:711–719
2. Proye C, Malvaux P, Pattou F, et al. Noninvasive imaging of insulinomas and gastrinomas with endoscopic ultrasonography and somatostatin receptor scintigraphy. *Surgery*. Dec 1998;124(6):1134–43
3. Matsuoka LY, Wortsman J, Gavin JR, Goldman J. Spectrum of endocrine abnormalities associated with acanthosis nigricans. *Am J Med* 1987; 83:719–25.
4. Cruz PD, Hud JA. Excess insulin binding to insulinlike growth factor receptors: proposed mechanism for acanthosis nigricans. *J Invest Dermatol* 1992; 98(Suppl. 6):82S–5S.
5. Ghosh S, et al. Clearance of acanthosis nigricans associated with insulinoma following surgical resection. *QJM*. 2008 Nov;101(11):899–900
6. Peifer SLE, Wilson RM, Gawkrödger DJ. Clearance of acanthosis nigricans associated with the HAIR-AN syndrome after partial pancreatectomy: an 11 year follow-up. *Postgrad Med J* 1999; 75:421–22.
7. Sawicki, P. T., et al. Hyperinsulinaemia is not linked with blood pressure elevation in patients with insulinoma. *Diabetologia* 35.7 (1992): 649–652
8. Solcia E, Klöppel G, Sobin L H et al. Histological typing of endocrine tumours, 2nd edn. WHO international histological classification of tumours. Springer, Berlin, 2000
9. DeLellis R A, Lloyd R V, Heitz P U et al. Pathology and genetics: tumours of endocrine organs. WHO classification of tumors. IARC Press, Lyon, 2004

**Author Information**

**Agueda Labrada-Ramos , MD**

Department of Internal Medicine, Polokwane-Mankweng Complex  
Polokwane, South Africa

**Louis Jacque Van Bogaert**

Pathologist, NHLS, Polokwane Hospital  
Polokwane, South Africa

**Adrew Ratsela , FCMSA**

Internal Medicine. Head of the Department of Internal Medicine, Polokwane-Mankweng Complex  
Polokwane, South Africa

**Jose Iganacio Perez-Zaldivar , MD**

Consultant Physician, Department of Internal Medicine, Polokwane-Mankweng Complex  
Polokwane, South Africa