

Tubercular Mastitis Masquerading As Carcinoma: A Case Report

R Godara, V Ahuja, A Dhingra, Sushila, J Sen, R Singh

Citation

R Godara, V Ahuja, A Dhingra, Sushila, J Sen, R Singh. *Tubercular Mastitis Masquerading As Carcinoma: A Case Report*. The Internet Journal of Surgery. 2006 Volume 13 Number 1.

Abstract

Tubercular mastitis is an extremely rare disease even in tuberculosis-endemic countries like India. A 52-year-old multiparous, postmenopausal female presented with a progressively increasing painless lump in the right breast. A mammogram was requested which pointed towards a malignant lump. The lump was subjected to fine needle aspiration cytology which revealed epithelioid cell granulomas, Langhans giant cells and lymphohistiocytic aggregates. Ziehl-Neelsen staining of the aspirate was positive for acid fast bacilli. The patient was put on antituberculous treatment for a period of nine months. The lump gradually disappeared and our patient is doing well at 6 months of follow-up.

INTRODUCTION

Tubercular mastitis is an extremely rare disease even in tuberculosis-endemic countries like India. Its incidence has been variously described as between 0.1 and 3%¹. The first case of tubercular mastitis was described by Sir Astley Cooper in 1829². Diagnosis is difficult because of nonspecific clinical and radiological findings. It should particularly be kept as a differential diagnosis in a young lactating, multiparous female who presents with a hard lump of the breast especially in the setting of a third world country.

CASE REPORT

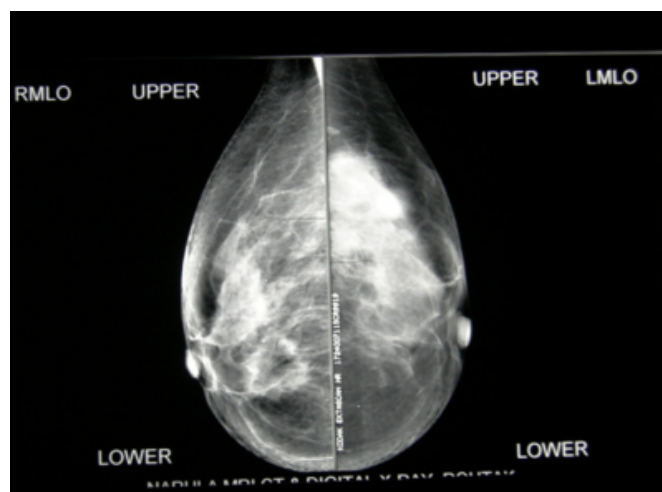
A 52-year-old multiparous, postmenopausal female presented with a progressively increasing painless lump in the right breast. There were no associated constitutional symptoms. On examination, it was a 3x2cm hard, non-tender, mobile lump in the upper outer quadrant. Nipple, areola and overlying skin were normal. There was no axillary or cervical lymphadenopathy. The opposite breast was normal. Chest and abdominal investigations were normal. Chest radiograph, basic hematological and biochemical investigations were within normal limits.

A mammogram was requested which pointed towards a malignant lump (Fig – I). The lump was subjected to fine needle aspiration cytology (FNAC) which revealed epithelioid cell granulomas, Langhans giant cells and lymphohistiocytic aggregates. Ziehl-Neelsen staining of the

aspirate was positive for acid fast bacilli (AFB). The patient was put on antituberculous treatment (ATT) for a period of nine months (HRZE x 2 months + HR x 7 months). The lump gradually disappeared and our patient is doing well at 6 months of follow-up.

Figure 1

Figure 1: Mammogram showing a lesion in the upper outer quadrant



DISCUSSION

Tubercular mastitis is an extremely rare disease of the younger age group. Occasionally, an older patient may present with a lump that masquerades malignancy. The rarity of this disease has been attributed to the relative resistance of the breast tissue towards colonisation and division of

mycobacteria₃. The risk factors considered to be associated with tubercular mastitis are multiparity, lactation, trauma, past history of suppurative mastitis and AIDS_{4,5}. It has been classified into three distinct pathological types – nodular, diffuse and sclerosing₆. The nodular variety is the most common and mimicks fibroadenoma or carcinoma, the diffuse variety presents with caseation and sinus formation, whereas the sclerosing variety shows extensive fibrosis with hard lumps resembling carcinoma.

The portal of entry of tubercular bacteria can be:

- Primary
 - by direct inoculation of bacilli through abrasions over the nipple which is very rare or,
- Secondary
 - by lymphatic (most common route)
 - or hematogenous as in miliary tuberculosis,
 - or contiguous spread from chest wall structures.

The clinical features of tubercular mastitis are sometimes indistinguishable from breast cancer and associated constitutional symptoms may also be absent in the majority. Mammography and ultrasonography do not clinch the diagnosis as features are largely nonspecific. In most cases, FNAC settles the diagnosis by showing characteristic epitheloid cell granulomas, Langhans giant cells and lymphohistiocytic aggregates which is sufficient for diagnosis_{3,8}. Zhiel-Neelsen staining for AFB is positive in only 25% of cases and hence is not mandatory for

diagnosis_{3,8}.

Treatment options include a 9 month regimen of ATT starting with 4 drugs (HRZE x 2 months) and then going on with two drugs (HR x 7 months) in the maintenance phase with or without lumpectomy.

A lack of response to ATT or a diffusely deformed breast with ulceration or sinuses may require simple mastectomy₉. Our patient responded well to medical management alone.

In conclusion, we suggest that tubercular mastitis is a rare but important differential diagnosis for a clinically malignant breast lump, especially in a young patient in third world countries.

CORRESPONDENCE TO

Dr. Rajesh Godara 58/9J, Medical Enclave Rohtak Haryana (India) - 124001. Email : drrajeshgodara@yahoo.co.uk

References

1. Hamit HF, Ragsdale TH. Mammary tuberculosis. J.R. Soc Med 1982; 75: 764.
2. Cooper A. Illustration of the diseases of the breast. Part I. Longmans, Orme, Brown, Green. London: 1829; 73.
3. Gupta D, Rajwanshi A, Gupta SK, Nijhawan R, Saran RK, Singh R. Fine needle aspiration cytology in the diagnosis of tuberculous mastitis. Acta Cytol 1999, 43: 191-4.
4. Gupta PP, Gupta KB, Yadav RK, Agarwal D. Tuberculous mastitis. A review of seven consecutive cases. Ind J Tub 2003; 50: 47-50.
5. Gilbert AI, McGough EC, Farrell JJ. Tuberculosis of the breast. Am J Surg 1962; 103: 424-427.
6. Goksoy E, Duren M, Durgun V et al. Tuberculosis of the breast. Eur J Surg 1995; 161: 471-3.
7. Zandrino F, Monetti F, Candolfo N. Primary tuberculosis of the breast. A case report. Acta Radiol 2000; 41: 61-3.
8. Kakkar S, Kapila K, Singh MK, Verma K. Tuberculosis of the breast. A cytomorphologic study. Acta Cytol 2000; 44: 292-296.
9. Shinde SR, Chandawarkar RY, Deshmukh SP. Tuberculosis of the breast masquerading as carcinoma. A study of 100 patients. World J Surg 1995; 19: 379-81.

Author Information

Rajesh Godara, MS, DNB, MNAMS, FAIS, FICS

Professor, Department of Surgery, Post Graduate Institute of Medical Sciences

Vivek Ahuja, MS

Senior Resident, Department of Surgery, Post Graduate Institute of Medical Sciences

Ashish Dhingra, MS

Senior Resident, Department of Surgery, Post Graduate Institute of Medical Sciences

Sushila, MBBS

Medical Officer, Department of Surgery, Post Graduate Institute of Medical Sciences

Jyotsena Sen, MD

Professor, Department of Radiodiagnosis, Post Graduate Institute of Medical Sciences

Ramender Singh, MD

Senior Resident, Department of Pathology, Post Graduate Institute of Medical Sciences