

The Predictive Value of Pirani Scoring System in the Management of Idiopathic Club Foot by Ponseti Method

M Porecha, D Parmar

Citation

M Porecha, D Parmar. *The Predictive Value of Pirani Scoring System in the Management of Idiopathic Club Foot by Ponseti Method*. The Internet Journal of Orthopedic Surgery. 2008 Volume 11 Number 2.

Abstract

The purpose of this study is to determine the predictive value of Pirani scoring system in the management of idiopathic club foot by Ponseti method. A total number of 50 feet in 30 patients of clubfoot were studied and rated according to Pirani scoring system prospectively at Guru Govind Singh Hospital, M.P. Shah Medical College, Jamnagar during the period of April 2005 to April 2008 by Ponseti method performed by a single surgeon. Tenotomies were performed in 31 of 50 feet (62%). Out of 20 feet with a Pirani score greater than or equal to 5.0 at initial presentation, 90% required tenotomy. The mean number of the casts required was significantly greater (range 6-9 casts) for tenotomy group than that of the non-tenotomy group (range 4-6 casts). Following the removal of the final cast, no significant differences were found between the tenotomy and non tenotomy group with reference to Pirani score system.

INTRODUCTION

Idiopathic clubfoot is a complex deformity that is difficult to correct. The deformity has four components: Forefoot Equinus, Hindfoot Varus, Forefoot Adductus and Midfoot Cavus. The Ponseti serial corrective cast management is an easy, effective and economical method of idiopathic club foot management. The deformity is corrected by weekly serial corrective cast manipulation. The aim of the treatment is to reduce or eliminate all the components of the CTEV deformity to obtain Painless, Plantigrade, Pliable and Cosmetically and Functionally acceptable foot within the minimum time duration and least interruption of the socio-economical life of the parents and child.

There is nearly universal agreement that the initial treatment of the Clubfoot should be non-operative regardless of the severity of the deformity. Ponseti Method¹ which involves serial corrective manipulation, a specific technique of the cast application, and a possible percutaneous Tendo-Achillis tenotomy. The method has been reported to have short-term success rate approaching 90% and long-term results have been equally impressive.¹²

There is no agreed method of grading the severity of the deformity or monitoring the natural history, but there is a reported need of such classification,^{3,4,5} which should be reliable, reproducible, feasible in a clinical setting and predict appropriate treatment.³ Pirani et al⁶ provide a simple

scoring system based on six clinical signs of contracture.

Three clinical signs for Midfoot include curved lateral border, medial creases and position of the lateral part of the talar head. Three clinical signs for Hindfoot include posterior creases, rigid equinus and empty heel.

Each is scored according to the following principle:

0, no abnormality.

0.5, moderate abnormality.

1, severe abnormality.

Thus, each foot can receive a Midfoot score between 0-3 and a hindfoot score between 0-3 and a total score between 0-6.

Scher et al,⁷ compared Pirani et al⁶ and Dimeglio et al⁸ scores with the need for a tenotomy. They concluded for both systems that there is a link between high scoring foot and the need for tenotomy. 85% of the feet with Pirani severity score above 5 required tenotomy, which is significantly more than those that did not required the same.

Parents whose children are starting Ponseti treatment are likely to enquire about the number of the casts to correct the deformity and about the requirement of the tenotomy later on during treatment. The aim of this study is to know whether Pirani severity score will allow the surgeon to give more specific answers of these questions or not during the early stages of Ponseti treatment.

PATIENTS AND METHODS

A total number of 50 feet in 30 patients of clubfoot were studied prospectively at Guru Govind Singh Hospital, M.P.Shah Medical College, Jamnagar during the period of April 2005 to April 2008 by Ponseti method performed by a single surgeon.

Corrective serial casts are applied after doing proper manipulation according to the Ponseti method¹⁸⁹¹⁰. Treatment is started as soon as possible after referral, preferably shortly after birth, as soon as the skin permits, and consists of gentle manipulation of the foot and the serial application of long leg plaster cast without the use of anesthesia, as described by Dr. Ponseti. In all patients, the cavus is corrected first by supinating the forefoot and dorsiflexing the first metatarsal. To correct the varus and adduction, the foot in supination is abducted while counter-pressure is applied with the thumb against the head of the talus which makes this method differ from that of the Kite where the lever fulcrum is at calcaneo-cuboid joint.

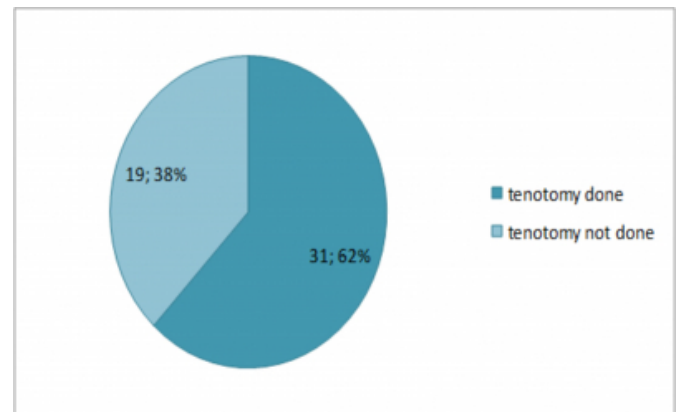
Four to eight long leg casts, changed weekly after proper manipulation of the foot, are usually sufficient to obtain good correction. In the last cast, the foot should be markedly abducted up to 70° without Pronation with 15 of dorsiflexion without any forceful manipulation and a long leg cast is applied for the three weeks.

If dorsiflexion is not obtained up to 15° after achieving the abduction up to 70° and correction of the varus deformity, a simple percutaneous tenotomy of the Achilles tendon is performed. Forty five minutes before the procedure, local anesthetic EMLA cream is applied at tenotomy site. 20 minutes before the procedure Atropine 20ug/Kg with Midazolam 0.5 mg/kg mixed with syrup Paracetamol 10 mg/kg is given orally. Patients are monitored for temperature, pulse, BP, ECG and oxygen saturation till 1 hr of post operative period. So procedure is finished under day case surgery criteria with local anesthetic application and sedation without any anesthesia related complication with better patient compliance. A long leg cast is applied in 70° of abduction and 15° of dorsiflexion immediate after tenotomy under the effect of anesthesia for further 3 weeks to allow for healing of the tendon.

RESULTS

Tenotomies were performed on 31 of 50 feet, comprising 62% of the treated feet. (Figure 1)

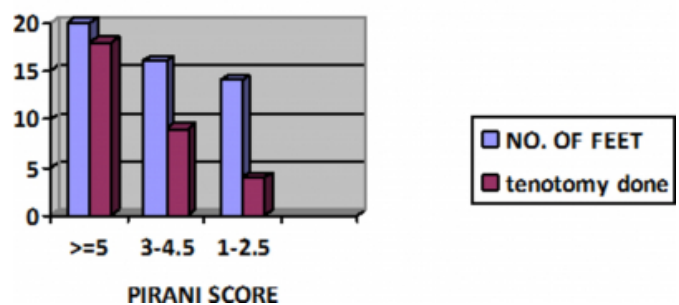
Figure 1



The mean number of the casts required was significantly greater for the group that required a tenotomy, (range 6-9 casts) than the group that did not required a tenotomy, (range 4-6 casts). Out of 20 feet with a Pirani score greater than or equal to 5.0 at initial presentation, 18 feet (90%) required tenotomy. Of the 16 feet with Pirani score between 3.0 and 4.5, 9 feet (56.25%) required a tenotomy and 7 feet (43.75%) did not. Finally, only 4 feet (28.57%) out of 14 feet with initial Pirani severity scores between 1 and 2.5 needed a tenotomy. (Figure 2)

Figure 2

PIRANI SCORE AT INITIAL EVALUATION



Following the removal of the final cast, no significant differences were found between those that did have a tenotomy and those that did not according to the Pirani severity score.

DISCUSSION

Tendo-Achillis tenotomy is an integral part of the Ponseti's technique for the treatment of idiopathic clubfeet. The indication for the tenotomy has been clearly described and is reported to be necessary in approximately 70-80% of the patients.¹²⁸⁹ although the effectiveness of the Ponseti technique has been made clear in multiple publications over

the past 30 years, whether we can predict the need of tenotomy and number of the casts before the initiation of the treatment is not yet been cleared.^{7,11}

This study is an attempt to determine whether the Pirani scoring system can be used to clarify the need of tenotomy and allows an estimation of number of weekly corrective manipulative plaster casts required by Ponseti method or not.

It has been found that a significantly greater percentage of the more severely deformed feet that scored greater than or equal to 5.0 on Pirani severity score required a tenotomy. It is very obvious because equinus is one of the components measured in these scores, so when equinus is severe the score become worse. In tenotomy group, the other components of hindfoot were also significantly worse than that of the non-tenotomy group. Hindfoot components reflect both the severity and the rigidity of the hindfoot contracture which may contribute to the need for tenotomy.

The feet that had tenotomies required significantly more casts than those that did not which also suggest that the likelihood of tenotomy relates to the overall rigidity of the deformity, and not only on the absolute severity. It concludes that the feet ultimately requiring tenotomies were in fact stiffer during the entire casting process in addition to being more severely deformed at the onset of the treatment. This explains that why the mean number of the casts (6-9 casts) required for the tenotomy group were significantly greater than that of the non tenotomy group (4-6 casts).

Another important conclusion is that the feet requiring tenotomies were equally well corrected at the end of the treatment as those that did not required tenotomies. This conclusion clears the fact that the need of tenotomy does not suggest a poor result. Proper application of the Ponseti technique can successfully treat the severe idiopathic clubfeet. At the end of the treatment, feet from both groups had equivalent overall Pirani severity scores, reflecting supple and plantigrade feet. However, the true functional outcome of these two groups cannot be determined until the child has completed the growth, and perhaps not until later in life.

CONCLUSION

Our data suggest that...

1. The need for a tenotomy can be predicted at the onset of the treatment from Pirani severity score system.
2. The rigidity of the foot, and not just the overall severity of the initial equinus, is an important factor in predicting the need of tenotomy.
3. The tenotomy group will generally required more number of the corrective manipulative weekly casts than those of the non-tenotomy group.
4. Finally, when properly indicated, feet requiring tenotomise are as well corrected at the end of the treatment as those not requiring tenotomise, but long term results are still to be awaited.

CORRESPONDENCE TO

Dr. Milind M. Porecha (M.S. Ortho) Assistant professor, Orthopedics department, M.P.Shah Medical College, Guru Govind Singh Hospital, Jamnagar. 361008. Gujarat. India.
E-Mail Address: drmilindmp@yahoo.co.in

References

1. SJ Laaveg & IV Ponseti IV. (1980). Long term results of treatment of congenital club foot. J. Bone Joint Surgery, Am 1980; 62:23-31.
2. Cooper, D.M. and Dietz, F.R. (1995). Treatment of idiopathic clubfoot. A thirty year follow-up note. J. Bone Joint Surg., 77A, 1477-89.
3. Wainwright AM, Auld T, Benson MK, Theologis TN. The classification of congenital talipes equinovarus. J Bone Joint Surg Br 2002;84-B:1020-4
4. Tibrewal SB, Benson MKD, Howard C. Fuller DJ. The Oxford clubfoot programme. J Bone Joint Surg Br 1992;74-B:528-33
5. Bensahel H. Catterall A. Dimeglio A. Practical applications in idiopathic clubfoot. A retrospective multicentric study in EPOS. J Pediatr Orthop 1990;10:186-8
6. Pirani S. Outerbridge HK. Sawatzky B. Stothers K. A reliable method of clinically evaluating a virgin clubfoot evaluation. 21st SICOT Congress 1999.
7. David M. Scher, David S. Feldman, Harold J.P. van Bosse, Debra A. Sala, MS, PT and Wallace B. Lehman, MD. Predicting the need for tenotomy in the Ponseti method for correction of clubfeet. J pediatr orthop 2004;24:349-52.
8. Ponseti IV. Congenital clubfoot: fundamentals of treatment. New York: Oxford University Press. 1996:82-84.
9. Ponseti IV. Treatment of congenital club foot. J Bone Joint Surg Am. 1992;74:448-454.
10. Ponseti IV, Smoley EN. Congenital clubfoot: The results of treatment. J Bone Joint Surg Am. 1963;45:261-275.
11. Dyer P J, Davis N. The role of Pirani scoring system in the management of clubfoot by the Ponseti method.

Author Information

Milind M. Porecha, M.S. Ortho

Assistant professor, Orthopedics department, M.P.Shah Medical College, Guru Govind Singh Hospital

Deepak S. Parmar, M.S. Ortho

Associate professor, Orthopedics department, M.P.Shah Medical College, Guru Govind Singh Hospital