

What is the Diagnostic Accuracy of Hypocellular Fine Needle Aspiration of the Breast in the Context of an Otherwise Negative Triple Screen

R Arrangoiz, S Garand, C Slomski, T Littman, J Osuch

Citation

R Arrangoiz, S Garand, C Slomski, T Littman, J Osuch. *What is the Diagnostic Accuracy of Hypocellular Fine Needle Aspiration of the Breast in the Context of an Otherwise Negative Triple Screen*. The Internet Journal of Oncology. 2008 Volume 6 Number 1.

Abstract

Background: We hypothesize that a hypocellular FNA of a palpable breast mass provides diagnostic accuracy in the context of an otherwise negative triple diagnosis (TD). **Methods:** A database of 1279 patients with palpable lesions was retrospectively reviewed. Lesions <1.5cm in size, clinical breast exam (CBE) not suspicious for cancer, mammography results of BIRADS I and II, and hypocellular FNAB results were extracted from the database and correlated with final pathology on open biopsy. **Results:** There were 276 patients with hypocellular results. Of those, 165 had mammograms of BIRADS I and II. After review of the clinical breast exam data, 83 patients met our study criteria. All were negative for malignancy on open biopsy - a false negative rate of 0% and negative predictive value of 100%. **Conclusion:** A hypocellular FNA, in the context of a benign CBE and breast imaging study is diagnostically accurate, eliminating the need for breast biopsy.

INTRODUCTION

Fine needle aspiration biopsy (FNA) of the breast is a minimally invasive, generally well tolerated surgical office procedure. FNA provides relevant diagnostic information helping decision making for treatment, particularly in the context of a triple screen, which includes mammogram, clinical breast exam (CBE), and FNA. Or does it not? When the CBE is benign, the mammogram results categorized as benign (BIRADS I and II), and a cellular FNA of the breast benign, the range of diagnostic accuracy is 95.5 - 100% [123456].

However, the accuracy of the triple screen in the context of a hypocellular FNA result, remains a source of controversy [7891011]. Common methods of management following hypocellular FNA is to either repeat the FNA or to proceed with excisional biopsy. With few exceptions [17], studies have failed to provide clear criteria for what constitutes a benign CBE or how a hypocellular FNA specimen is defined. The purpose of this study was to determine the diagnostic accuracy of a breast mass using a triple screen which includes a hypocellular FNA result. Precise criteria will be defined for the evaluation of a palpable breast mass using a practical algorithm.

METHODS

The study was conducted at the Michigan State University (MSU) Department of Surgery, a single-site referral center for both physician and self-referred patients attended by 6 general surgeons and 3 surgical oncologists who cared for women with breast complaints. Because the Department of Surgery at MSU is part of a community based medical school, the setting is similar to that of a group practice in a mid-size urban community. The department sees a wide variety of breast complaints, of which approximately 10% result in a diagnosis of malignancy. The majority of the clinic population is drawn from a 30-mile radius around Lansing, Michigan.

After receiving Institutional Review Board approval, we conducted this retrospective study from a previously constructed database of all procedural billing codes indicative of operating room breast procedures performed between January 1, 1996 and December 31, 1999. The procedural codes used included open incisional (19101), open excisional (19120), duct excision (19110), needle localization breast biopsy (19125, or 19126), and partial mastectomy (19160). Of the 2,731 biopsy procedures identified, the medical records could not be located in 49

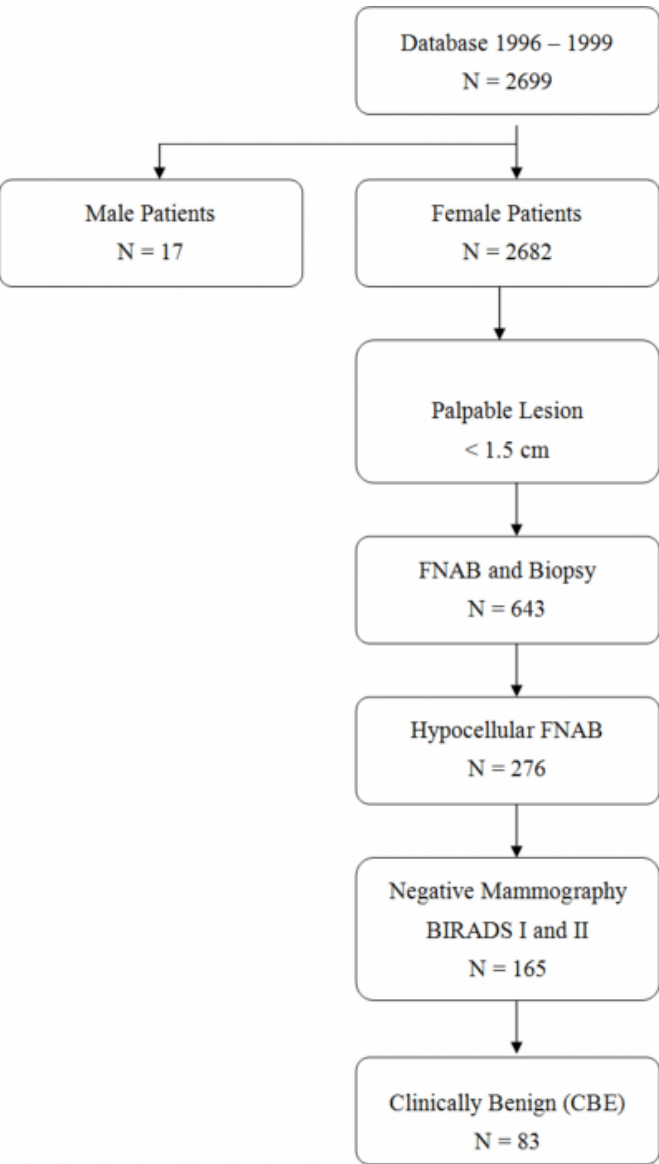
(1.8 %). Data was collected on a large number of epidemiologic, clinical, and diagnostic variables. Epidemiological variables were collected using a standardized breast history form that was completed by each patient at their first visit and updated as necessary. Clinical and diagnostic variables were abstracted from the medical record by a surgical nurse with extensive knowledge of breast cancer evaluation and treatment. To monitor intra-observer reliability, one in every ten charts was re-abstracted by the surgical nurse at least two weeks after the initial abstraction. Inter-observer reliability was assessed by having a breast surgeon abstract a ten percent sample of the re-abstracted charts done by the surgical nurse. Subsequent analysis found error rates of less than two percent for the intra-observer reliability study, and less than five percent for inter-observer reliability.

Data were extracted on all consecutive patients evaluated for a palpable breast mass by triple screen. We excluded men, and women who did not have a mammogram within 6 months of the FNA. The study population was further limited to those patients found to have hypocellular FNA results, a mammogram with breast imaging reporting and data system (BIRADS) category I (negative) or II (benign), as well as a clinically benign CBE. We defined a clinically benign CBE as any examination that included a breast mass of less than or equal to 1.5 cm in size, no irregular characteristics, not fixed to skin or chest wall, no nipple retraction or dimpling, and no skin changes. In addition, the mass had to have a smooth texture, be mobile, be round or oblong in shape, and have a soft or rubbery consistency. Uniformity in fine needle aspiration technique is established within our practice. The uniform FNA procedure is used. The area is prepped with alcohol and the mass fixed between two fingers. Using a 22 gauge needle on a 10cc syringe housed within a syringe holder, one pass is made into the center of the palpable mass. The needle is then moved back and forth several times within the mass while maintaining negative pressure on the syringe. The needle is then repositioned within the mass (without removing it from the original point of entry) at least 3 additional times while repeating the aspiration sequence. The aspirate is then placed on 2 slides and sprayed with fixative. The remainder of the specimen is placed in a cytospin container. Our primary cytopathologist considers an adequate fine needle aspiration specimen as one with at least 6 colonies, each containing at least 10 epithelial cells as described in the Rubenchick criteria [10]. Of the 2699 patients in the database, 17 male

patients were eliminated. Figure one illustrates the study group selection. Of the 2682 remaining patients, 1279 had palpable lesions of < 1.5cm in size. There were 643 who underwent both FNA of the breast and subsequent breast biopsy, 42.9 % of whom had hypocellular FNA results. We then eliminated those individuals with mammogram results of BI-RADS category 3, 4, or 5. Of the remaining 165 patients, 83 were found to have CBE not suspicious for cancer (Fig.1).

Figure 1

Figure 1: Delineation of our patient population. CBE (Clinical Breast Exam) – Clinically Benign: size < 1.5 cm, no irregular characteristics, not fixed to skin/chest wall, no nipple retraction/dimpling, no skin changes. BIRADS: I – negative, II – benign, III – probably benign, IV – suspicious abnormality, V – highly suggestive of malignancy



RESULTS

The mean age of our patient population was 49 years. Of the 83 patients evaluated with a triple screen who had a hypocellular FNA and a breast mass < 1.5 cm, histopathological results demonstrated fibrocystic changes (49.3%), hyperplasia without atypia (29.1%), fibroadenoma (13.3%), papilloma (3.6%), mastitis (2.4%), and fat necrosis (2.4%). All were negative for malignancy yielding a false negative rate of 0% and negative predictive value of 100%.

DISCUSSION

Although breast cancer constitutes the most common malignancy in women in the U.S., breast symptoms frequently represent normal physiological change or benign breast disease. In addition, the vast majority of women will experience some type of breast symptoms during the course of their lifetime. Women with breast complaints must be appropriately evaluated to ensure accurate diagnosis, which becomes more challenging as breast masses become smaller. The triple screen is effective; Morris et al. [12] and Vetto et al. [13] reported a sensitivity of 96% and specificity of 100% for FNA of the breast in the context of a triple screen. There are several methods for obtaining tissue samples from a palpable breast mass. Appropriately obtaining an adequate fine needle aspirate of a palpable lesion is a skill not readily mastered by all, nor is the confident interpretation of a cytology specimen a universally mastered or even available procedure. Furthermore, what constitutes a “hypocellular” result is left to the interpretation of the cytopathologist [781011]. Some authors argue that the number of cells from an FNA reflects the degree of epithelial proliferation in that sample and not specimen adequacy [1114]. The results from this study support that contention. Why then, advocate the use of FNA? Fine needle aspiration eliminates the risk of anesthesia, can be done on first office visit, is minimally invasive, and generally well tolerated without major risk or morbidity. Malignant cells on FNA eliminate the need for open or needle core biopsy, allowing the practitioner to proceed with definitive treatment. A cellular FNA with a benign cytology provides both the patient and practitioner the peace of mind that the lesion is not of imminent concern. The value of a hypocellular FNA is controversial. In the context of the triple screen, our results show that a hypocellular FNA can predict whether the lesion is benign.

The current surgical literature does not define a universally accepted interval for follow-up. Osuch, et al. [1] suggests follow up visits every three months, and suggests that all malignancies should be diagnosed within six months of presentation. Our results favor routine follow-up for patients with a small breast mass, a cytologically negative hypocellular FNA, and a normal mammogram (Fig. 2)

Figure 2

Figure 2

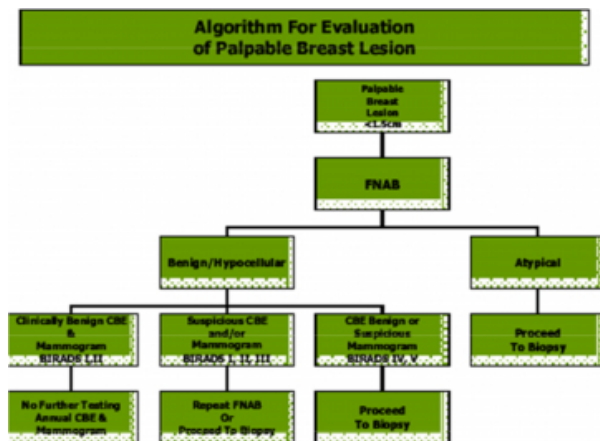


Figure 2: Algorithm

CBE (Clinical Breast Exam) – Clinically Benign: Size <1.5cm, no irregular characteristics, not fixed to skin or chest wall, no nipple retraction/dimpling, no skin changes.
 BIRADS: I – negative, II – benign, III – probably benign, IV – suspicious abnormality, V – highly suggestive of malignancy.

Strengths of this study include the inclusion of consecutive patients who underwent triple screen, uniformity of CBE reported by a single surgical practice with multiple surgeons, and uniformity of cytological interpretation with standard FNA technique, and use of the “gold standard” of open biopsy in each patient. In addition, because of the nature of the surgical practice at MSU, these study results should be generalizable to most surgical practices with skilled cytopathologists. Although the retrospective nature of the study is considered a weakness, the consecutive evaluation of patients and the use of a standardized database help guard against unforeseen biases.

CORRESPONDENCE TO

Rodrigo Arrangoiz, M.D. Michigan State University M.S.U.
 Department of Surgery 1200 E. Michigan Avenue, Suite 655
 Lansing, MI 48912 Tel: 517-267-2487. Fax: 517-267-2488.
 E-Mail: rodrigo.arrangoiz@ht.msu.edu

References

1. Osuch JR, Reeves MJ, Pathak DR, Kinchelow T. BREASTAID Clinical Results From Early Development of a Clinical Decision Rule for Palpable Solid Breast Masses. *Ann Surg* 2003, 238(5):728-37.
2. Vetto JT, Pommier RF, Shih RL, Campagna J, Robbins D, Schmidt WA. Breast fine-needle aspirates with scant cellularity are clinically useful. *Am J Surg* 2005, 189:621-6.
3. Steinberg JL, Trudeau ME, Ryder DE. Combined fine-needle aspiration, physical examination and mammography in the diagnosis of palpable breast masses: their relation to outcome for women with primary breast cancer. *Can J Surg* 1996, 39:302-311.
4. Morris A, Pommier RF, Schmidt W, Shih R, Alexander P, Vetto JT. Accurate Evaluation of Palpable Breast Masses by the Triple Test Score. *Archives of Surgery* 1998, 133(9):930-34.
5. Kaufman Z, Shpitz B, Shapiro M, Rona R, Lew S, Dinbar A. Triple approach in the diagnosis of dominant breast masses: combined physical examination, mammography, and fine-needle aspiration. *J Surg Oncol* 1994, 56(4):254-7.
6. Hermansen C, Poulsen HS, Jensen J, Langfeldt B, Steenskov V, Frederiksen P. Diagnostic reliability of combined physician examination, mammography, and fine-needle puncture (“Triple Test”) in breast tumors: a prospective study. *Cancer* 1987, 60:1866-71.
7. Boerner S and Sneige N. Specimen adequacy and false-negative diagnosis rate in fine-needle aspirates of palpable breast masses. *Cancer* 1998, 84(6):319-23.
8. Eckert R and Howell LP. Number, size, and composition of cell clusters as related to breast FNA adequacy. *Diagn Cytopathol* 1999, 21(2):105-11.
9. Salami N, Hirschowitz SL, Nieberg RK, Apple SK. Triple Test Approach to Inadequate Fine Needle Aspiration of Palpable Breast Lesions. *Acta Cytologica* 1999, 43(3):339-43.
10. Rubenchik I, Sneige N, Edeiken B. In search of specimen adequacy in fine-needle aspirates of nonpalpable breast lesions. *Am J Clin Pathol* 1997, 108:1-3.
11. Abele JS, Wagner LT, Miller TR. Fine-Needle Aspiration of the Breast: Cell Counts as an Illusion of Adequacy. *Cancer Cyto* 1998, 84(6):319-23.
12. Morris A, Rodney F, Waldman A. Accurate evaluation of palpable breast masses by triple test score. *Arch Surg* 1998;133:930-4.
13. Vetto J, Rodney R, Waldman, Polly RN. Use of the triple test for palpable breast lesions yields high diagnostic accuracy and cost saving. *Am J Surg* 1995;169:519-20.
14. Saxe A, Philips E, Orfanou P, Husain M. Role of sample accuracy in fine needle aspiration biopsy of palpable breast lesions. *Am J Surg* 2001, 182:369-71.

Author Information

Rodrigo Arrangoiz, MD

Susan Garand, DO

Carol Slomski, MD

Travis Littman, MD

Janet R. Osuch, MD