

Inversion 16 Leukemia Possible Associated With Familial Sinus Bradycardia And Bridging Of Ribs

I Yavasoglu, G Kadikoylu, Z Bolaman

Citation

I Yavasoglu, G Kadikoylu, Z Bolaman. *Inversion 16 Leukemia Possible Associated With Familial Sinus Bradycardia And Bridging Of Ribs*. The Internet Journal of Hematology. 2008 Volume 5 Number 2.

Abstract

Tumor predisposition syndromes might account for a larger percentage of childhood cancers than currently estimated. A 61 years old man admitted for frequent epistaxis attacks in the last 15 days. The patient's heart rate was 40 beats/min. Sinus bradycardia rhythm was seen in the electrocardiography (ECG) examination and non-specific T waves were present on D3, AVF derivations of ECG. Chest radiography showed only bridging between anterior portion of second and third ribs. The diagnosis of acute myeloblastic leukemia (AML) with recurrent genetic abnormalities- inv 16- (according to WHO classification) was confirmed by bone marrow biopsy, flow cytometry and genetic evaluation. Constitutional genetic defects should be important for leukemogenic potential.

INTRODUCTION

Tumor predisposition syndromes might account for a larger percentage of childhood cancers than currently estimated. Several studies have shown a relationship between childhood cancer and the presence of major and minor anomalies in children (1). Here, we report sinus bradycardia and bridging of ribs possible associated with inversion 16 leukemia, to our knowledge, that has not been reported before.

CASE REPORT

A 61 years old man admitted for frequent epistaxis attacks in the last 15 days. Physical examination showed petechias at low extremities and asymptomatic bradycardia. The patient's heart rate was 40 beats/min. Chest radiography showed only bridging between anterior portion of second and third ribs (figure, arrow). Sinus bradycardia rhythm was seen in the electrocardiography (ECG) examination and non-specific T waves were present on D3, AVF derivations of ECG (figure legend).

Figure 1

Figure

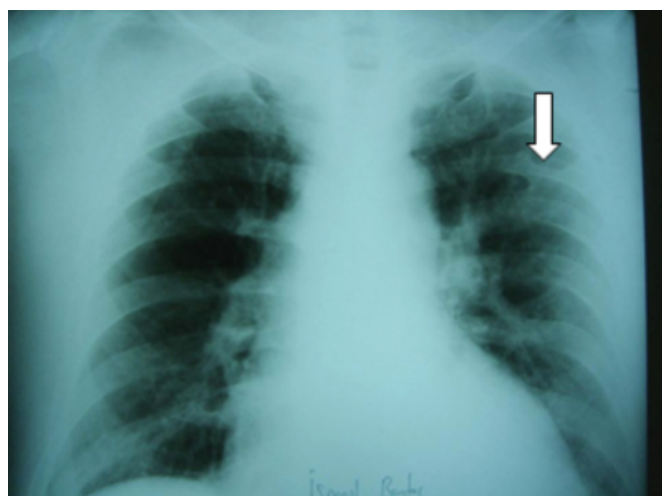
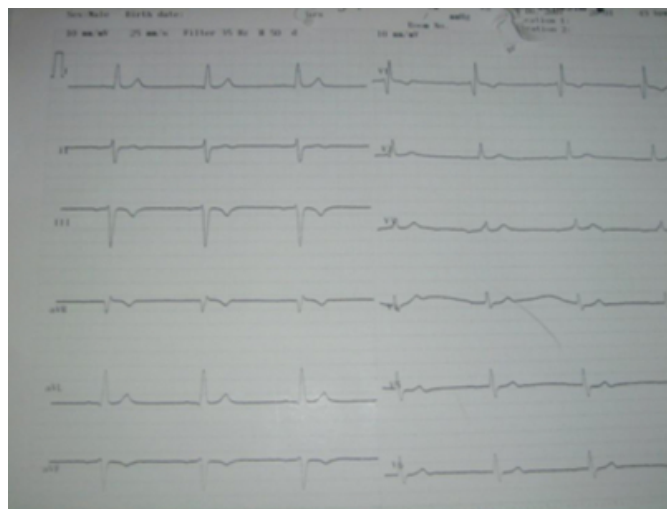

Figure 2

Figure legend



Hemoglobin was 8 gr/dl, white blood cell was 2900/mm³, platelet count was 36000/mm³. Bone marrow consisted 42% blasts. Sudan black dye was positive. Blasts did not include auer body. Flow cytometry showed CD 13, 33, 34 positivity. He was diagnosed as acute myeloblastic leukemia. G banding was held for cytogenetic evaluation. He had inversion (inv) 16 (p13q22). Induction chemotherapy with idarubicine 12 mg/m² IV over 30 minutes on days 1-3 and cytosine arabinoside 100 mg /m² IV over 30 minutes every 12 hours on days 1-7 was initiated. We found a three-generation family with 5 patients (our patients, three daughter- one sudden death, other two had permanent pacing-also girls grandchild) affected by bradycardia. Patient's girls did not have inv 16 with G banding. Sinus bradycardia have in Patient's history. Cardiac enzyme levels (LDH, CPK, AST, Troponin T) and thyroid function test were normal. Echocardiography (ECHO) was normal. Medications such as digitalis, calcium channel and β -blockers, and antihypertensive drugs were not used. Chest radiography and ECHO of others were normal. The diagnosis of acute myeloblastic leukemia (AML) with recurrent genetic abnormalities- inv 16- (according to WHO classification) was confirmed by bone marrow biopsy, flow cytometry and genetic evaluation.

DISCUSSION

Inv(16) (p13q22) is generally associated with AML- recurrent genetic abnormalities (WHO classification), which is characterized by the presence of myelomonocytic blasts and atypical eosinophils. Bone marrow eosinophils of our patient were not increased.

This chromosomal rearrangement results in the fusion of core binding factor- β (CBFB) and myosin heavy chain (MYH11) genes. Mouse models indicate that the fusion gene, CBFB-MYH11, inhibits differentiation of hematopoietic cells. Although expression of CBFB-MYH11 is not sufficient for leukemogenesis, a combination of CBFB-MYH11 and additional mutations can lead specifically to the development of myeloid leukemia (2). Patterning of the axial skeleton in vertebrates is mainly determined by Hox genes. Hox genes also play a role in normal and malignant hematopoietic processes. The mixed-lineage leukemia (MLL) gene, a structural and functional homologue of Trithorax, a Drosophila homeotic regulator, is involved in the maintenance of expression of Hox genes during embryogenesis, this way being an important factor in anterior-posterior patterning (3). Within the hematopoietic system, Hox genes are expressed in stem cells and immature progenitor cells, but are down regulated in differentiated myeloid cells. MLL-gene translocations are involved in the majority of infantile leukemia (4). Mice with mutations of Trx-G and Pc-G genes, involved in the maintenance of the expression of Hox genes, show both vertebral anomalies (including cervical ribs) and leukemia or lymphoma (3,4).

Bradycardia is conventionally defined as a heart rate lower than 60 beats per minute. The fact that sinus bradycardia can be inherited indicates that it can have a genetic basis. The cyclic nucleotide-gated (hHCN4) gene is located on chromosome 15 (15q24-25); the genes coding for other channels contributing to the electrical activity of sinoatrial-node cells, including the L- and T-type calcium channels and delayed-rectifying potassium channels, are all located on different chromosomes (5). Inversion in chromosome 15 was not with G banding at our patient. To our knowledge, sinus bradycardia due to located on chromosome 16 anomaly previously have not reported in the literature previously.

We did not make genetic analysis for hox genes (for bridging ribs) and sinus bradycardia. Merks and colleagues demonstrated a significantly higher prevalence of cervical rib anomalies in a large cohort of childhood cancer patients compared to controls. The difference was found only in patients with acute lymphoblastic leukemia, astrocytoma, and germ cell tumor, suggesting that cervical rib anomalies are tumor specific (1).

In conclusion, constitutional genetic defects should be important for leukemogenic potential.

CORRESPONDENCE TO

Irfan Yavasoglu, Adnan Menderes University Medical
Faculty, Division of Hematology, 09100 Aydin, Turkey. e-
mail: dr_yavas@yahoo.com Telephone: +90-256-2120020
Fax: +90-256-2146495

References

1. Merks JH, Smets AM, Van Rijn RR, Kobes J, Caron HN, Maas M, Hennekam RC. Prevalence of rib anomalies in normal Caucasian children and childhood cancer patients.

Eur J Med Genet 2005; 48:113-29.

2. Kundu M, Liu MM. Function of the inv(16) fusion gene CBFB-MYH11. Curr Opin Hematol 2001; 8:201-5.

3. Yu BD, Hanson RD, Hess JL, Horning SE, Korsmeyer SJ. MLL, a mammalian trithorax-group gene, functions as a transcriptional maintenance factor in morphogenesis, Proc Natl Acad Sci 1998; 95:10632-36.

4. Ayton PM, Cleary ML. Molecular mechanisms of leukemogenesis mediated by MLL fusion proteins, Oncogene 2001; 20:5695-07.

5. Roden DM, Balser JR, George AL JR, Anderson ME. Cardiac ion channels. Annu Rev Physiol 2002; 64:431-75

Author Information

Irfan Yavasoglu

Assistant Professor, Internist, Fellow in Hematology, Division of Hematology, Adnan Menderes University Medical Faculty

Gurhan Kadikoylu

Associate Professor, Internist, Hematologist, Division of Hematology, Adnan Menderes University Medical Faculty

Zahit Bolaman

Professor, Internist, Hematologist, Division of Hematology, Adnan Menderes University Medical Faculty