

# Metatarsal Lengthening By Callus Distraction For Brachymetatarsia: Case Report and Review of the Literature

R Rose

---

## Citation

R Rose. *Metatarsal Lengthening By Callus Distraction For Brachymetatarsia: Case Report and Review of the Literature*. The Internet Journal of Third World Medicine. 2003 Volume 1 Number 2.

## Abstract

Congenital metatarsal shortening (brachymetatarsia) causes minor disability in daily life. However, patients are likely to seek medical care complaining mainly of cosmetic problems when they reach adolescence or adult life. Callus distraction is a unique method for elongating a long bone. As with any lengthening procedure by callotaxis there are complications and these can be avoided or minimized by careful monitoring of progress throughout distraction and consolidation. This is the first reported case of callus distraction for brachymetatarsia from the English speaking Caribbean. The technique and complications are discussed.

## INTRODUCTION

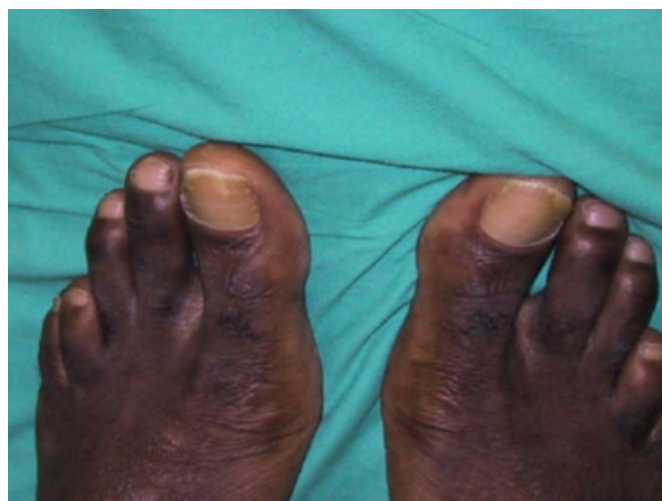Brachymetatarsia most commonly involves the fourth ray with early closure of the distal growth plate and may be unilateral or bilateral (1,2,3). It is normally idiopathic, but can be a marker of pseudohypoparathyroidism or Turner's syndrome (4). It is usually symptomless, but may cause painful callosities in the adjacent metatarsals (4,5,6). This results from mechanical insufficiency of the short metatarsal, and the associated axial deviation or claw-toe deformity, can cause problems on walking.

## CASE REPORT

A 29 year old male presented, at the University Hospital of the West Indies, in 2002 with bilateral symmetric deformities of the fourth toes. He had no functional disability, but was very concerned about the cosmetic appearance of his feet (Fig I). There was no hereditary, infectious or traumatic history. Plain radiographs showed 18mm congenital shortening of each fourth metatarsal (Fig II).

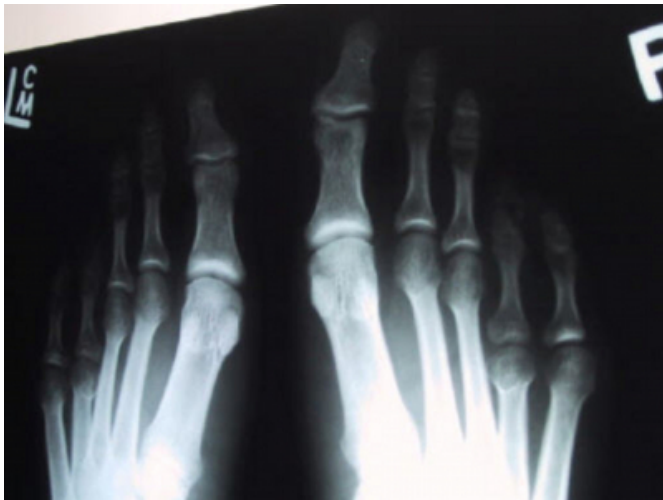
## Figure 1

Figure 1: Pre-operative photograph both feet



**Figure 2**

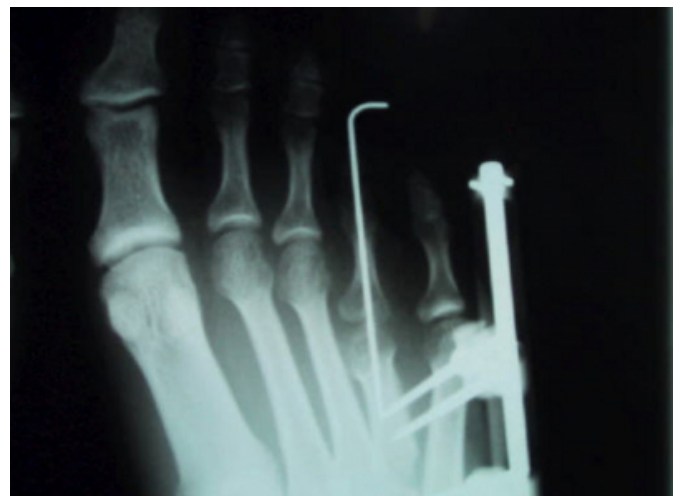Figure 2: Pre-operative radiograph both feet



At surgery a 4cm straight incision was made on the dorsal side of the fourth metatarsal. The periosteum was incised longitudinally and carefully elevated from the bone at its proximal metaphyseal-diaphyseal junction. The external fixator (Orthofix M-100) was used as guide for placement of the screws. After drill holes were made with a 1.5mm Kirschner wire (K-wire), four self-tapping screws with 3mm shank and 3mm tapered threads were inserted. All the screws were inserted in line with the long axis of the metatarsal. A transverse osteotomy between the second and third screws was performed using a thin osteotome. A Z-lengthening of the extensor digitorum longus tendon to the fourth toe was carried out prior to closure of the periosteum and application of the external fixator. K-wires were inserted across the metatarsophalangeal (MTP) joints of the fourth metatarsals to prevent subluxation of the MTP joints as well as medial and plantar angulation of the metatarsals during distraction. On the right foot, the fourth MTP joint was exposed for accurate placement of the K-wire across the joint. On the left foot, a K-wire was inserted without visualization of the MTP joint. Distraction was started one week after surgery at a rate of 0.25mm twice per day (Fig III). The rate of distraction was increased to 0.25mm three times per day 16 days after the commencement of distraction. Radiographs were taken every week.

**Figure 3**

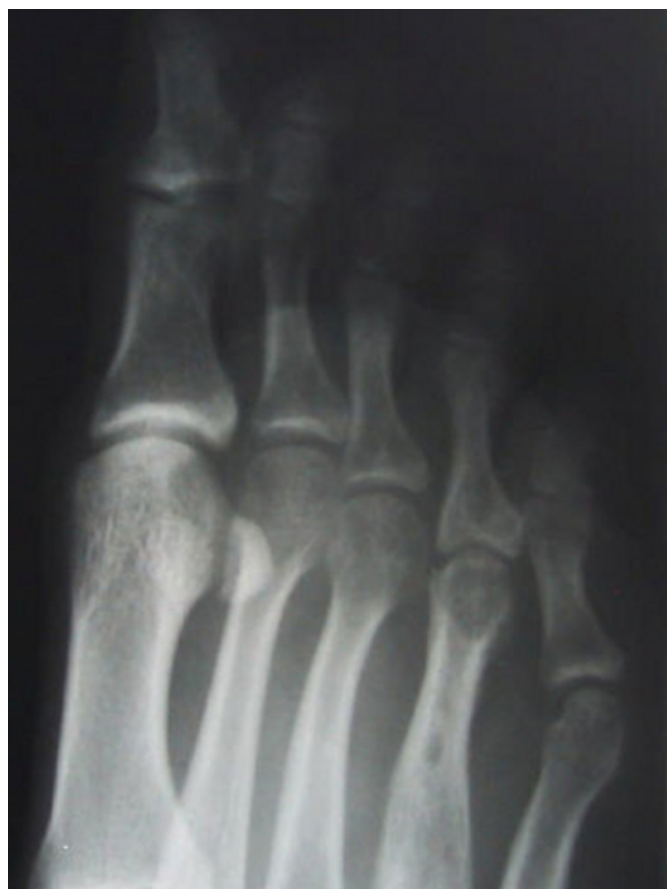Figure 3: Radiograph right foot showing distraction site, K-wire and external fixator in situ



Post-operative radiographs obtained during the first week of distraction revealed the K-wire in the left foot was not accurately placed across the MTP joint. The K-wire was removed. Partial weight bearing with crutches was allowed immediately after surgery. Broad spectrum antibiotics were required for pin tract infection. Distraction of the right fourth metatarsal was stopped after the metatarsal length of 18mm was achieved and this was after thirty six days. The external fixator was left in place for another 59 days until complete bone union had occurred. The amount of lengthening was approximately 32.8% of the original length and the Healing Index 94:1.8cm (Fig IV). The Healing Index is defined as the ratio between the healing time in days and the lengthening achieved in centimeters. The range of motion of the MTP joint was slightly decreased at follow-up but the patient was satisfied with the results. He returned to wearing regular shoes 4 weeks following the removal of the fixator and was pain free in the right foot (Fig V).

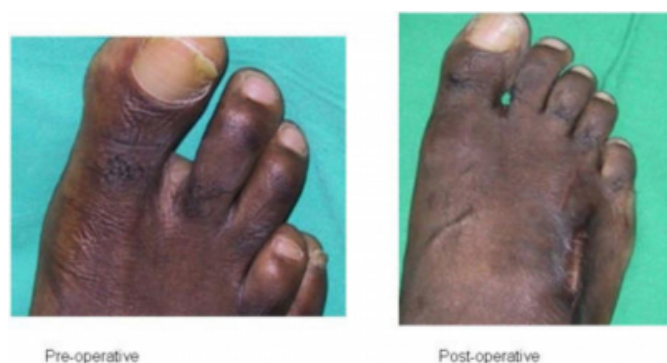**Figure 4**

Figure 4: Radiograph of completely healed and fully lengthened fourth metatarsal right foot



**Figure 5**

Figure 5: Photographs of right foot Pre and Post operative for comparison



Distraction of the left fourth metatarsal was discontinued after twenty days due to medial and plantar angulation of the metatarsal. The desired length was also not achieved. The patient declined further surgery until the right foot was fully functional.

## DISCUSSION

In the past a number of techniques for metatarsal lengthening were described. These included osteotomy followed by gradual distraction and bone graft (<sup>7,8</sup>), and osteotomy, gradual distraction without bone grafting (<sup>6,9,10</sup>). The use of an external fixator for gradual metatarsal elongation was first reported by Skirving and Newman (<sup>9</sup>). Since then, there have been several reports concerning metatarsal lengthening by callus distraction for brachymetatarsia (<sup>4,5,6,9</sup>).

Callotaxis using the minifixator has been shown to be safer and less traumatic than techniques which involve bone grafting at the end of the distraction period (<sup>4,5,6,9,10</sup>). As with any lengthening procedure there are complications, and these involve pin tract infections, subluxation of the MTP joint, flexion deformity of the fourth digit, plantar and medial angulation of the metatarsal and limitation of the range of motion of the MTP joint (<sup>4,5,10</sup>). A review of the literature shows only one paper which discusses the pitfalls and complications of metatarsal lengthening (<sup>11</sup>). The principal problems in metatarsal lengthening by callus distraction are angulation of the metatarsals, subluxation or axial deviation of the MTP joint and joint stiffness (<sup>4,6,10,11</sup>).

Superficial pin tract infection is an accepted complication of callus distraction and complete resolution usually occurs with local pin care and oral antibiotics administration (<sup>12</sup>). Because of the high incidence of pin tract inflammation, some authors do not regard it as a complication, but as a natural sequela of lengthening by callus distraction (<sup>13,14</sup>).

Several authors have reported that the range of movement of the MTP joint decreased in all cases after surgery, and the normal range was never achieved at follow-up. However none of the patients complained of the restriction in range of motion (<sup>4,6,10,11</sup>). Slight restriction in the range of motion of the right fourth MTP joint was noted at follow-up in the case presented. In many studies it was observed that the degree of MTP joint stiffness was related to the amount of lengthening. Takakura et al (<sup>15</sup>) reported the results of lengthening the great toe and emphasized that in order to prevent joint stiffness the amount of lengthening should not exceed 40% of the original length of the metatarsal. In the study by Masada et al (<sup>11</sup>), two cases in which the lengthening exceeded 40% of the preoperative length showed a large decrease in range of motion of the MTP joint.

There are several reports describing the possibility of metatarsal angulation and axial deviation of the joint. Excessive plantar deviation can lead to pain in the lengthened metatarsal, while dorsal deviation may fail to relieve pain in the adjacent segments. Lateral or medial deviation may cause painful contact between the metatarsal heads, with the development of bursitis or degenerative osteochondritis. It is also essential to maintain MTP and interphalangeal alignment to prevent iatrogenic subluxation and axial deviation (<sub>4</sub>).

Several authors recommended K-wire fixation of the MTP joint during distraction to prevent deformity of the joint (<sub>4,11,15</sub>). In addition, soft tissue release was recommended by other authors to prevent subluxation or axial deviation of the joint. Wakisaka et al (<sub>6</sub>) and Ferrández et al (<sub>16</sub>) reported that release of the extensor brevis tendon and Z-lengthening of the extensor digitorum longus tendon had been performed in some of their cases. In contrast, Saxby and Nunley (<sub>10</sub>) reported good results without soft tissue release.

The occurrence of angulation of the metatarsal increased in proportion to the amount of lengthening. Masada et al (<sub>11</sub>) reported two cases of metatarsal angulation when the amount of lengthening exceeded 40% of the original length, while Magnan et al (<sub>4</sub>) reported that the amount of lengthening should be limited to 50% of the preoperative length.

In the case presented, Z-lengthening of the extensor digitorum longus tendons was performed along with K-wire fixation of the MTP joint of the right fourth toe. As was reported in the case history, the K-wire was removed from the left fourth MTP joint when it was discovered on plain radiographs that the wire had not transfixed the MTP joint. Distraction of the left fourth metatarsal resulted in plantar angulation of the metatarsal and mild prominence of the metatarsal head. The angular deformity was most likely due to lack of fixation of the MTP joint.

As for any lengthening procedure, callotaxis of the metatarsal requires careful monitoring of the progress

throughout distraction and consolidation. Restoration of the correct metatarsal proportions requires exact control of the amount of distraction and scrupulous attention to local factors to prevent complications. The temporary use of a K-wire with or without Z-lengthening during distraction is indicated even for minor degrees of lengthening. It is also recommended that the amount of lengthening should not exceed 40% of the original length of the metatarsal.

## References

1. Mori F, Molfetta L, Squra A, Patella V. Congenital shortness of the 4th metatarsal. *Chir Piede* 1983; 7: 37-44
2. McGlamry ED, Cooper CT. Brachymetatarsia: a surgical treatment. *J Am Podiatry Assoc* 1969; 59: 259-64
3. McGlamry ED, Fenton CF III. Brachymetatarsia: a case report. *J Am Podiatry Assoc* 1983; 73: 75-8
4. Magnan B, Bragantini A, Regis D, Bartolozzi P. Metatarsal lengthening by callotaxis during the growth phase. *J Bone Joint Surg Br* 1995; 77: 602-607
5. Levine SE, Davidson RS, Dormans JP, Drummond DS. Distraction osteogenesis for congenitally short lesser metatarsals. *Foot Ankle Int* 1995; 16: 196-200
6. Wakisaka T, Yasui N, Kojimoto H, Takasu M, Shimomura Y. A case of short metatarsal bones lengthened by callus distraction. *Acta Orthop Scand* 1988; 59: 194-6
7. Walter JH, Pressman MM. External fixation in the treatment of metatarsal non unions. *J Am Podiatry Assoc* 1981; 71: 297-301
8. Urbaniak JR, Richardson WJ. Diaphyseal lengthening for shortness of the toe. *Foot and Ankle* 1985; 5: 251-6
9. Skirving AP, Newman JH. Elongation of the first metatarsal. *J Pediatr Orthop* 1983; 3: 508-10
10. Saxby T, Nunley JA. Metatarsal lengthening by distraction osteogenesis: a report of two cases. *Foot and Ankle* 1992; 13: 536-9
11. Masada K, Fujita S, Fujii T, Ohno H. Complications following metatarsal lengthening by callus distraction for brachymetatarsia. *J Pediatr Orthop* 1989; 19: 394-397
12. Aronson J. Experimental and clinical experience with distraction osteogenesis. *Cleft Palate Cranioface J* 1994; 31: 473-81
13. Cierny G 3rd, Zorn KE. Segmental tibial defects. Comparing conventional and Ilizarov methodologies. *Clin Orthop* 1994; 301: 118-23
14. Paley D, Catagni MA, Argnani F, Villa A, Benedetti GB, Cattaneo R. Ilizarov treatment of tibial non unions with bone loss. *Clin Orthop* 1989; 241: 146-65
15. Takakura Y, Tanaka Y, Fujii T, Tamai S. Lengthening of the short great toes by callus distraction. *J Bone Joint Surg Br* 1997; 79: 955-8
16. Ferrández L, Yubero J, Usabiaga J, Ramos L. Congenital brachymetatarsia: three cases. *Foot Ankle* 1993; 14:529-33

**Author Information**

**Rec Rose**

Department of Surgery, Radiology, Anaesthesia and Intensive Care, Division of Orthopaedics, The University of the West Indies