

Skin And Umbilical Metastasis In Carcinoma Ovary - A Rare Presentation

P Shukla, D Gupta, J verma, S Bisht, M Pant, N Husain, D Mishra

Citation

P Shukla, D Gupta, J verma, S Bisht, M Pant, N Husain, D Mishra. *Skin And Umbilical Metastasis In Carcinoma Ovary - A Rare Presentation*. The Internet Journal of Oncology. 2008 Volume 6 Number 2.

Abstract

We report the case of ovarian carcinoma with skin and umbilical metastasis in a thirty year old female. The CT scan abdomen showed right ovarian mass with anterior abdominal wall metastasis . The CT guided FNAC from the ovarian mass showed adenocarcinoma. FNAC from umbilical and skin metastasis also showed adenocarcinoma. Because of the unresectability of the mass, the patient was put on taxol based chemotherapy which she took for two cycles and then expired.

INTRODUCTION

Ovarian cancer, a disease of “older women” occurs primarily in postmenopausal women, with a peak incidence from 50 through 70 years of age. The disease is relatively uncommon before 40 years of age. Metastasis occurs primarily through lymphatic and hematogenous pathways. A metastatic malignancy of the umbilicus commonly termed “Sister Mary Joseph nodule” is a rare occurrence. Metastasis to skin is still rarer, the reported incidence being 3%.^[1]

We report a cytologically proven case of adenocarcinoma ovary in a young female with skin and umbilical metastasis .

CASE REPORT

A thirty year old female presented to our OPD in October 2007 with the history of vague gastrointestinal complaints of dyspepsia, nausea and constipation for the past three months and a progressively increasing abdominal swelling for the past one month. She had developed a nodule in the epigastric area ten days back and another nodule in periumbilical area a week back.

On examination, the abdomen was distended and tense. Fluid thrill could be elicited. Bilateral inguinal lymphadenopathy was present. There was presence of umbilical hernia along with a nodule present over it discharging a serosanguinous fluid.

An ulcerated nodule was presented in the epigastric area which was also discharging a serosanguinous fluid.(fig1)

Figure 1

Fig1 photograph of patient showing skin and umbilical metastasis

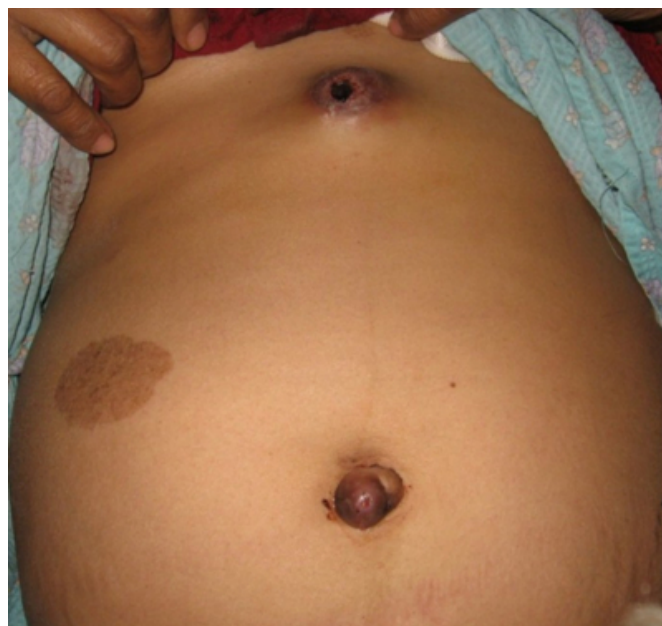

Figure 2

Fig 2.CT scan abdomen showing adnexal mass and skin metastasis.

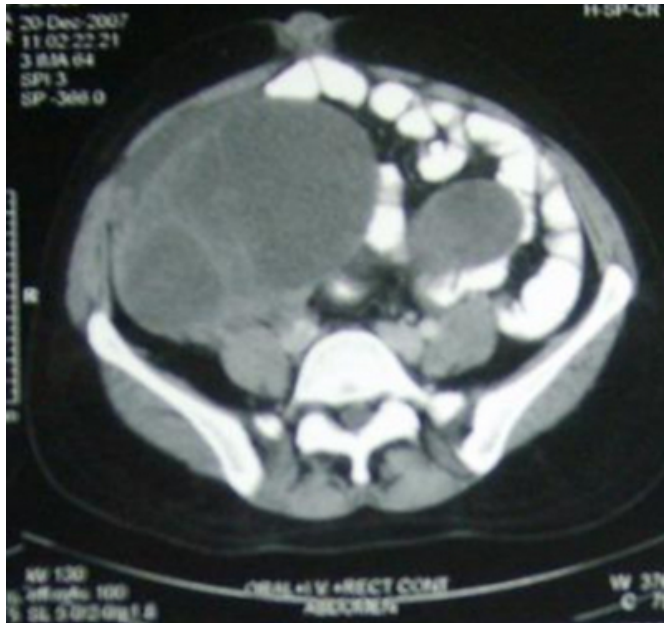

Figure 3

Fig 3 FNAC from ovarian mass showing marked pleomorphism and prominent nucleolic

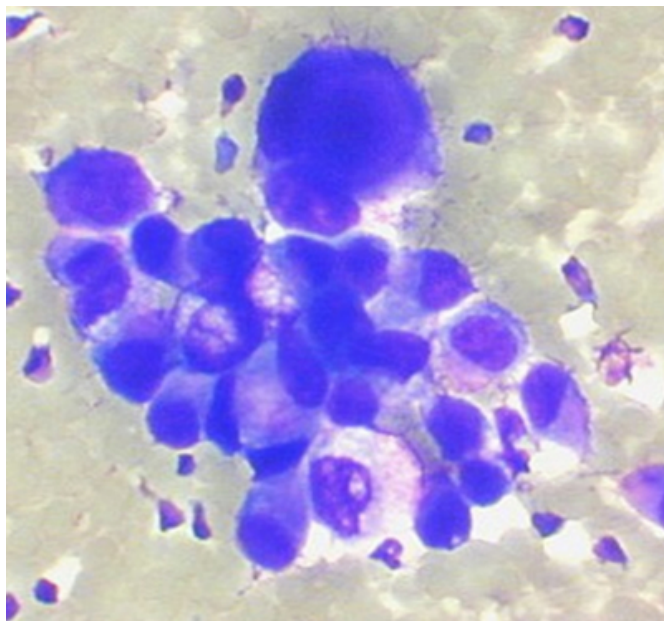
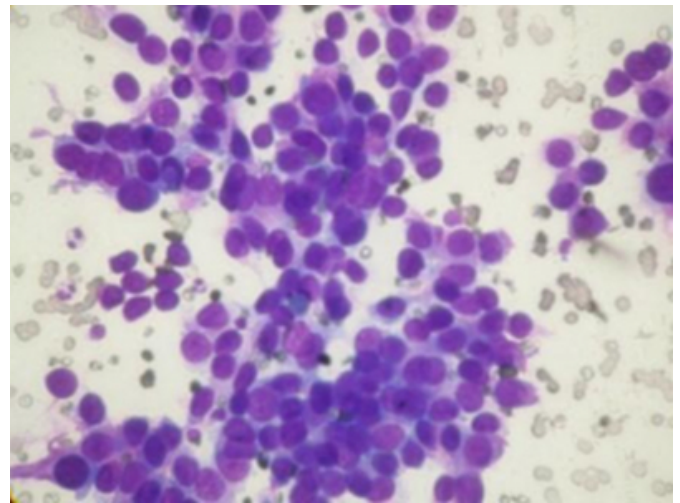


Figure 4

Fig 4 FNAC from skin and umbilical nodule showing pleomorphic cells with a high nuclear cytoplasmic ratio and hyperchromatic nucleus



The CT scan abdomen (fig2) showed bilateral very large solid-cystic heterogeneously enhancing abdomino-pelvic lesions extending from bilateral adnexal regions to the abdomen. These lesions were abutting-involving the fundus & posterior wall of uterus and also abutting the superior part of urinary bladder with focal loss of intervening fat planes.

Multiple small to medium sized hypodense heterogeneously enhancing lesions were seen in both lobes of liver. Anterior abdominal wall deposits were present. There was presence of retroperitoneal, diaphragmatic and bilateral inguinal lymphadenopathy along with ascites.

CT guided FNAC from right ovarian solid cystic mass showed loosely cohesive ball-like clusters, acini and singly dispersed atypical cells on a proteinaceous background. Some of the clusters showed papillary disposition. The tumor cells displayed marked pleomorphism, high nucleocytoplasmic ratio, scant to moderate amount of pale cytoplasm, ill-defined cell borders, round to irregular nuclei, open chromatin and prominent nucleoli. Mucin was present extracellularly as well as intracellularly. Binucleated and bizarre tumor cells were also present. The above features were indicative of an adenocarcinoma of the ovary. (fig 3)

FNAC from skin and umbilical nodule showed atypical cells disposed in discohesive sheets and clusters and having similar morphology as the primary ovarian adenocarcinoma. (Fig 4) Her CA-125 was 377.9u/ml. X-ray chest was normal.

Surgical resection was not possible due to the extensive local spread. In view of the fact that the primary tumour was not

resectable and skin metastases was present, the patient was put on chemotherapy. She was planned for Taxol based chemotherapy, which she took for two cycles and then expired.

We report this case as a rarity of occurrence of adenocarcinoma ovary in a young female and also for the presence of skin and umbilical metastasis.

DISCUSSION

A periumbilical nodule (Sister Mary Joseph nodule) is mostly suggestive of an abdominal malignancy . In about 75% of cases ,the histological type is adenocarcinoma , and is most rarely epidermoid, undifferentiated or carcinoid. In over 55% of cases, the origin is from the digestive tract. Gynecological origin is the second most common etiology, with ovarian cancer being the most common(34% of cases).^[2,3] This is usually associated with poor prognosis. Average survival after discovery is about 10 to 11 months.^[4]

The interval time between diagnosis of ovarian cancer and documentation of cutaneous involvement is the most important prognostic factor associated with survival.^[5]

References

1. Micheal D. Stambaugh. Ovary In; Perez CA and Brady LW; Principle and Practice of Radiation Oncology; Ovary 4th ed. Philadelphia: Lippincott Raven 2004 p1935-1936
2. Touraud JP, Lentz N, Dutronc Y, Mercier E, Sagot P, Lambert D Umbilical cutaneous metastasis (or Sister Mary Joseph's nodule) disclosing an ovarian adenocarcinoma Gynecol Obstet Fertil. 2000 ;28;719-21
3. Dubreuil A, Domp martin A, Barjot P, Louvet S, Leroy D: Umbilical metastasis or Sister Mary Joseph's nodule.Int J Dermatol 1998;37;70-73.
4. Powell FC, Cooper AJ, Massa MC, Goellner JR, Daniel WP: Sister Joseph's nodule: a clinical and histologic study. J Am Acad Derm 1984; 10;610-615
5. Gennaro Cormio A, Mariateresa Capotortoa, Giovanni Di Vagnoa, Ambrogio Cazzollaa, Carmine Carrieroa and Luigi Selvaggia Skin metastases in ovarian carcinoma: A report of nine cases and a review of the literature Gynecologic Oncology 2003;90; 682-685

Author Information

Pragya Shukla, MD(std)

Dept of Radiotherapy, TATA Memorial Cancer Centre

Deepak Gupta, MD(std)

Dept of Radiotherapy, TATA Memorial Cancer Centre

Jitender verma, MD(std)

Dept of Radiotherapy, CSMMU, Lucknow

Shyam Singh Bisht, MD

Dept of oncology, Artemis, Gurgaon

Mohan Chand Pant, MD

Dept of Radiotherapy, CSMMU, Lucknow

Nuzhat Husain, MD

Dept of Pathology, CSMMU, Lucknow

Deepti Mishra, MD

Dept of Surgery, CSMMU, Lucknow