

# An Unusual Reason Of Parotid Gland Enlargement: Parotid Gland Tuberculosis

I Can, H Pulat, V Gunduz, H Oguz, E Samim

## Citation

I Can, H Pulat, V Gunduz, H Oguz, E Samim. *An Unusual Reason Of Parotid Gland Enlargement: Parotid Gland Tuberculosis*. The Internet Journal of Head and Neck Surgery. 2006 Volume 2 Number 1.

## Abstract

**Objective:** Our aim was to better understand the rarely encountered tuberculous parotitis

**Methods:** A case report

**Results:** Parotid gland involvement of tuberculosis is extremely rare, even in endemic region of disease. However, it should be considered in the differential diagnosis of parotid gland masses. Imaging and fine needle aspiration cytology are often inconclusive, and thus most cases require removal of the salivary gland to enable a final diagnosis to be made as in this case. Once the diagnosis of tbc is made, standard antituberculosis treatment is given with an initial phase lasting 2 months and a further phase that lasts 4-6 months

**Conclusion:** Clinicians should have a high index of suspicion for tuberculosis of the parotid gland in patients with a chronic parotid lump, even if the chest radiographs appear normal.

## INTRODUCTION

The incidence of tuberculosis (tbc) is rising throughout the world. Pulmonary tbc is the most frequent form of tbc, but any organ in the body can be involved (1).

Tumors of salivary gland origin are rare. Approximately 80% of tumors of salivary gland origin arise from the parotid gland, and, of these, 80% are benign. Approximately 60-90% of the benign parotid neoplasms are pleomorphic adenomas. Parotid gland tbc is an uncommon disease. Less than 200 cases have been reported since the first description of this condition. These cases include tbc of the intraparotid lymph nodes or primary tbc of the parotid gland substance (2). These intraparotid and periparotid lymph nodes may become infected either by lymphatic drainage from the oral cavity or hematogenously from a pulmonary focus. The diagnosis of parotid gland tbc can only be confirmed by gland excision. Although it is very rare, it should be kept in mind in the differential diagnosis of benign parotid lesions (1).

A case of involvement of intraparotid lymph nodes with tbc was presented in this article. Our purpose was to

investigate the clinical and surgical characteristics of major salivary gland tbc.

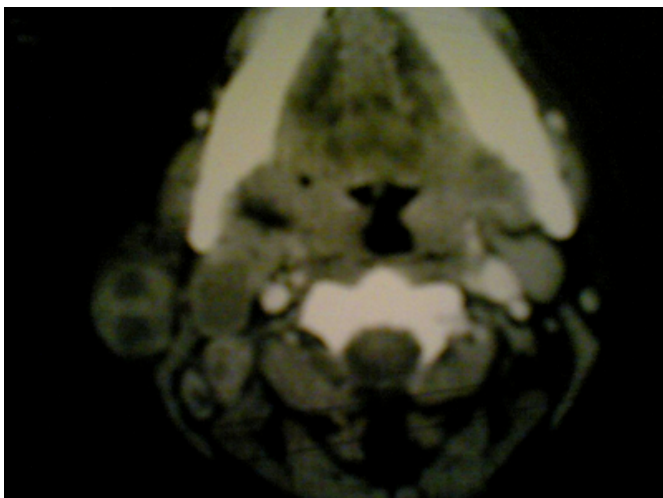## CASE REPORT

A 37 year old female applied to our ENT clinic for the right parotid enlargement. The swelling became larger with time. She had been given several courses of antibiotic treatment for several months with no improvement in her condition. She denied any symptoms of weight loss, cough, fever, chest pain and night swelling. She did not give any past history of tbc infection either in herself or in her family. Examination revealed 4x4 cm painless, rubber like lesion in the right parotid gland and 2x1 cm lymph nodes in the upper servical region. There was no sign of fistula or color change on the overlying skin. Laboratory profile was unremarkable including PPD test, which was done after the pathological investigation. Chest X-ray was normal. Multiple lymph nodes, the largest one was 13x10 mm, were detected in the right parotid gland and multiple lymph nodes, the largest one was 34x22 mm, in the right upper servical region in USG investigation. The spiral CT scan showed 2x2.5 cm, contrast enhanced peripheral borders, central cystic-necrotic, regular contoured, bilobulated lesion in the right parotid gland

(Figure 1). Superior to this lesion there was a 8 mm intraparanchimal lymph node. In the upper servical region, there were multiple lymph nodes with the same scan findings in the parotid gland. These findings were reported as consisted with pleomorphic adenoma or adeno carcinoma. Fine neddle aspirations performed three times showed lymphocytes and germinal center cells and patchy eosinophils. With all these findings, thinking the benign nature of the lesion, parotidectomy was planned for this case. During surgery, the mass was within the parotid gland and very adhesive to surrounding and it was extending to deep lobe. Subtotal parotidectomy with preservation of facial nerve was performed. The frozen section investigation showed granulomatous inflammatory reaction. There were multiple conglomerated, 2x3 cm lymph nodes in the right upper middle and lower servical regions. On gross investigation, there was 6x6x2.5 cm sized, irregular tissue piece. On cut section, 3.2x3.2 cm sized, cream coloured, regularly bordered region contained patchy necrotic focuses (Figure 2). On cut sections of lymph nodes, there were also multiple cream colored necrotic regions. All lymph nodes and parotid lesions were capsulated. The sweat glands were not involved, the intraparotideal lymph nodes were involved. On the light microscopic investigation, epiteloid histiocytes and Langhans type giant cells with caseification necrosis formed conjugating granulomas, which was consistent with tuberculous lyphadenitis (Figure 3). She was put on anti-tuberculous treatment consisting of isoniazid, rifampicin and ethambutol.

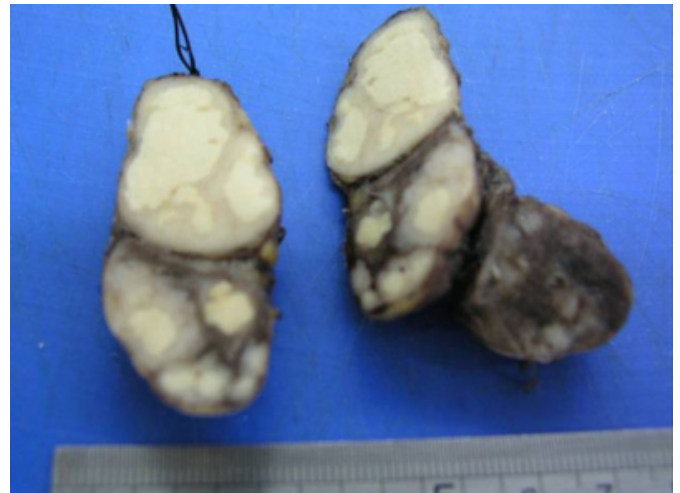### Figure 1

Figure 1: CT scan of the patient



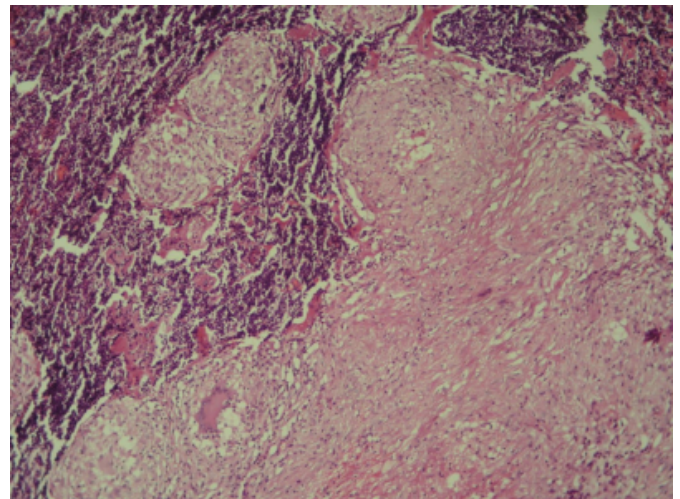
### Figure 2

Figure 2: Macroscopic view of the lesion, creamy yellow necrotic fields



### Figure 3

Figure 3: Microscopic view: Langhans type giant cell and granuloma



## DISCUSSION

Tbc is a common disease in Turkey however tbc infection of the parotid gland is still very rare. The patients usually presents with the painless parotid swelling. Otorrhea and facial paralysis are two uncommon presentations which was encountered in the literature (3, 4).

Tbc of the salivary gland presents as a slow growing, firm to hard nodular mass with a variable degree of fixation. The mass is almost uniformly unilateral and its clinical features are difficult to distinguish from those of a salivary gland neoplasm, thus making its diagnosis challenging (5).

Hematogenous and lymphogenous spread to the parotid

gland from the primary foci seems the most probable route of infection. If a primary focus has not been found, the infection is clinically called primary. The disease either involves the parenchyma of the gland or lymph nodes within or surrounding the gland. Tbc is an infectious disease caused by *Mycobacterium tuberculosis* (in rare cases, *M. Bovis*). It can affect any organ but there is usually a primary pulmonary focus. The transmission is mostly by droplet infection. The definitive diagnosis of tbc depends on isolation and identification of *M. Tuberculosis* from a diagnostic specimen (2).

Tbc of the parotid gland is classified into 2 forms:

1. A focal form that spreads from a tbc infection of the intra or periglandular lymph nodes, as in our case
2. A diffuse form, in which the parenchyma of the parotid gland is involved diffusely.

The differential diagnosis includes: actinomycosis, parotitis, mumps, sarcoidosis, Sjogren's syndrome and sialosis.

Investigations should include chest X ray and skin testing; the skin test is a beneficial adjunct to diagnosis, although it may be misleading (3).

The diagnosis is often challenging. Owing to the neoplastic presentation of the disease, CT has become an important initial diagnostic tool. Reed and Bergeron classified cervical tuberculous lymphadenitis into four categories according to its appearance on a CT scan. The first and second categories feature a mass with a central lucency and a thick enhancing rim and are typical of tuberculous lymphadenitis. The third and fourth categories feature an homogenous enhancing mass, respectively and thus mimic neoplastic and inflammatory conditions, providing no clues in terms of diagnosing salivary gland tuberculosis (3). This particular case was found to belong to the first and two categories mentioned above, thus supporting the diagnosis of tbc. But in general, mycobacterial inflammatory lesions could not be reliably differentiated from neoplastic masses by means of CT alone.

FNAB revealed nothing in this patient. Imaging and fine needle aspiration cytology are often inconclusive, and thus most cases require removal of the salivary gland to enable a

final diagnosis to be made as in this case. Tissue confirmation for diagnosis of tbc is still routine when dealing with tumorous conditions of the major salivary gland. The typical histologic features are the presence of characteristic conglomerating tuberculous granulomas with caseous necrosis, epithelioid cells or Langhans giant cells. However, it should not be forgotten that the early phase of the disease may reveal an acute inflammatory process, which may not be distinguishable from other inflammatory conditions (5, 6).

Once the diagnosis of tbc is made, standard antituberculosis treatment is given with an initial phase lasting 2 months and a further phase that lasts 4-6 months (3). Early initiation of anti-tbc treatment is one of the most important requirements for optimal recovery without complications. The traditional regimen of isoniazid, rifampicin, ethambutol and pyrazinamide was used as first line chemotherapy, and provided good results in the literature. Rescue surgery should be considered when anti-tbc treatment fails. Also, in drug-resistant cases, the anti-tbc agents should be selected carefully and the treatment duration should be extended (5).

In conclusion, tbc should be considered in the differential diagnosis of parotid enlargement especially in patients from endemic region.

### **CORRESPONDENCE TO**

Ilknur Haberal Can, MD Camlica Bulvar Sitesi F Blok No: 19 Umitkoy Ankara Turkey Email: haberalcan@gmail.com Phone: 905325875338

### **References**

1. Erdoğan B, Uzaslan E, Demirdöğen E, Adım ŞB, Salan A, Çakır Ü. An unusual reason of parotid gland enlargement; parotid gland tuberculosis. *Tüberküloz ve Toraks Dergisi* 2006;54(2):182-184.
2. Koç A, Cengiz K, Şengör A, Han T. Tuberculosis of the parotid gland. *Otolaryngology Head and Neck Surgery* 2005;133:1-2.
3. Khodaei I, Rowley H, Muldoon C, Gaffney R. Tuberculosis of the parotid gland in a patient with otorrhea. *Ir Med J* 2001;94:250.
4. Sharma K, Mehdiratta NK, Gupta AK. Tuberculosis of the parotid gland. *Can J Surg* 1996;39:253.
5. Kim YH, Jeong WJ, Jung KY, Sung MW, Kim KH, Kim CS. Diagnosis of major salivary gland tuberculosis: experience of eight cases and review of the literature. *Acta Otolaryngica* 2005;125:1318-1322.
6. Lee IK, Liu JW. Tuberculous parotitis: case report and literature review. *Annals of Otolaryngology and Laryngology* 2005;114(7):547-551.

**Author Information**

**Ilknur Haberal Can, MD**

ENT Clinic, Ministry of Health Ankara Education and Research Hospital

**Haluk Pulat, MD**

Pathology Clinic, Ministry of Health Ankara Education and Research Hospital

**Veli Gunduz, MD**

ENT Clinic, Ministry of Health Ankara Education and Research Hospital

**Haldun Oguz, MD**

ENT Clinic, Ministry of Health Ankara Education and Research Hospital

**Ethem Erdal Samim, MD**

ENT Clinic, Ministry of Health Ankara Education and Research Hospital