

Does Pilonidal Sinus Locate In The Scalp?

H SINAN, I SUCULLU, A FILIZ, M INCE

Citation

H SINAN, I SUCULLU, A FILIZ, M INCE. *Does Pilonidal Sinus Locate In The Scalp?*. The Internet Journal of Surgery. 2008 Volume 21 Number 2.

Abstract

Pilonidal sinus disease has been described as a hair dressers' or (barbers') disease because of short hairs that penetrate the interdigital spaces of the hand. Pilonidal sinus disease is common around the sacrococcygeal region but rarely seen in the anal canal, umbilicus, chest wall, ear, or on the scalp. Our case involves a 21-year-old man who was doing his military service. He complained of a mass which he had had for several years around the left occipital region of the scalp, the patient's medical history seemed uneventful. We totally excised the lesion and sutured. After the operation, histopathology confirmed our diagnosis as pilonidal sinus of the scalp. After a three-month follow-up, the patient had made a complete recovery. Pilonidal sinus disease involves a hair-containing sinus first described by Herbert Mayo in 1833 [1]. In 1880, Hodge suggested the term "pilonidal"[2] from the Latin "pilus" for hair and "nidus" meaning nest, and later Karydakakis [3,4] defined the pathogenesis of this disease. After a long debate the disease is no longer considered a congenital abnormality even though 50-70% of cases have hair shafts in the lesion. Pilonidal sinus disease has been described as a hair dressers' or (barbers') disease because of short hairs that penetrate the interdigital spaces of the hand [5,6,7]. The mechanism for the formation of sinuses by hairs was postulated by Hodges in 1880 in an article on postnasal pilonidal sinus [2]. The first case of a sinus in a hairdresser was described by Templeton in 1942 [7]. Pilonidal sinus disease is common around the sacrococcygeal region [8] but rarely seen in the anal canal [9], umbilicus [10], chest wall [11], ear [12], or on the scalp [13]. As near as we can determine, only a few cases appear in the existing literature. We are reporting here on an unusual case of pilonidal sinus of the scalp with no apparent reason.

CASE

Our case involves a 21-year-old man who was doing his military service. He complained of a mass which he had had for several years around the left occipital region of the scalp. The patient's medical history seemed uneventful, and when palpated upon physical examination, the approximately 2 x 2 x 2cm soft mass was movable and painless. In order to reveal the relation between the mass and cranium a cranial ultrasonography was performed. According to the ultrasonography, there was no invagination inside the cranium and it looked like a lipoma or sebaceous cyst. The patient was informed about the mass, and a decision was made to have it removed. After the necessary preparations, we operated on the patient under local anaesthesia. We were expecting to remove the lipoma-like mass easily, but during the operation we encountered a pouch filled with hair (Figure1-2). We totally excised the lesion and sutured. After the operation, the specimen was fixed with formalin. Histopathology confirmed our diagnosis as pilonidal sinus of the scalp. After a three-month follow-up, the patient had made a complete recovery.

Figure 1

Figure 1: Incision on the scalp

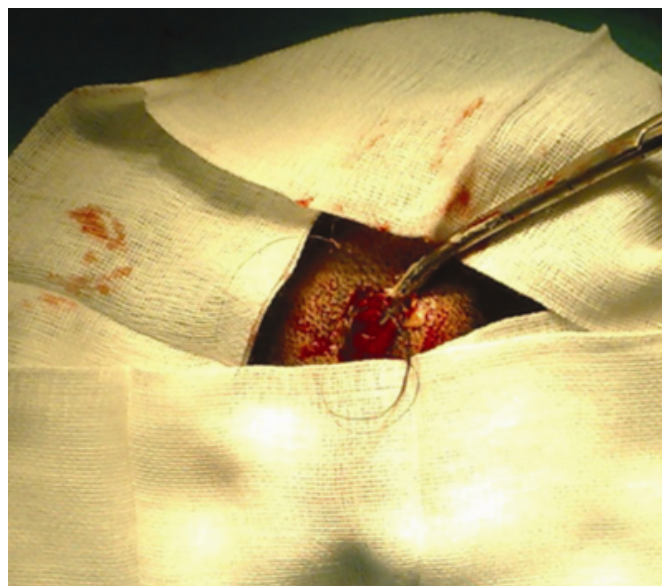
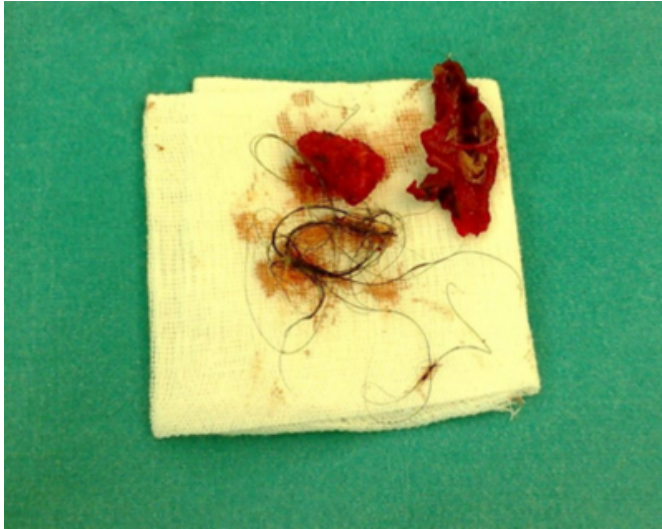


Figure 2

Figure 2: The pouch of the pilonidal sinus



DISCUSSION

As stated earlier, the pathogenesis of pilonidal sinus disease was first defined by Karydakís [3,4]. It appears primarily in adults, never in children, and [14] after a long debate the disease is no longer considered a congenital abnormality. Over the years, other symptoms or phenomena described in the hands or fingertips have been well recognized as an occupational disease among barbers, hairstylists and pet groomers [15,16].

There have been two reports regarding pilonidal sinus on the scalp [13, 15]. Moyer described a young boy who received blows to the occipital region repetitively [13]. The second case, described by Kosaka, involved a 4-year-old boy who fell within a room, impacting the occipital region. After the injury, a small scar remained in the injured region. Later, over a period of 15 months, a slightly painful mass developed on the occipital alopecia. After surgery the patient had been recurrence-free for 1 year [15]. The case we have just presented is the third example (with respect to English language publications) regarding occipital pilonidal sinus.

There were clear reasons for the previous two cases, but in our case there was no apparent reason to explain the appearance of the pilonidal sinus on the scalp.

ACKNOWLEDGEMENT

The authors thank Paula M. Knauer for editorial assistance.

References

1. Mayo OH (1833). Observations on injuries and disease of rectum, pp. 45-46. Burgess and Hill, London (Quoted from: da Silva JH. Pilonidal cyst: cause and treatment. Dis Colon Rectum 2000;43:1146-56).
2. Hodge RM. Pilonidal sinus. Boston Medical Surg J 1880 (Quoted from da Silva JH. Pilonidal cyst: cause and treatment. Dis Colon Rectum 2000;43:1146-56)
3. Karydakís GE. New approach to the problem of pilonidal sinus. Lancet 1973;2:1414-5.
4. Karydakís GE. Easy and successful treatment of pilonidal sinus; after explanation of its causative process. Aust NZ J Surg 1992;62:385-9.
5. Jochims J, Brandt KA. Interdigital pilonidal sinus ("barber's disease"): a rare occupational disease. 1998;69:1280-1.
6. Uysal AC, Alagoz MS, Unlu RE and et al. Hair dresser's syndrome: A case report of an interdigital pilonidal sinus and review of the literature. Dermatol Surg 2003;29:288-290.
7. Templeton HJ. Foreign body granuloma or interdigital cysts with hair formation. Arch Dermatol Syuph 1942;46:157-8.
8. Patey D. Pilonidal sinus or "jeep disease.". Nurs Times 1971;67:534-6.
9. Wilson E, Failes DG, Killingback M. Pilonidal sinus of the anal canal: report of a case. Dis Colon Rectum 1971;14:468-70.
10. Allegaert WJ. Pilonidal sinus of the umbilicus. Br J Clin Pract 1967;21:201.
11. Saggat RP. Pilonidal disease of the chest wall. J Ir Med Assoc 1967;60:125-7.
12. Woodward WW. A pilonidal sinus of the ear. Aust NZ J Surg 1965;35:72-3.
13. Moyer DG. Pilonidal cyst of the scalp. Arch Dermatol 1972;105:578-9.
14. Raffman RA. A re-evaluation of the pathogenesis of pilonidal sinus. Ann Surg 1959;150:895-903.
15. Kosaka M, Kida M, Mori H, et al. Pilonidal cyst of the scalp due to single minor trauma. Dermatol Surg 2007;33:505-507.
16. Patel MR, Bassini L, Nashad R, et al. Barber's interdigital pilonidal sinus of the hand; a foreign body hair granuloma. J Hand Surg 1990;15A:652-5.

Author Information

H. SINAN, MD

Department of Surgery, UW School of Medicine

I. SUCULLU, MD

Department of Surgery, UW School of Medicine

A.I. FILIZ, MD

Department of Surgery, UW School of Medicine

M. INCE, MD

Department of Surgery, UW School of Medicine