

Postpartum Haematogenous Osteomyelitis Of The Tibia: A Case Report And Review Of Literature

R Lee, E How

Citation

R Lee, E How. *Postpartum Haematogenous Osteomyelitis Of The Tibia: A Case Report And Review Of Literature*. The Internet Journal of Orthopedic Surgery. 2009 Volume 18 Number 1.

Abstract

Osteomyelitis is a disease that usually affects children^{1,2}. In adults, infection of long bones is particularly uncommon³. We present a 20-year-old lady with postpartum haematogenous osteomyelitis of the tibia caused by methicillin-resistant *Staphylococcus aureus* (MRSA) that was isolated from blood and bone. The patient was two months postpartum when she first presented with her only complaint being a swollen and painful knee. Thorough surgical debridement of the tibia and six weeks of intravenous antibiotics produced excellent results in this patient. A high-index of suspicion accompanied by appropriate imaging methods is essential for early diagnosis and successful treatment.

INTRODUCTION

Osteomyelitis is one of the oldest recorded diseases⁵ and is primarily a disease of children, with up to 85% of cases occurring in patients under 17 years of age². Most cases in adults are seen in patients over age 50 and unlike children, very rarely involve long bones^{3,6}. The most common sites of infection in adults are the vertebral bodies and pelvis^{1,3,4,7,8}. Apart from haematogenous seeding, osteomyelitis can also occur as a result of direct inoculation of microorganisms into bone or a contiguous focus of infection⁴. *Staphylococcus aureus* is the most common organism responsible for this infection in both age groups^{4,9}.

Review of the current literature only returned a handful of case reports with regards to postpartum haematogenous osteomyelitis. The cases that have been reported to date mainly involved the pelvis or vertebrae^{10,11,12,13,14}; none involving long bones. Also, there have not been any reports of this disease caused by methicillin-resistant *Staphylococcus aureus* (MRSA). We report a case of postpartum haematogenous osteomyelitis of the tibia in a 20-year-old lady with MRSA isolated from blood and bone.

CASE REPORT

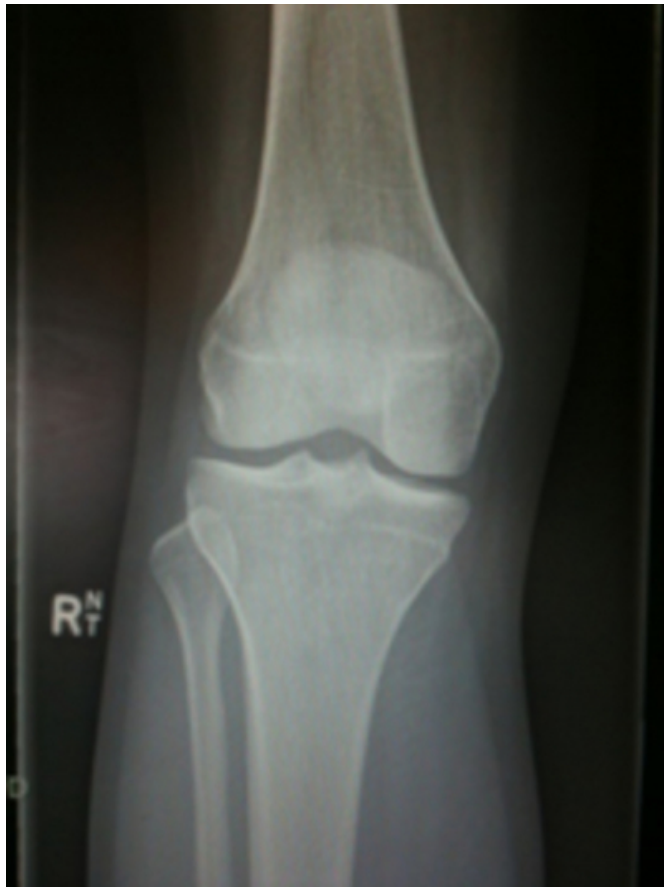A 20-year-old non-indigenous, Australian female presented to the Emergency Department with a one day history of acute pain and swelling over the right knee. She denied any recent trauma to the right knee and has been feeling well otherwise. It was noted that she had a normal vaginal

delivery of her first child nine weeks prior which was uncomplicated. This was also her first pregnancy. She did not have any past medical history and denied previous recreational drug use. Examination of the right knee only showed mild tenderness and minimal swelling around the patella. She was able to walk and fully weight bear on the right leg with only slight pain. All vital signs were within normal limits. A diagnosis of patellar tendonitis was made and the patient discharged with simple analgesia.

This patient returned 48 hours later with severe pain of her right knee and was unable to weight bear or bend her knee. On examination, the right knee appeared slightly swollen but was not red. It was very tender and warm to touch with minimal range of movement. She had remained systemically well. Plain radiographs of the knee did not show any obvious abnormalities (Figure 1).

Figure 1

Figure 1: Plan radiograph of right knee joint



A knee joint aspiration was performed and initial gram stain revealed no crystals, low white cells ($540 \times 10^6/L$) and no organisms. Although her white cell count in blood was normal, her erythrocyte sedimentation rate (ESR) and C-reactive protein (CRP) levels were elevated to 74mm/hr and 91mg/L respectively.

An arthroscopic washout of the right knee was then performed. Turbid joint fluid was obtained but microbiology testing of the specimen was again negative for any growth with low white cells ($670 \times 10^6/L$). By this time, her blood cultures had come back positive for MRSA which was only sensitive to vancomycin and clindamycin. The patient was promptly started on intravenous vancomycin with daily pre-dose levels checked.

This patient's condition deteriorated in the ensuing days with high-grade temperatures, tachycardia and rigors by the seventh day of onset of knee pain. Her inflammatory markers rose steadily despite treatment with therapeutic doses of intravenous vancomycin. Her knee pain too, did not abate.

The diagnosis only became obvious after this patient underwent magnetic resonance imaging (MRI) 10 days after initial onset of knee pain. MRI of the right lower limb showed decreased signal intensity on T1-weighted images and increased signal intensity on T2-weighted images throughout the marrow of the proximal right tibial metaphysis. This was in keeping with extensive osteomyelitis corresponding to Cierny-Mader Stage 1A¹⁵ (Figures 2 to 5).

Figure 2

Figures 2 and 3: Coronal sections on MRI of right knee showing irregular signal throughout the marrow of proximal right tibia.

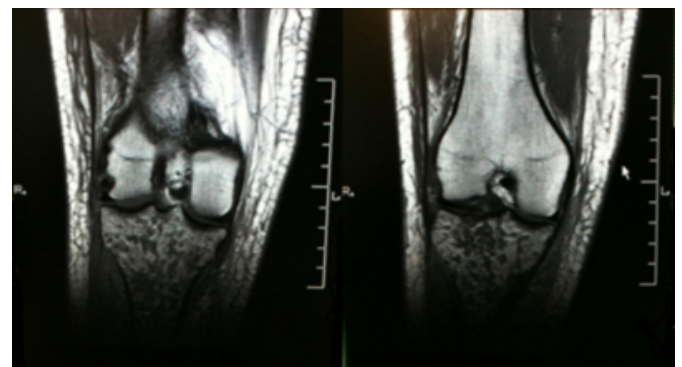
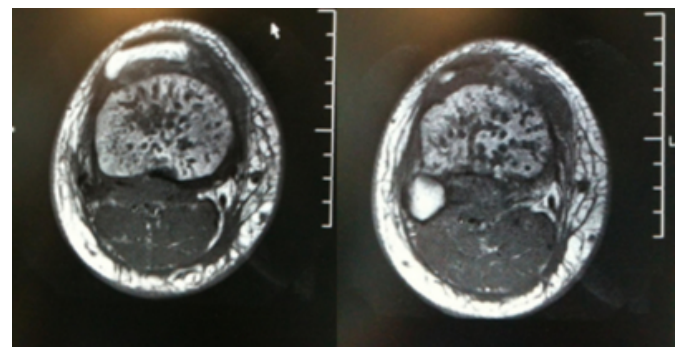


Figure 3

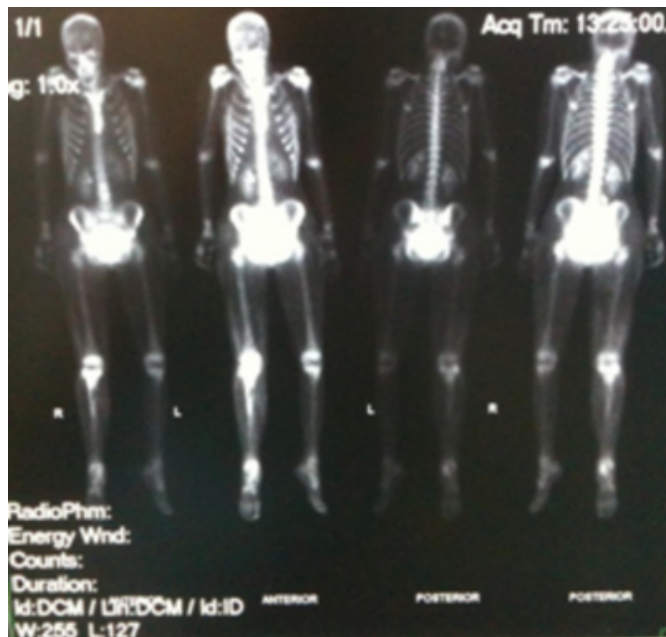Figures 4 and 5: Transverse sections on MRI of right knee showing irregular signal throughout the marrow of proximal right tibia



A three phase, whole body bone scan also supported the diagnosis of osteomyelitis in this region (Figure 6). There were no other abnormalities elsewhere on both modalities.

Figure 4

Figure 6: Bone scan images showing increased tracer activity in the proximal right tibial metaphysis. Note this patient was unable to empty her bladder before the scan.



This patient subsequently had surgical debridement of the right proximal tibia which yielded 100ml of frank pus. Five holes were drilled on the antero-lateral side of proximal tibia and a wound drain was left in situ for 48 hours. Culture and sensitivity results of the purulent specimen and bone tissue were identical to that found in blood earlier. After another two washouts in the following week, this patient made an excellent recovery with resolution of symptoms and steady improvement in inflammatory marker levels. She received six weeks of intravenous vancomycin after surgical debridement followed by two months of oral clindamycin as per advice from the infectious diseases physicians. Follow up at six weeks post-debridement showed that this patient had made a full recovery and normalisation of all inflammatory markers.

DISCUSSION

Osteomyelitis in long bones occurs much more commonly in children than in adults^{1,2}. This is mainly due to differences in the anatomy of blood vessels in the long bones of children and adults. Three causes of osteomyelitis have been established; haematogenous spread, direct inoculation of organisms into bone, or a contiguous focus of infection⁴. There are also several patient factors that may increase the risk of osteomyelitis such as diabetes mellitus, intravenous drug use, malignancy and immune disease⁴.

There are only a handful of articles in literature describing the occurrence of acute osteomyelitis in postpartum women^{10,11,12,13,14}. While the common cause in these cases appears to be haematogenous spread, the exact pathogenesis is unclear. Berkowitz and McCaffrey suggested that an altered immune status in pregnancy and intrapartum bacteraemia could be a mechanism¹⁴. Others have suggested seeding of microorganisms into bloodstream through tears in the birth canal during delivery^{11,12}. In the reported cases, only the pelvis (pubis and sacro-iliac joint) or vertebrae were affected. Also, methicillin-sensitive *Staphylococcus aureus* (MSSA) or group B streptococci has been the usual culprits.

Regardless of whether a patient is postpartum, we believe that this case highlights several key points in management. Firstly, the vague and non-specific nature of osteomyelitis in adults⁴ demands a high index of suspicion for early and accurate diagnosis. The fact that a patient presents with symptoms in the postpartum period should just provide a hint of bacteraemia being a potential cause for the problem. A seemingly unremarkable joint aspirate (as in this case) does not exclude osteomyelitis although septic arthritis can be an indicator of infection in adjacent bone(s)¹⁶. It is also worth noting that blood tests for inflammatory markers (ESR and CRP) are not sensitive and specific enough for the diagnosis of osteomyelitis⁴.

Secondly, it is important to have an understanding of the roles and limitations of the different imaging modalities. Plain radiographs are readily available and relatively inexpensive, but findings lag at least two weeks behind the process of infection^{4,17}. This is especially true in early infection when findings may be subtle or radiographically absent¹⁷. Magnetic resonance imaging (MRI) is the modality of choice for early detection of acute osteomyelitis due to its very high sensitivity and specificity^{18,19}. Having said that, this investigation is relatively more expensive to conduct and accessibility may be an issue for patients presenting to rural or remote hospitals.

The patient in this case presented to our centre which does not have an in-house MRI scanner. As a result, despite her deteriorating clinical condition, she had to wait over the weekend to have her MRI at a private facility out of town.

MRI is also not useful for whole-body scans and is not suitable for patients with cardiac pacemakers or insulin pumps. Even metallic implants that are MRI-compatible may obscure a region of interest due to metallic susceptibility artifact⁴. In these circumstances, a three phase

bone scan may prove to be more useful than MRI. Several studies have indicated that a three phase bone scan has a sensitivity and specificity of about 95% if plain radiographs are normal^{20,21,22}. Computed tomography (CT) may also play a role in the diagnosis of osteomyelitis but is disadvantaged when metal is present near the region of interest⁴.

Lastly, osteomyelitis in adults is more refractory to treatment and usually requires antibiotics and surgical debridement⁴. Lazzarini et al. recommended four weeks of appropriate parenteral antibiotic therapy from the last debridement, although the final decision on duration and route of administration should be based on a surgeon's experience and consultation with infectious diseases specialists. It should also be noted that previous studies have shown no benefit with longer courses of oral or intravenous antibiotics (six months or more)^{24,25}. On a separate note, the emergence of methicillin-resistant *Staphylococcus aureus* (MRSA) infections could prove to be even more difficult and expensive to treat with greater restriction on antibiotic choice. It has been reported that failure of therapy occurs mostly as a result of emergence of resistant strains or inadequate operative treatment⁴.

The principles of surgical debridement include adequate drainage, thorough debridement of necrotic tissue, obliteration of dead spaces, adequate soft tissue coverage and restoring effective blood supply²³. In addition, the patient in this case had surgical drilling of the tibia which has been shown to increase the overall success rate of treatment²⁶.

In conclusion, osteomyelitis of long bones in adults is uncommon and often presents with non-specific signs and symptoms. A high index of suspicion is needed for early diagnosis of this condition, especially in the postpartum patient. MRI is the investigation of choice but cost and accessibility factors may delay the diagnosis. Meticulous operative treatment and an appropriate duration of antibiotic therapy are vital in ensuring a favourable outcome.

References

1. David R, Barron BJ, Madewell JE: Osteomyelitis, acute and chronic. *Radiol Clin North Am*; 1987; 25: 1171
2. Mader JT, Shirliff M, Calhoun JH: The host and the skeletal infection: classification and pathogenesis of acute bacterial bone and joint sepsis. *Baillieres Best Pract Res Clin Rheumatol*; 1999; 13: 1
3. Gordon RJ, Lowy FD: Bacterial infections in drug users. *N Engl J Med*; 2005; 353: 1945
4. Lazzarini L, Mader JT, Calhoun JH: Osteomyelitis in Long Bones. *J Bone Joint Surg Am*; 2004; 86: 2305-2318
5. Lew DP, Waldvogel FA: Osteomyelitis. *Lancet*; 2004; 364: 369
6. Chandrasekar PH, Narula AP: Bone and joint infections in intravenous drug abusers. *Rev Infect Dis*; 1986; 8: 904
7. Espersen F, Frimodt-Moller N, Thamdrup Rosdahl V, et al.: Changing pattern of bone and joint infections due to *Staphylococcus aureus*: study of cases of bacteremia in Denmark, 1959-1988. *Rev Infect Dis*; 1991; 13: 347
8. Pedersen H, Engberg JH, Oturai PS: Acute multifocal osteomyelitis caused by haemolytic group B streptococci. *Ugeskr Laeger*; 2006; 168(6): 589-590
9. Lew DP, Waldvogel FA: Osteomyelitis. *N Engl J Med*; 1997; 336: 999-1007
10. Lischke JH, McCreight PH: Maternal group B streptococcal vertebral osteomyelitis: an unusual complication of vaginal delivery. *Obstet Gynecol*; 1990; 76 (3 Pt 2): 489-491
11. Lovisetti G, Sala F, Battaini A, et al.: Osteomyelitis of the pubic symphysis, abscess and late dysjunction after delivery. A case report. *Chir Organi Mov*; 2000; 85(1): 85-88
12. Eskridge C, Longo S, Kwark J, et al.: Osteomyelitis pubis occurring after spontaneous vaginal delivery: a case presentation. *J Perinatol*; 1997; 17(4): 321-324
13. Delbarre F, Rondier J, Delrieu F, et al.: Pyogenic infection of the sacro-iliac joint. Report of thirteen cases. *J Bone Joint Surg Am*; 1975; 57: 819-825
14. Berkowitz K, McCaffrey R: Postpartum osteomyelitis caused by group B streptococcus. *Am J Obstet Gynecol*; 1990; 163 (4 Pt 1): 1200-1201
15. Cierny G, Mader JT, Penninck JJ: A clinical staging system for adult osteomyelitis. *Comtemp Orthop*; 1985; 10: 17-37
16. Calhoun JH, Manring MM, Shirliff ME: Osteomyelitis of the long bones. *Sem Plastic Surg*; 2009; 23: 59
17. Gold RH, Hawkins RA, Katz RD: Bacterial osteomyelitis: findings on plain radiography, CT, MR and scintigraphy. *AJR Am J Roentgenol*; 1991; 157: 365
18. Ma LD, Frassica FJ, Bluemke DA, et al.: CT and MRI evaluation of musculoskeletal infection. *Crit Rev Diagn Imaging*; 1997; 38: 535-568
19. Erdman WA, Tamburro F, Jayson HT, et al.: Osteomyelitis: characteristics and pitfalls of diagnosis with MR imaging. *Radiology*; 1991; 180: 533
20. Pineda C, Vargas A, Rodriguez AV: Imaging of osteomyelitis: current concepts. *Infect Dis Clin North Am*; 2006; 20: 789
21. Schauwecker DS: The scintigraphic diagnosis of osteomyelitis. *AJR Am J Roentgenol*; 1992; 158: 9
22. Schauwecker DS: The role of nuclear medicine in osteomyelitis. In: *Skeletal Nuclear Medicine*, Collier DB, et al (eds), Mosby, St Louis, 1996.
23. Cierny G, Mader JT: The surgical treatment of adult osteomyelitis. In: *Evarts CMC, editor. Surgery of the musculoskeletal system*. New York: Churchill Livingstone; 1983. p15-35.
24. Hedstrom SA: The prognosis of chronic staphylococcal osteomyelitis after long-term antibiotic treatment. *Scand J Infect Dis*; 1974; 6: 33-38
25. Wagner DK, Collier BD, Rytel MW: Long-term intravenous antibiotic therapy in chronic osteomyelitis. *Arch Intern Med*; 1985; 145: 1073-1078
26. Danielsson LG, Duppe H: Acute hematogenous osteomyelitis of the neck of femur in children treated with drilling. *Acta Orthop Scand*; 2002; 73(3): 311-316

Author Information

Richard G Lee, MBBS, BMedSc (Hons)

Department of Orthopaedics, Toowoomba Base Hospital

Elena PL How, MBBS, BMedSc (Hons)

Department of Surgery, Toowoomba Base Hospital