

Abdominal aortic aneurysm: A Surgical Cause For Isolated Thrombocytopenia And Easy Bruising

N Rafique, S Mossadegh, S Kumar, N Menon

Citation

N Rafique, S Mossadegh, S Kumar, N Menon. *Abdominal aortic aneurysm: A Surgical Cause For Isolated Thrombocytopenia And Easy Bruising*. The Internet Journal of Surgery. 2007 Volume 16 Number 1.

Abstract

Most causes of thrombocytopenia are non-surgical and are managed medically. However, surgical causes should not be overlooked. We report an eighty-year-old male patient who presented with easy bruising because of thrombocytopenia. Evaluation showed a large infra-renal abdominal aortic aneurysm with associated iliac aneurysm. Surgical repair of the aneurysms resolved the thrombocytopenia. Abdominal aortic aneurysm should be considered in evaluating elderly patients with easy bruising and/or thrombocytopenia.

INTRODUCTION

Thrombocytopenia may be caused by reduced production, increased destruction or sequestration of platelets. With exceptions such as hypersplenism and idiopathic thrombocytopenic purpura, which may benefit from surgery, the causes are usually managed medically. We report the case of a patient who was thrombocytopenic, presented initially with easy bruising and was found to have a large abdominal aortic aneurysm, the surgical treatment of which cured the thrombocytopenia.

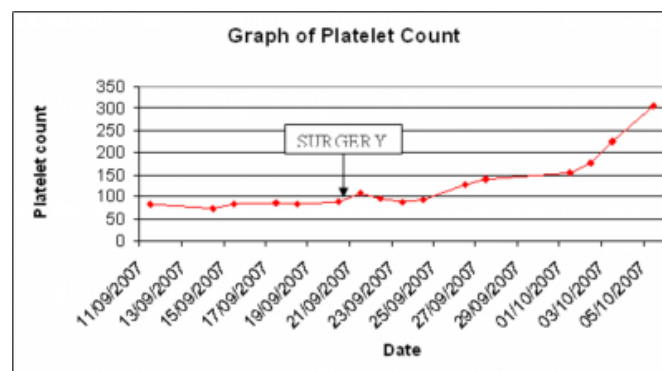
CASE REPORT

An 80-year-old Caucasian gentleman was referred to the medical assessment unit by his general practitioner for a low platelet count ($77 \times 10^9/L$) and easy bruising. The patient had a history of easy bruising for one month, but was otherwise asymptomatic. On examination, he had no hepatosplenomegaly. However, an incidental finding of a large abdominal aortic aneurysm (AAA) was noted. An urgent CT scan confirmed an infra-renal AAA of 10cm diameter, a right common iliac aneurysm of 7cm and a left common iliac aneurysm of 5cm diameter. There was no other cause for the thrombocytopenia. The prothrombin time and activated partial thromboplastin time were normal.

The patient underwent an open endoaneurysmorrhaphy of his aortic and iliac aneurysms using a dacron tube graft. A total of 8 units of packed red cells, 4 units of platelets and 2 units fresh frozen plasma were transfused perioperatively. His postoperative course was uneventful. Interestingly, his

platelet count showed a steady increase postoperatively starting from the third postoperative day and reaching normal levels by the seventh day. The increase was sustained when he was discharged on the 14th day (fig. 1). His pre-operative platelet count was $88 \times 10^9/L$, while the platelet count at discharge was $303 \times 10^9/L$. The platelet count remained normal at follow up 2 months later.

Figure 1



DISCUSSION

The management of abdominal aortic aneurysms may be complicated by coagulopathy. This is often seen intra-operatively or postoperatively due a multitude of factors including blood loss, multiple transfusions and the effects of aortic cross clamping. Pre-operative low-grade disseminated intravascular coagulation (DIC) has been reported in association with AAA, but is uncommon^{1,2,3,4}. Patients with aortic aneurysms have been observed to have a slightly lower platelet count than the general population⁵. The

patient presented above had pre-operative isolated thrombocytopenia which was corrected by treatment of his aneurysm. While the patient received two units of platelet transfusion intra-operatively, the continued and sustained rise in the platelet count two weeks after transfusion cannot be explained by the transfused platelets as the lifespan for platelets is only 5-10 days₆. Mukaiyama et al. have demonstrated increased platelet activity in aneurysms by using Indium-111 labelling technique₇. We propose that the symptomatic thrombocytopenia was due to consumption at the site of the aneurysm. In elderly patients who present with easy bruising and thrombocytopenia, the possibility of an abdominal aortic aneurysm should be considered in the diagnostic work up.

CORRESPONDENCE TO

Dr Senthil Kumar Flat 83, City view, Centreway Axonplace
Ilford Essex, UK IG1 1NH E mail: sanskriti@hotmail.com
Ph: 00-44-07737495294

References

1. Thompson RW, Adams DH, Cohen JR, Mannick JA, Whittemore AD. Disseminated intravascular coagulation caused by abdominal aortic aneurysm. *Journal of Vascular Surgery* 1986; 4: 184-186.
2. Aboulafia DM, Aboulafia ED. Aortic aneurysm-induced disseminated intravascular coagulation. *Annals of Vascular Surgery* 1996; 10: 396-405.
3. Rowlands TE, Norfolk D, Homer-Vanniasinkam S. Chronic disseminated intravascular coagulopathy cured by abdominal aortic aneurysm repair *Cardiovascular Surgery* 2000; 8 (4): 292-294.
4. Nikapota ADB, Stern SCM. Bruising in a man with aortic aneurysms. *J R Soc Med* 2002; 95: 556-557.
5. Milne AA, Adam DJ, Murphy WG and Ruckley CV. Effects of asymptomatic abdominal aortic aneurysms on the coagulation system, platelet count and platelet activation. *European Journal of Vascular and Endovascular Surgery* 1999; 17: 434-437.
6. Najeau Y, Ardaillou N, Dresch C. Platelet lifespan. *Annual Review of Medicine* 1969; Vol. 20: 47.
7. Mukaiyama H, Shionoya S, Ikezawa T, Kamiya T, Hamaguchi M, Saito H. Abdominal aortic aneurysm complicated with chronic disseminated intravascular coagulopathy: a case of surgical treatment. *Journal of Vascular Surgery* 1987; 6: 600-604.

Author Information

Nadia Rafique, MBChB

Foundation year 1 trainee, Department of Surgery, Basildon and Thurrock University Hospital

Somayyeh Mossadegh, MBChB

Foundation year 1 trainee, Department of Surgery, Basildon and Thurrock University Hospital

Senthil Kumar, MS, FRCS (Ed)

Specialist Registrar in Surgery, Department of Surgery, Basildon and Thurrock University Hospital

NJ Menon, MS, FRCS (Ed)

Consultant Vascular Surgeon, Department of Surgery, Basildon and Thurrock University Hospital