

# Evaluation of Oral manifestations as correlates in Thalassemia major cases in current dental practice in Central part of India

P Raju, M Chaudhary, V Wadhwan

## Citation

P Raju, M Chaudhary, V Wadhwan. *Evaluation of Oral manifestations as correlates in Thalassemia major cases in current dental practice in Central part of India*. The Internet Journal of Hematology. 2008 Volume 6 Number 2.

## Abstract

Thalassemia is one of the most common genetic disorders worldwide. It is the commonest of all the inherited hemolytic anemias seen in India. It is important to recognize this condition due to its implications in routine clinical practice such as during minor surgical procedures. Although rare, it is seen that thalassemia major cases go undiagnosed until 6-7 yrs of life. Therefore it is prudent on the part of dentist to have a high index of suspicion of this condition on the basis of oral manifestations. This study was carried out with the purpose to evaluate various oral manifestations, which will help the dental practitioner to suspect the condition, so that proper steps can be done before commencement of any clinical procedures.

## INTRODUCTION

Thalassemia is the commonest of all the inherited hemolytic anemias seen in India. Though the earliest case was described in 1925, it was only after 1940, that the genetic variants of this disorder were appreciated. Thalassemia results from decreased synthesis of one or more of the  $\alpha$  or  $\beta$  globin chains<sup>1</sup>. Based on clinical and genetic entities, thalassemias are classified as homozygous, heterozygous or compound heterozygous. The heterozygous form (thalassemia minor) is mild, with minimal clinical expression. The heterozygous form of  $\beta$ -thalassemia (thalassemia major) exhibits the most severe clinical symptoms with marked orofacial defects. A less severe form, thalassemia intermedia also occurs<sup>2</sup>. At 4 to 6 months of life, with the change from fetal  $\gamma\gamma$  chain to adult  $\alpha\beta$  chain hemoglobin production, the first clinical manifestations appear. Apart from other general manifestations such as, anemia, decrease in growth and development, pallor, hepatomegaly, splenomegaly, the dental and facial abnormalities include spacing of teeth, open bite, prominent malar bones, protrusion of maxilla and saddle nose. Bimaxillary protrusion and other occlusal abnormalities are also frequently seen in thalassemia major cases<sup>3</sup>.

The aim of the study was to assess different oral manifestations in patients with  $\beta$ -Thalassemia in rural parts of Vidarbha region, Maharashtra state, India to help the dentists recognize this condition on time.

## MATERIALS AND METHODS

The data for this study was obtained from the archives of Acharya Vinoba Bhave Rural Hospital, DMIMS, Wardha; Civil Hospital, Wardha, Civil Hospital, Chandrapur and IGMC, Nagpur. A total of 34 diagnosed patients of thalassemia major were considered for the study (males- 21, females- 13). The age groups of the patients ranged between 6 to 15yrs. Patients were further examined clinically and the intra-oral findings were documented. OPG & Lateral Skull Radiographs were also taken for all the cases to see for any bony changes.

## RESULTS

The numbers of patients with  $\beta$ -thalassemia major were 34; 21(61.7%) males and 13(38.2%) females in the age group of 6 to 15 years. Most of them (91%) were in the first decade of life.

There was not any relationship between the complications and sex. The prevalence of dental complications of  $\beta$ -thalassemia major patients has been shown in Table 1. Radiological features observed in decreasing frequency were; loss of trabecular pattern (83%), thinning of lamina dura (65%) and hair-on-end appearance of skull (33%).

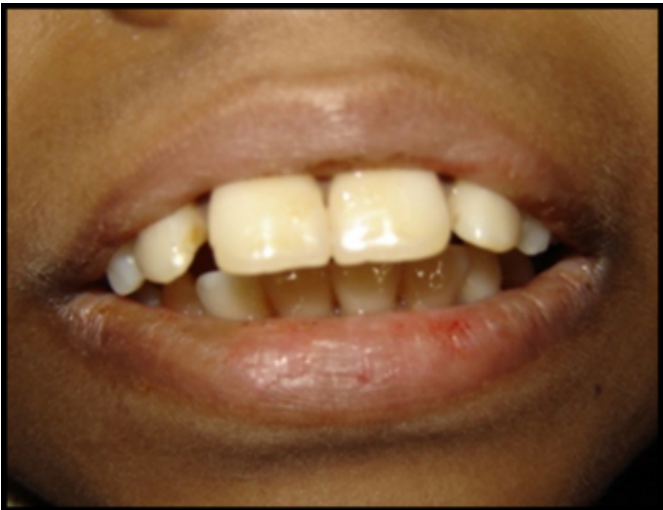**Figure 1**

Table 1: Prevalence of oral manifestations

C/F	No. of cases (n=34)	%
Pallor of mucosa	34	100
Malocclusion	28	82.3
Proclination	26	76.4
High-arched palate	21	61.7
Spacing	15	44.1
Caries	10	29.4
Delayed eruption	07	20.5

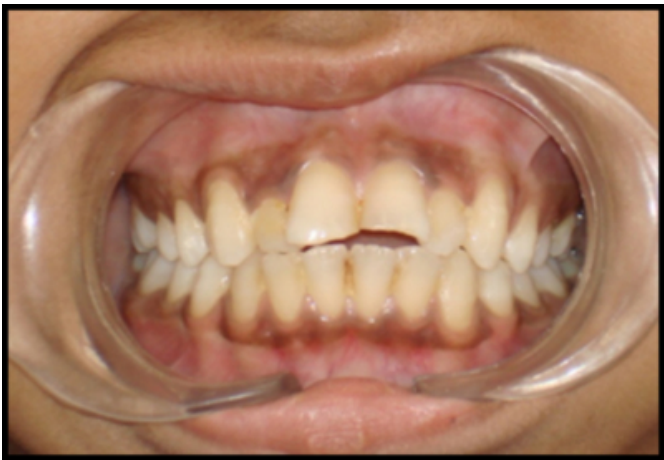**Figure 2**

Fig.1: Proclination of anterior teeth



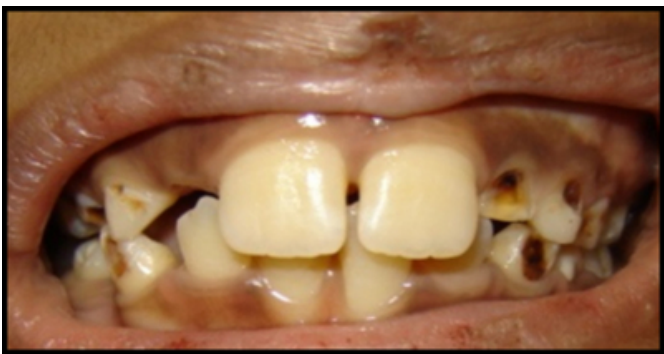**Figure 3**

Fig.2: Malocclusion



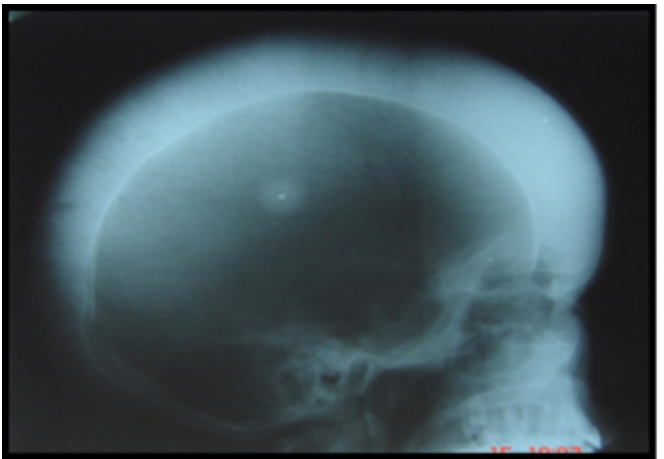
**Figure 4**

Fig. 3: Dental Caries



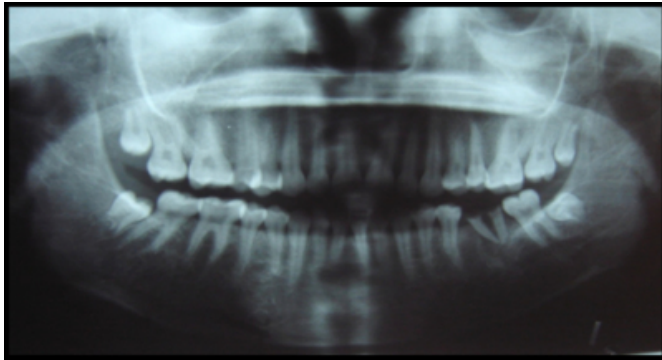
**Figure 5**

Fig.4: Hair-on-end appearance of skull



**Figure 6**

Fig. 5: OPG showing thinning of lamina dura and loss of trabecular pattern



## DISCUSSION

Haemoglobinopathies represent a significant national health burden in India. The distribution of specific disorders varies geographically and by community.  $\beta$ -Thalassemia is the commonest single gene disorder in India. The carrier rate in different regions varies between 1% and 17%, with a mean of 3.3 %<sup>4,5</sup>. Based on this mean carrier frequency and the recent demographic profile of India (UNICEF 1996), it is estimated that there are 29.7 million carriers of  $\beta$ -thalassemia, while about 7000 affected infants are born every year<sup>4</sup>.

In this study the commonest manifestation observed was pallor of the mucosa, as has been stated in the literature<sup>3</sup>. Though the patients' age range from 6-15 years, most of them were in the first decade, which indicates a lack of life expectancy as has also been put forward by other authors<sup>3</sup>. The next common feature seen was malocclusion. This has also been documented by other authors. Malocclusion seen is basically caused by proliferation of marrow within the frontal and facial bones, resulting in hypertrophy of osseous structures and a consequent prominence of the lateral margins of malar eminences, together with anterior and medial displacement of the developing teeth. This in turn leads to clinically apparent proclination, spacing, etc<sup>2,6</sup>.

Dental caries and delayed eruption were also noted, though

in very few cases. No particular explanation could be given for these findings, though delayed eruption has been put forward in literature<sup>7</sup>. The radiographic features observed in this study are also found in various studies<sup>2,6,8</sup>.

## CONCLUSION

The study concluded that oral manifestations of thalassemia major; mucosal pallor and dental malocclusion in particular can be a useful pointer to prompt the clinician to suspect this disorder in undiagnosed cases. The results obtained in this study can not be extrapolated to general population due to the sample size constraint and should be interpreted with caution.

## ACKNOWLEDGEMENT

We are thankful to the staff of Department of Haematology and Blood Bank, Acharya Vinoba Bhave Rural Hospital, DMIMS, Wardha; Civil Hospital, Wardha, Civil Hospital, Chandrapur and IGMCI, Nagpur for giving us permission to use their archival records of the patients.

## References

1. Agarwal MB, Mehta BC. Genotypic analysis of symptomatic thalassemia syndromes (A study of 292 unrelated cases from Bombay). JPGM 1982; Vol.28 (1):1-3.
2. E.A. Alhaija et al. Cephalometric measurements and facial deformities in subjects with  $\beta$ -thalassemia major. Eur J of Orthodontics 2002; Vol.24:9-19
3. MR Salehi et al. Prevalence of Orofacial Complications in Iranian Patients with  $\beta$ -Thalassemia Major, Iranian J Publ Health 2007; Vol. 36(2):43-46
4. Ishwar C. Verma, Renu Saxena, Elizabeth Thomas, Pawan K. Jain. Regional distribution of  $\beta$ -thalassemia mutations in India. Hum. Genet. 1997; Vol.100: 109-113
5. D. Mohanty et al. Genetic Disorders in Haematological Practice in India. Community Genetics 2002; Vol. 5(3): 234-37
6. R. Rajendran, B. Sivapathasundaram. Diseases of blood and blood-forming organs. In: Shafer's textbook of Oral Pathology, 5th edition. Elsevier publications, 2007, pg. 1049-50
7. Abdalla Hazza. Dental Development in Subjects with Thalassemia Major. The Journal of Contemporary Dental Practice 2006; Vol. 7(4):80-83
8. Caffey et al. Thalassemia: Changes visible in radiographs used in dentistry. Oral Surg Oral Med Oral Pathol 1968; Vol. 25(4):564-76

**Author Information**

**Pratima Raju**

PG Student, Department of Oral Pathology and Microbiology, Sharad Pawar Dental College, Sawangi (M), Wardha, India

**Minal Chaudhary**

Professor, Guide and Head, Department of Oral Pathology and Microbiology, Sharad Pawar Dental College, Sawangi (M), Wardha, India

**Vijay Wadhwan**

Reader, Department of Oral Pathology and Microbiology, Sharad Pawar Dental College, Sawangi (M), Wardha, India