

# Unusual Presentation and Site of Small Bowel Perforation by Fish Bone: A Case Report

A A Mohamed, I S Bahurmoz, A A Mohamed

---

## Citation

A A Mohamed, I S Bahurmoz, A A Mohamed. *Unusual Presentation and Site of Small Bowel Perforation by Fish Bone: A Case Report*. The Internet Journal of Surgery. 2016 Volume 33 Number 1.

DOI: [10.5580/IJS.46113](https://doi.org/10.5580/IJS.46113)

## Abstract

Preoperative diagnosis of small bowel perforation by sharp foreign body is difficult because of its variable clinical presentation. We report a case of a 80 year old man who presented with delayed small bowel perforation caused by a fish bone 2 weeks after ingestion.

## INTRODUCTION

Although most of the ingested foreign bodies pass out spontaneously, bowel perforation is a known complication of ingested sharp foreign bodies. We report a case of small bowel perforation caused by fish bone with delayed clinical presentation and unusual site of perforation.

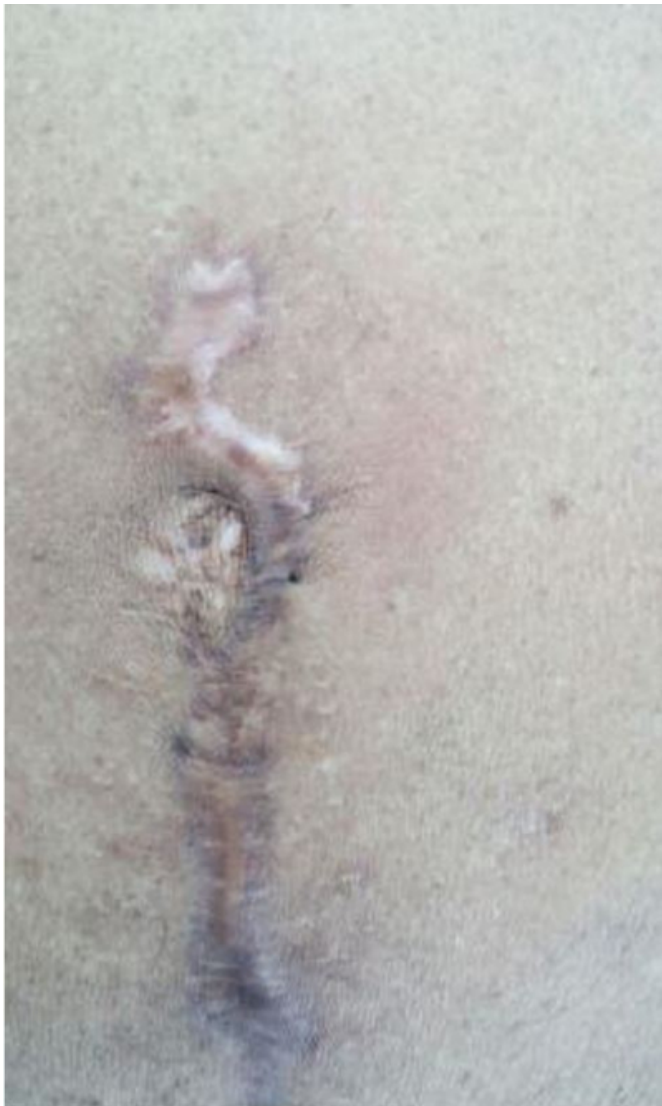## CASE REPORT

An 80 year old man presented to our emergency department complaining of sudden onset abdominal pain around the umbilicus of two days duration. The pain was initially sharp and stabbing in nature then became dull aching continuous

pain localized to the paraumbilical region. He had no vomiting or change of bowel habits. He was known to have hypertension on medical treatment and he had laparoscopic cholecystectomy 3 years ago and laparotomy for acute appendicitis with lower midline incision a year ago.

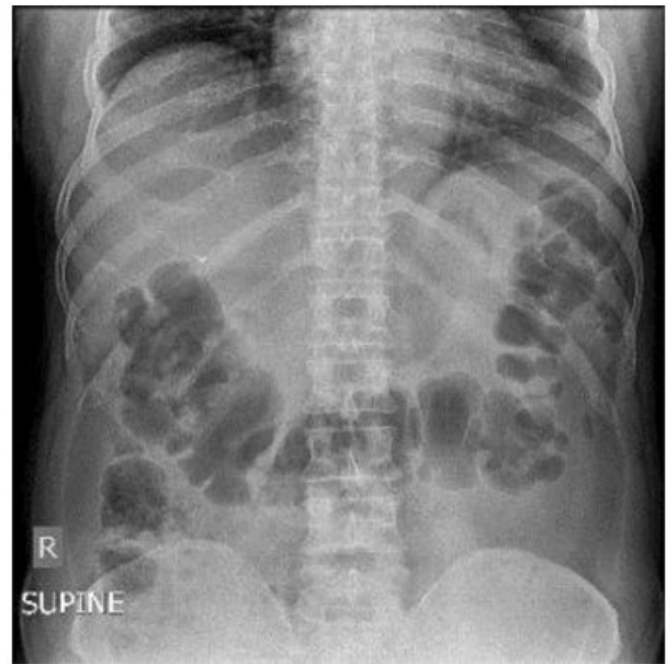
On clinical examination he looked well and was not in pain. Pulse was 86/minute, temperature of 38.7 °C, and BP was 160/96 mm of Hg. Abdominal examination revealed an area of redness and tenderness to the right of the umbilicus near the upper end of the laparotomy scar. There was no generalized abdominal tenderness or rigidity or others signs of peritonitis (Figure 1).

**Figure 1**

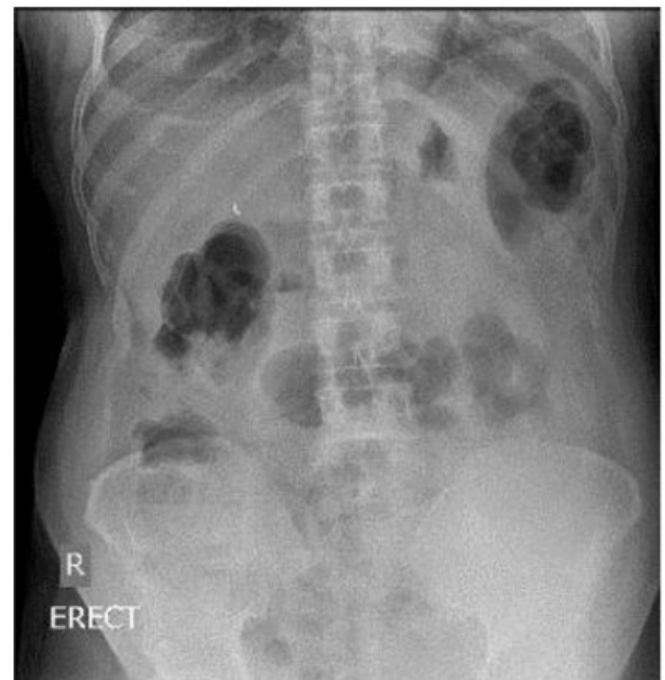

All laboratory investigations including CBC, urea and electrolytes and liver function test were within normal limits. The plain abdominal x ray showed no evidence of free air within the peritoneal cavity or radiopaque shadow apart from the clips related to the previous cholecystectomy (Figures 2 and 3).

**Figure 2**



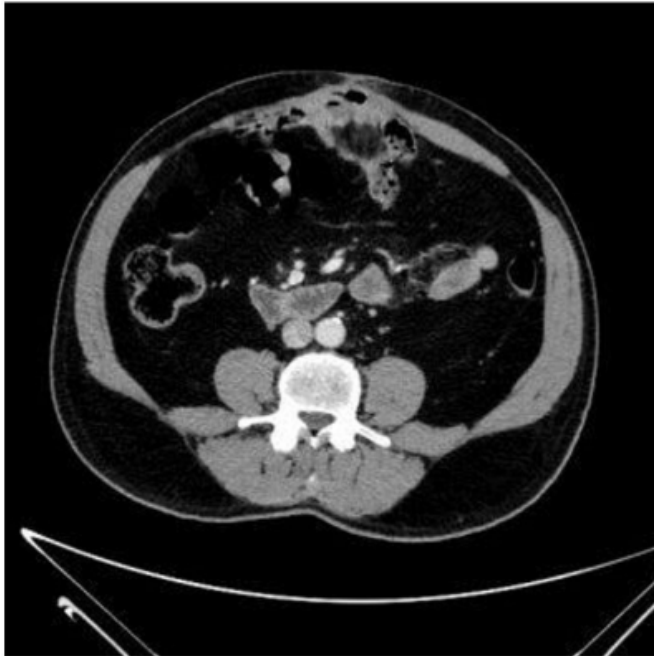**Figure 3**



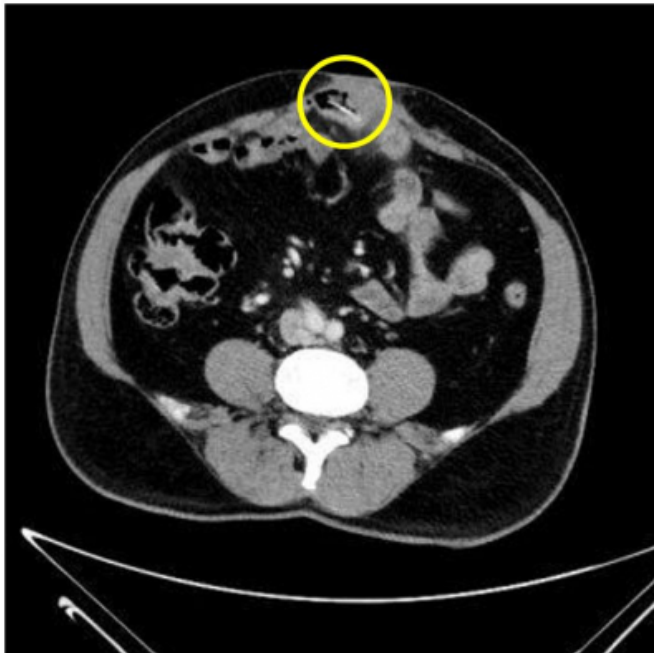
CT scan was requested to exclude deep seated abscess in the presence of the localized area of inflammation. The CT showed adhesion of the jejunal loop to the anterior abdominal wall along the scar with a 3.5 cm long hyper dense linear structure likely fish or chicken bone partly seen inside lumen of jejunum and its other end seen piercing the jejunal wall associated with inflammatory changes

particularly around site of penetration. No pneumoperitoneum or free collection identified (Figures 4, 5 and 6).

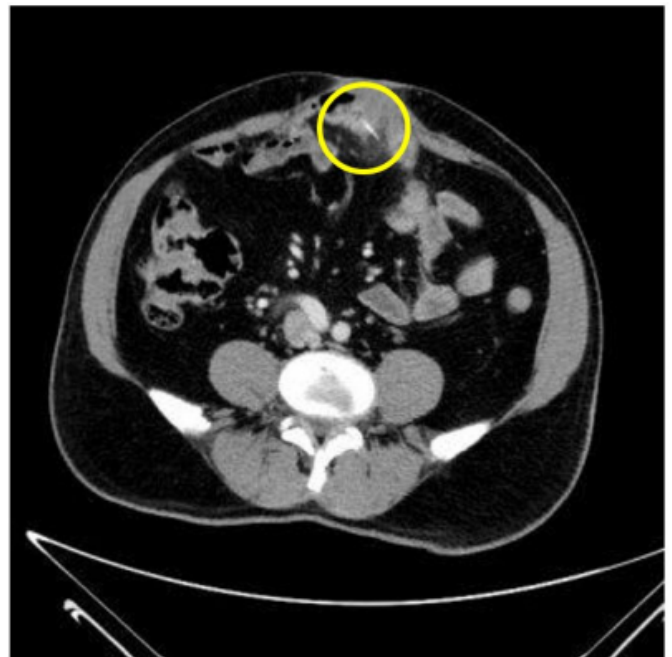**Figure 4**



**Figure 5**

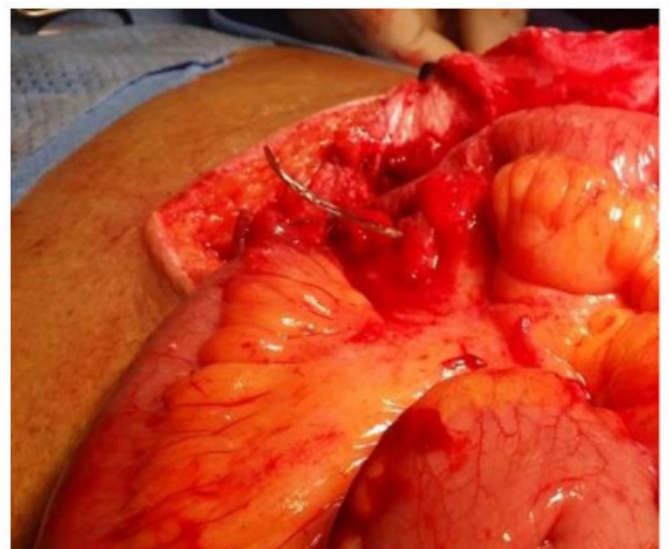


**Figure 6**



The patient had an emergency laparotomy through the same scar with extension of the wound superiorly. There was severe bowel adhesion to the anterior abdominal wall. The jejunal loops were carefully release from the anterior abdominal wall. A fish bone was found perforating the jejunum proximal to the site of adhesion. The bowel around the perforation was found to be inflamed and ugly looking. The fish bone was grasped and pulled through the bowel wall. The inflamed bowel was resected and the continuity of the bowel was restored by side to side anastomosis (Figures 7 and 8).

**Figure 7**



**Figure 8**



## DISCUSSION

Ingestion of foreign bodies is a common presentation to emergency departments. Although most of the ingested foreign bodies pass out spontaneously, bowel perforation is a known complication of ingested sharp foreign bodies. 90% of foreign bodies pass through the intestine if they reach the stomach with only a few causing impaction and severe complications (1). Perforation of the gastrointestinal tract by ingested foreign bodies is uncommon and less than 1% of ingested foreign bodies perforate the bowel (2). Accidentally ingested fish bones are the most common foreign bodies to cause gastrointestinal tract perforation due to their sharp ends and elongated shape (3).

Although perforation of the bowel by sharp foreign bodies can happen anywhere along the intestinal tract, it tends to occur particularly at the angulating regions such as ileocecal and recto-sigmoid junctions (4, 5, and 6).

Pinero Madrona et al studied 21 cases of bowel perforations with foreign bodies they reported that the most common location was the terminal ileum (52.3%), followed by the recto-sigmoid junction (23.8%) (7). Perforation of the jejunum, as occurred in our case, is relatively uncommon and has a reported incidence of approximately 14.3 % (3). In our case most probably the angulation created by the adhesion of the bowel to the anterior abdominal wall at the site of the perforation was the main predisposing factor for the perforation and its uncommon site. Bernard B et al

reported a similar case of jejunal perforation by a fish bone where the perforation at laparotomy was found above several loops of small bowel densely adhered to the nonabsorbable intra-abdominal mesh (10).

Preoperative diagnosis of small bowel perforation by sharp foreign body is difficult because of its variable clinical presentations and failure of the most patients to recall the incident of the foreign body ingestion. Variable pictures of clinical presentation were reported including acute and chronic pain, bowel obstruction and abscess and fistula formation (9, 10). Our patient presented with abdominal wall cellulitis most probably due to localization of the infection by the adhesion of bowel to the anterior abdominal wall at the site of the perforation.

Plain abdominal radiography is not helpful in the preoperative diagnosis of fish bone perforation of the bowel, as most fish bones don't contain enough calcium to show in x rays and the perforation is almost always so tiny to cause free air in the peritoneal cavity or under the diaphragm.

Computed tomography, especially multidetector CT, is considered the method of choice for preoperative diagnoses of ingested foreign bodies and their complications due to its high-quality multiplanar capabilities and high resolution (4-11, 12).

## SUMMARY

Accidentally ingested fish bones are the most common foreign bodies to cause gastrointestinal tract perforation due to their sharp ends and elongated shape. Although perforation of the bowel by fish bone can happen anywhere along the intestinal tract, it tends to occur particularly at the angulating regions such as ileocecal and recto-sigmoid junctions. Perforation of the jejunum is relatively uncommon but can occur especially in presence of bowel adhesion. Preoperative diagnosis is difficult because of its variable clinical presentations and failure of most patients to recall the incident of the fish bone ingestion. Multidetector CT is the method of choice for preoperative diagnosis.

## References

1. Earlam E. Clinical tests of oesophageal function. *BMJ*. 1976;1080-1081.
2. Hsu S-D, Chan D-C, Liu Y-C. Small-bowel perforation caused by fish bone. *World Journal of Gastroenterology*: WJG. 2005; 11(12):1884-1885.
3. Goh BK, Tan YM, Lin SE, et al. CT in the preoperative diagnosis of fish bone perforation of the gastrointestinal tract. *AJR Am J Roentgenol* 2006;187:710-4.
4. Coulier B., Tancredi M.H., Ramboux A. Spiral CT and multidetector-row CT diagnosis of perforation of the small

intestine caused by ingested foreign bodies. *EurRadiol.* 2004;14:1918–1925.

5. Maleki M., Evans W.E. Foreign – body perforation of the intestinal tract; report of 12 cases and review of the literature. *Arch Surg.* 1970;101:474–477.

6. Brian K.P., Goh B.K., Chow P.K. Perforation of the gastrointestinal tract secondary to ingestion of foreign bodies. *World J Surg.* 2006;30:372–377.

7. Pinero M.A., Fernandez J.A., Carrasco P.M., Riguelme R.J., Parrilla P.P. Intestinal perforation by foreign bodies. *Eur J Surg.* 2000;166:307–309.

8 .Bernard B, Mhanna T, Dugas B, Gasquez P, Valette PJ, Marx P, Sauvage P, Naouri A, Odet E, Bernard P. [Jejunal perforation by a fish bone diagnosed by CT-Scan:report of

two cases]. *Ann Chir.* 2005 Dec; 130(10):636-9.

9-Pulat, Huseyin et al. “Small Bowel Perforation due to Fish Bone: A Case Report.” *Turkish Journal of Emergency Medicine* 15.3 (2015): 136–138.

10. Webb WA. Management of foreign bodies of the upper gastrointestinal tract: update. *GastrointestEndosc.* 1995;41:39–51.

11. Akhtar S, McElvanna N, Gardiner KR, Irwin ST. Bowel perforation caused by swallowed chicken bones: a case series. *Ulster Med J* 2007;76:37-8.

12. Takada M, Kashiwagi R, Sakane M, Tabata F, Kuroda Y. 3D-CT diagnosis for ingested foreign bodies. *Am J Emerg Med* 2000; 18:192-3.

**Author Information**

**Abbas AR Mohamed, MBBS, FRCSI, FICS, FACS**

Consultant General and Laparoscopic Surgeon, Head of General Surgery Department  
NGH, Madinah, KSA

**Idrees S Bahurmoz, MBBS**

Staff grade surgeon, Department of Surgical Specialties  
NGH, Madinah, KSA

**AbdelRahaman A Mohamed, MBBS**

Staff grade physician, Department of Medicine,  
NGH, Madinah, KSA