

Hydatid Disease of the Spleen

K Vagholkar, S Nair, B Patel, K Dastoor, O Joglekar, S Nachane, S Rambhia

Citation

K Vagholkar, S Nair, B Patel, K Dastoor, O Joglekar, S Nachane, S Rambhia. *Hydatid Disease of the Spleen*. The Internet Journal of Surgery. 2010 Volume 27 Number 1.

Abstract

Hydatid disease is a common parasitic infestation seen in rural settings of agricultural countries. The disease has a predilection for the liver and lung. Splenic disease is quite uncommon. The clinical presentation may either be due to splenomegaly or complications arising from long-standing large hydatid cysts. Diagnosis can be confirmed by CT scan. Splenectomy, preferably by open method, is the treatment of choice for splenic hydatid cyst.

INTRODUCTION

Hydatid cyst is a parasitic infestation caused by *Echinococcus granulosus*. It is disease which is seen in countries where animal husbandry is a major occupation. Man is an accidental host in the life cycle of the parasite. The disease usually affects the liver in most of the cases or could be disseminated involving other organ systems such as the lungs, kidney, brain or peritoneum. Primary isolated hydatid cyst of the spleen is a rare occurrence. A case of primary isolated hydatid cyst of the spleen is reported along with a brief review of literature.

CASE REPORT

A 37-year-old female presented with history of upper abdominal pain since two months. The pain was dull aching in nature and located in the left hypochondrium. It was aggravated with exertion. There was no history of gastrointestinal or renal symptoms. Physical examination did not reveal any tenderness on superficial or deep palpation of any of the quadrants. The spleen and liver were impalpable. Hematological investigations did not reveal any abnormality. Ultrasonography of the abdomen showed a cystic space-occupying lesion in the spleen. To confirm the diagnosis, a CT scan of the abdomen was performed. This revealed a large cyst in the spleen (Figure 1). The cyst had internal septations and showed daughter cysts confirming the diagnosis of hydatid cyst of the spleen. There was no involvement of the liver, kidney or peritoneum. The chest was uninvolved. The patient underwent elective open splenectomy after being prepared by vaccination against meningococcal, pneumococcal and H influenzae organisms. Intraoperative findings were an enlarged spleen with the cyst

projecting to the surface. There were flimsy adhesions to the parietal wall which could be separated easily. The diaphragm was not involved. Liver, colon and the left kidney were normal. There was no evidence of dilated vessels in the vicinity of the spleen suggestive of portal hypertension. Splenectomy was done taking utmost care to prevent rupture of the cyst (Figure 2). The postoperative course of the patient was uneventful with no complications specific to splenectomy such as pulmonary, gastric, hematological or septic ones in the form of OPSI. The patient was advised a course of albendazole post-operatively.

Figure 1

Figure 1. CT scan showing the cyst in the spleen with internal septations.

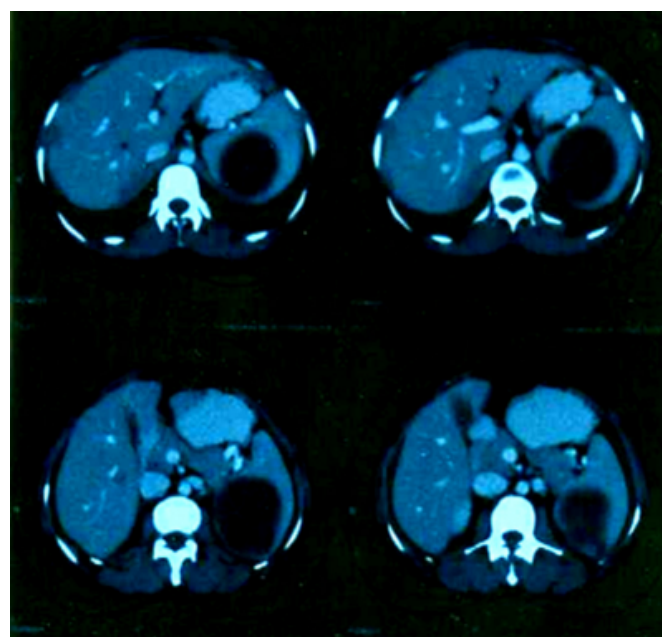


Figure 2

Figure 2. Specimen of spleen removed showing the intact cyst wall reaching the surface.

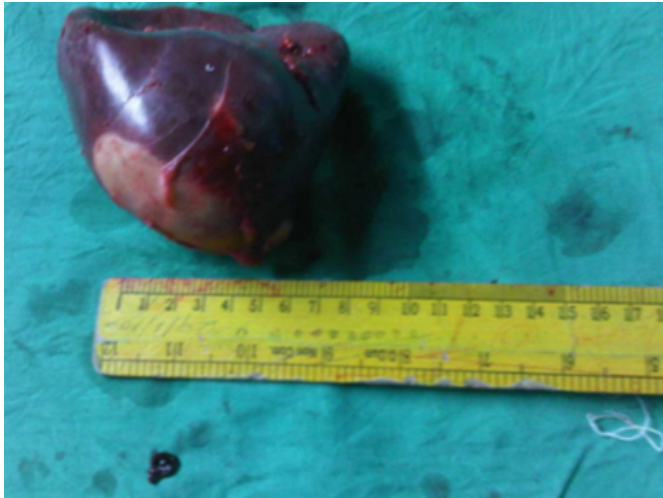
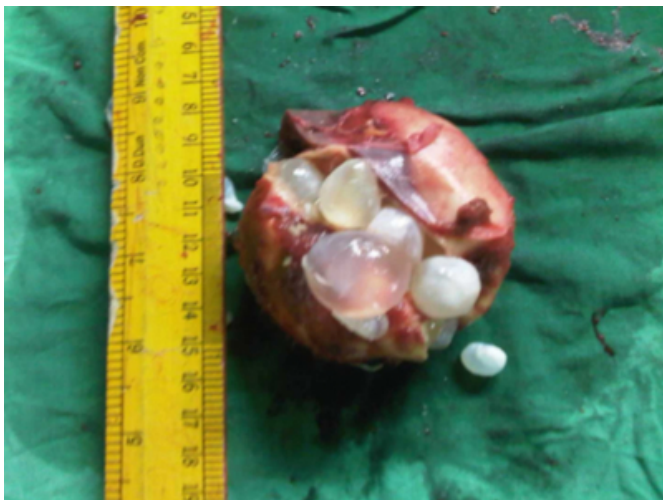

Figure 3

Figure 3. Specimen cut open showing daughter cysts typical of hydatid disease



DISCUSSION

Hydatid disease is caused by the parasite *Echinococcus granulosus*. Man is the accidental host. Canine animals such as dogs and foxes are the definitive hosts. The eggs are usually passed in the faeces of infected animals which may be consumed by grazing herbivorous animals such as sheep and cattle which are intermediate hosts. The parasites develop in the intestines of the intermediate host and may localize in various organ systems of the intermediate host. Consumption of infected flesh of these animals causes disease in humans. The cyst typically has three layers; the pericyst which is compressed surrounding parenchyma of the host organ; the ectocyst, the middle layer, which is part

of the proper cyst and the inner endocyst to which is attached the germinal layer which secretes hydatid fluid and forms the infective components namely scolices. The hydatid fluid within the cysts contains hydatid sand comprised of salts and scolices. It is highly infective and can precipitate an anaphylactic reaction. Hence, sterilizing the cyst prior to aspiration in case of liver hydatids and avoidance of rupture in splenic and lung hydatids is mandatory.

Primary infestation of the spleen is uncommon with a reported incidence of 0.5-3%. Barlot was the first to describe splenic hydatid disease at autopsy. [1] Primary infestation is usually by the arterial route after having gone through two filtering systems namely the liver and lungs. Secondary involvement of spleen follows dissemination following rupture of a large hepatic hydatid cyst. [2,3]

A hydatid cyst of the spleen could present in a variety of ways. This depends upon the size, location and duration of the disease. If the size of the cyst is small, it will not cause significant splenomegaly and therefore will remain silent for quite some time. As the size increases gradually over time the spleen will enlarge causing pain due to traction on the splenic pedicle.

When the cyst assumes a very large size it will invade and involve the adjacent structures such as the diaphragm, stomach, colon and kidney. It can penetrate the diaphragm and invade the thoracic cavity to involve the lung. [4] Presenting symptoms will then depend upon the organs involved by extension. [5]

There are no laboratory investigations which can confirm the diagnosis of hydatid cyst. Serological tests which were routinely performed in the past were supportive but not confirmatory. Imaging methods of USG and CT scanning have revolutionized the diagnosis of hydatid disease. [6] USG will give an approximate idea of the extent of the disease while CT scan will confirm the diagnosis. CT scan will furnish all the details which are required to plan the surgical course of treatment viz. location of the cyst, number of cysts, size of the cyst, adherence or involvement of other abdominal organs. Presence of internal septations and daughter cysts within the cyst is confirmatory for hydatid cyst. (Figure 3)

Surgery is the treatment of choice for hydatid cysts. [3,7] In case of hepatic hydatids, no attempt is made to perform pericystectomy as this can cause torrential life-threatening

bleeding intraoperatively. Hence enucleation of the cyst after sterilizing it with either hypertonic saline or freshly prepared silver nitrate solution is done [7], whereas in splenic hydatid disease splenectomy removes the cyst completely. [7] This can be done laparoscopically or by open method. The laparoscopic approach is best suited for small cysts. [8] For larger lesions causing splenomegaly with the cyst pointing to the surface, the chances of rupture are high. Hence, it is prudent to go in for an open approach as the organ can be carefully separated from the surroundings without rupturing the cyst. If the laparoscopic approach is to be used successfully, retrieval of the spleen should be done exclusively using an endocatch bag after having made an adequate incision to deliver the specimen in order to prevent rupture and spillage of daughter cysts. Hand assisted laparoscopic technique is a preferred method.[9] Rupture of the cyst in the peritoneal cavity during the course of surgery can cause a fatal anaphylactic reaction or seeding of the peritoneal cavity with small daughter cysts which may evade the surgeon's view. (Figure 3)

The open method is safe and allows better dissection of the organ under vision. Better isolation can be achieved during an open procedure in the event of an accidental rupture taking place as compared to the laparoscopic approach.

Dissecting the spleen from adjacent viscera, especially the diaphragm, is much easier by the open method. Any further repair for the adjacent organ can be done meticulously.

Proper precautions with respect to vaccinations against pneumococcus, meningococcus and *H. influenzae* coupled with a course of antibiotic prophylaxis helps significantly to reduce the incidence of septicaemia (OPSI). In elective cases, vaccinations should be given 14 days prior to surgery to allow a good antibody response to develop at the time of surgery.[10]

A course of albendazole or praziquantel is given for a period of one month after surgery. The rationale is to prevent growth of new cysts (if at all they are concomitantly present in distant sites) which may not be picked up by imaging prior to surgery; however, these drugs have no effect on cysts which are already formed as the penetration across the cyst wall is very poor.

ACKNOWLEDGEMENT

We would like to thank the Dr. Bhaskar, Medical Superintendent of Rajawadi Municipal General Hospital Ghatkopar, Mumbai 400077, Maharashtra State, India, for allowing us to publish this case report.

References

1. Muro J, Ortiz-Vazquez J, Mino G, Sanmartin P: Demonstration angiografica del quiste hidatidico de bazo. *Rev Clin Esp*; 1969; 115: 433-38.
2. Uriate C, Pomares N, Martin M, Conde A, Alonso N, Bueno A: Splenic hydatidosis. *Am J Trop Med Hyg*; 1991; 44: 420-3.
3. Ionesu A, Jakab A, Jutis T, Forai F, Ota A: Splenic Hydatid cyst. *Rev Med Chir Soc Med Nat Lasi*; 1990; 94: 528-9.
4. Barzilai A, Poack S, Kafton JK, Sourday M, Barzilai D: Splenic echinococcal cyst burrowing into left pleural space. *Chest*; 1977; 72(4): 543-45.
5. Quereshi MA, Haffner CD: Clinical Manifestations of splenic cysts, study of 75 cases. *Am Surg*; 1965; 31: 605-9.
6. Von Sinner WN, Strideback H: Hydatid disease of the spleen. *Ultrasonography, CT and MR imaging. Acta Radiol*; 1992; 33(5): 459-61.
7. Kune GA, Morris DI: Hydatid disease. In Schwartz & Ellis, editors. *Maingot's Abdominal Operations*, 9th Edition. Appleton & Lange; 1989; 1225-40.
8. Khoury G, Abiad F, Geagea T, Nabiout G, Jabbour A: Laparoscopic treatment of hydatid cysts of liver and spleen. *Surg Endosc*; 2000; 14: 243-4.
9. Ballanx KE, Himpens JM, Leman G, Van den Bossche MR: Hand assisted laparoscopic splenectomy for hydatid cyst. *Surg Endosc*; 1997; 11(9): 942-43.
10. Holdsworth RJ, Irving AD, Cushieri A: Postsplenectomy sepsis and its mortality rate: actual versus perceived risks. *Br J Surg*; 1991; 78: 1031-8.

Author Information

Ketan Vagholkar, MS, DNB, MRCS, FACS.

Professor, Department of Surgery, Padmashree Dr. D. Y. Patil Medical College

Shalini Nair, MS

Associate Professor, Department of Surgery, Padmashree Dr. D. Y. Patil Medical College

Bhavin Patel, MS

Assistant Professor, Department of Surgery, Padmashree Dr. D. Y. Patil Medical College

Khojasteh Dastoor, MBBS

Registrar, Department of Surgery, Padmashree Dr. D. Y. Patil Medical College

Omkar Joglekar, MBBS

Senior Resident, Department of Surgery, Padmashree Dr. D. Y. Patil Medical College

Siddharth Nachane, MBBS

Senior Resident, Department of Surgery, Padmashree Dr. D. Y. Patil Medical College

Samir Rambhia, MBBS

Junior Resident, Department of Surgery, Padmashree Dr. D. Y. Patil Medical College