

Thrombosed Varix Of The External Jugular Vein: Diagnostic Considerations

V Naraynsingh, M Ramdass

Citation

V Naraynsingh, M Ramdass. *Thrombosed Varix Of The External Jugular Vein: Diagnostic Considerations*. The Internet Journal of Dermatology. 2010 Volume 8 Number 2.

Abstract

This is the case of a middle-aged male presenting with a lump over the external jugular vein region of the neck. The clinical differential diagnosis included a sebaceous cyst or lipoma, however it remarkably turned out to be a thrombosed varix of the external jugular vein. We advise caution and proper history taking to avoid potential catastrophic complications with bleeding when such a lump presents in close proximity to the external jugular vein.

CASE REPORT

A 57-year old male patient of Afro-Trinidadian descent presented with a swelling on the left side of his neck for approximately 2-years. The lump was located in the posterior triangle and bulged-out on shouting or singing, then reduced spontaneously.

One week prior to presentation the lump became hard, tender and swollen. It did not reduce spontaneously. On clinical examination, there was a 2cm lump in diameter, firm consistency, had limited mobility in all planes, not attached to skin and located in the posterior triangle and posterior to the external jugular vein (implying the external jugular vein was not thrombosed). There was no history of trauma or venous cannulation.

At operation, a thrombosed varix of the external jugular vein was found [Figures 1 and 2 and excised with ligation of the proximal and distal ends of the vein with 2.0 Vicryl sutures.

Figure 1

Figure 1: Varix of External Jugular Vein showing external jugular vein with instrument in the lumen

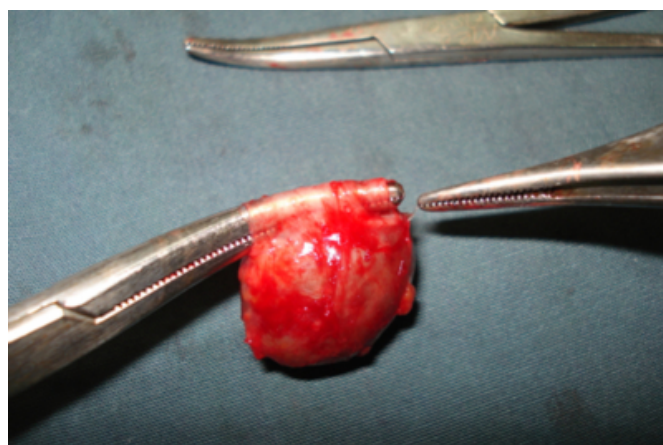
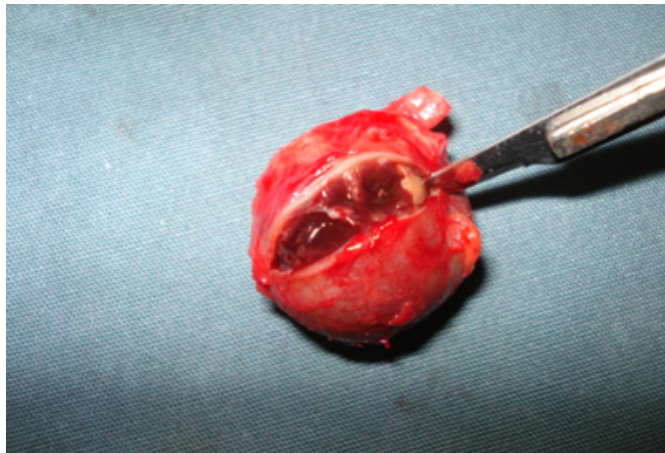


Figure 2

Figure 2: Varix of External Jugular Vein with thrombus within the varix.



Varices of the external jugular vein have been extensively

reported in the literature with many case series and complications. The differentials include a sebaceous cyst and lipoma. There is always a risk of bleeding if one approaches such a lump without possible awareness of an external jugular varix.

We advise caution and proper history taking to avoid potential catastrophic complications with bleeding when such a lump presents in close proximity to the external jugular vein.

References

1. Wieringa JW, van Houten MA. Case 2: A crying patient with a swelling in the neck. Phlebectasia of the external jugular vein. *Acta Paediatr.* 2008 Dec; 97(12):1603.
2. Ajuluchuku EU, Da-Rocha Afodu JT, Bode C, Adebajo AK, Elesha SO. Varix of the external jugular vein. *Thorac Cardiovasc Surg.* 1986 Apr; 34(2):135-6.
3. Nocito FJ, Quiros RS. Varices of the external jugular. *Bol Trab Soc Cir B Aires.* 1963 Sep 25;47:595-600.

Author Information

Vijay Naraynsingh, FRCS

Professor of Surgery, Department of Clinical Surgical Sciences, University of the West Indies

Michael J. Ramdass, FRCS

Lecturer/ Consultant Surgeon, Department of Clinical Surgical Sciences, University of the West Indies