

Diagnosis Of Leg Ulcers

A Khachemoune, C Kauffman

Citation

A Khachemoune, C Kauffman. *Diagnosis Of Leg Ulcers*. The Internet Journal of Dermatology. 2001 Volume 1 Number 2.

DOI: [10.5580/64d](https://doi.org/10.5580/64d)

Abstract

In the United States, leg ulcers present a significant clinical problem, occurring at a rate of approximately 600,000 new cases per year. (1) The most common types are venous, arterial, and neuropathic ulcers. Venous hypertension is the primary culprit in venous ulcerations. Peripheral vascular disease due to atherosclerosis with microvascular or macrovascular changes leads to ischemic ulcers. Sensory impairment with loss of protective sensation in the foot and repetitive trauma lead to neuropathic ulcers. Unusual causes of leg ulcers must be considered in the differential diagnosis. To arrive at the diagnosis, the clinician must perform a thorough history and physical examination, and order relevant investigative studies. Good management of chronic leg ulcers depends on correction of identified underlying conditions, long-term multidisciplinary care effort, and integrating traditional and new wound-healing technologies. Most patients with chronic leg ulcers benefit from the use of compression bandaging at a level appropriate to their vascular status. Venous ulcers must be managed with an arsenal of strategies to control venous insufficiency, heal the wound, and prevent recurrence. Surgery with revascularization remains the treatment of choice for chronic ischemic leg ulcers. In the absence of vascular compromise, up to 90 percent of neuropathic ulcers will heal with proper ulcer debridement, treatment of infection, saline wet-to-dry dressings, and relief of weight from the ulcerated area. The available armamentarium for wound care includes over 2000 wound dressing products and elastic compression wraps. Chronic leg ulcer treatment options have been expanded by alternatives available to treating these wounds. These alternatives include hyperbaric oxygen therapy, bioengineered skin substitutes, recombinant platelet-derived growth factors and vacuum assisted wound closure. Patients with large leg ulcers may benefit from skin grafting. Other patients may benefit from ligation and stripping of superficial veins or subfascial interruption of perforating veins.

VENOUS ULCERS

Venous ulcers represent up to 80% of all lower extremity ulcers.(2) Venous ulcers develop slowly. Symptoms may include aching, heaviness, leg-tiredness, cramps, itching, burning, and swelling. These symptoms often worsen with prolonged standing and improve with leg elevation.

When taking the medical history, special attention should be paid to the duration, location and previous history of the ulcers. A history of long duration varicose veins, and/or deep venous thrombosis (DVT) is often present. Acquired and genetic factors known to increase the risk for DVT formation are summarized in table 1. (3) Other causes of venous ulcers include neoplastic obstruction, congenital or acquired arteriovenous fistulae.

Figure 1

Table 1: Acquired and Genetic Risk Factors for Venous Thrombosis

Acquired	Genetic
<ul style="list-style-type: none">• Surgery• Trauma• Immobilization• Obesity• Pregnancy• Nephrotic syndrome• Cancer• Oral contraception• Hormone-replacement therapy• Antiphospholipid antibody syndromes*• Hyperhomocysteinemia	<ul style="list-style-type: none">• Factor V Leiden *• Prothrombin G20210A mutation*• Antithrombin deficiency*• Protein S deficiency*• Protein C deficiency *• Hyperhomocysteinemia*

From: Ridker, PM. Inherited risk factors for venous thromboembolism: implications for clinical practice. Clin Cornerstone. 2000;2(4):1-14

* Laboratory screening for these factors may be appropriate in patients with the history of recurrent deep venous thrombosis (DVT).

On physical examination, venous ulcers are usually located

in the malleolar area. (Picture 1) A typical venous ulcer is usually superficial with irregular or shaggy borders. The drainage is often moderate to heavy. There is often presence of fibrinous material at the ulcer bed. (Table 2) Other findings may include telangiectasia, reticular or varicose veins, edema, and hyperpigmentation, lipodermatosclerosis, venous stasis dermatitis, and atrophie blanche.

Figure 2

Picture 1: Typical venous ulcer, located at the internal malleolus

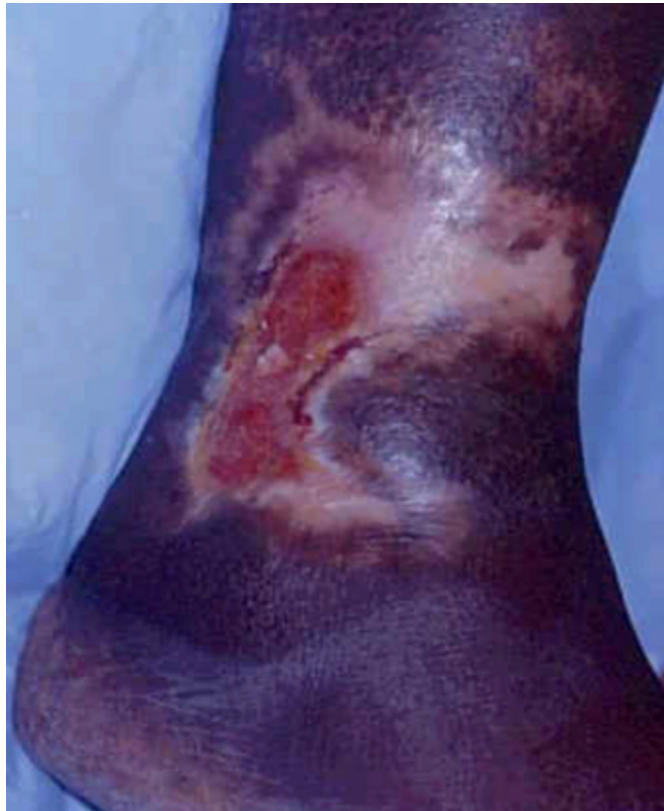

Figure 3

Table 2: Main characteristics of venous, arterial and neuropathic leg ulcers

	Venous ulcer	Arterial ulcer	Neuropathic
History	Past history of varicose veins +/- DVT, trauma, surgery to leg, or multiple pregnancies. Aching and swelling worse at end of day—relieved with leg elevation.	History of smoking, intermittent claudication. Painful, especially after exertion and leg elevation.	History of numbness, paresthesias, burning. Loss of sensation in the foot. Common in patients with diabetes mellitus.
Location	Between the malleolus and the lower calf. Majority of venous ulcers are located over the medial malleolus.	Frequently occurs distally and over bony prominences.	Sites of pressure (eg, metatarsal heads, heels, toes).
Ulcer bed	Fibrinous material at the ulcer bed with moderate to heavy exudate.	Dry necrotic base.	Variable depth partial thickness to severe ulcer involving tendon, fascia, joint capsule or the bone itself.
Appearance	Shallow, irregular margins. They can vary from small to nearly encircling the leg. Margins are either flat or have a slight steep elevation.	Round or punched out with a sharply demarcated border.	Surrounding callus. May be sinus track formation. Prolonged bacterial infection may be associated with underlying osteomyelitis.
Capillary refilling time	Normal (<3 seconds)	A prolonged capillary refilling time (>4.5 seconds)	Normal if no associated arterial disease.
Surrounding skin	Pigmented (hem siderin deposition), edema, atrophie blanche (white scar formation), indurated (lipodermatosclerosis).	Pale, loss of hair, shiny and atrophic skin, cool feet, weak or absent dorsalis pedis pulse.	Frequently callused.
ABI* measured by Doppler ultrasonography	Normal. An ABI of 0.9 or higher is normal.	ABI of 0.5 or less indicates severe arterial disease.	Normal if no associated arterial disease.

*ABI: (ankle/brachial index):The ankle-to-brachial blood pressure ratio.

PATHOPHYSIOLOGY OF VENOUS ULCERS

Venous hypertension in both the superficial and deep venous systems may be due to one or a combination of the following causes: valve dysfunction, venous obstruction (e.g., DVT), and failure of calf muscle pump function. The mechanism of ulceration in patients with venous insufficiency is unclear. Pericapillary fibrin cuff formation, trapping of white blood cells and growth factors have been proposed as possible mechanisms of ulcerations. (4) Trapping of leukocytes within the microcirculation leads to their subsequent activation. Endothelial cells, presumably activated by hypoxia or other causes, stimulate adherence of leukocytes. The activated leukocytes then release toxic products, with subsequent surrounding tissue injury.

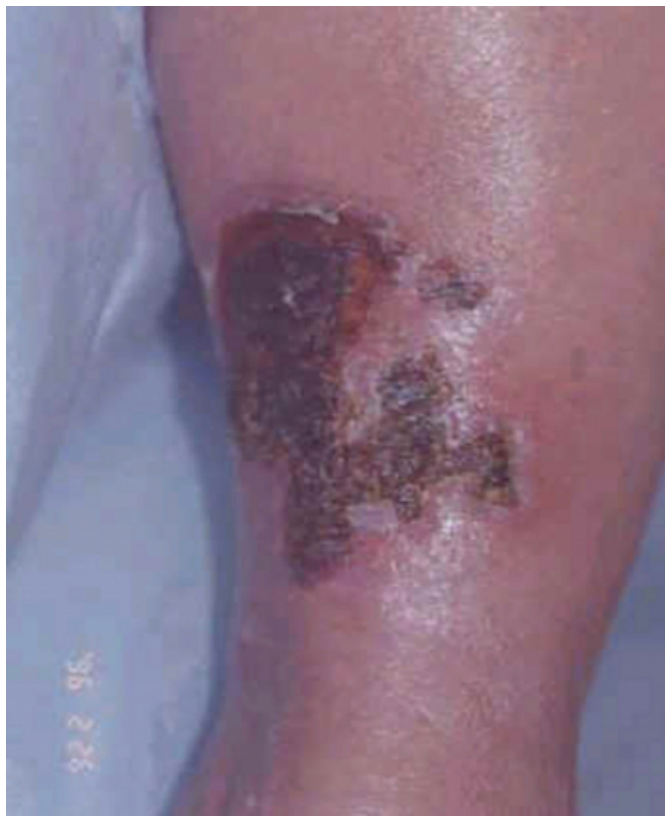ARTERIAL ULCERS

Arterial ulcers are most worrisome, because of the threat of limb loss. The frequent involvement of the coronary arteries

with atherosclerosis is also of concern. Arterial ulcers often affect the toes or shin or occur over pressure points (Picture 2). Arterial ulcers are often seen in elderly. These patients often present with a history of intermittent claudication or a rest pain, which is usually relieved by dependent position. Some patients report that in order to ease the pain to their limbs they have to sit on the edge of the bed and dangle their legs. The patient medical history is often positive for smoking and other risk factors for atherosclerosis like hypertension, hyperlipidemia, and diabetes. A history of minor trauma to the leg initiating the ulcer is frequently reported.

Figure 4

Picture 2: Necrotic leg ulcer (arterial) located at the shin area



On physical examination, the ulcers usually are located on bony prominences. A typical arterial ulcer is deep and has circular or well-demarcated “punched out” margins. The ulcer base is covered with a black, dry necrotic material with minimal or poor granulation tissue. Other findings include weak or absent peripheral pulses, dependent rubor and elevational pallor of the foot, and thickened nails. The skin of the affected leg is often shiny, atrophic, dry, and cold to the touch. Examination of the leg should include palpation of pulses, and determination of range of hip, knee, and ankle movements. Involvement of these articulations with an

inflammatory process may explain the pain, which should be differentiated from pain caused by arterial insufficiency.

Reduced mobility from arthritis is a factor that is known to prevent healing of ulcers. (5) Also calf muscle pump failure due to musculoskeletal deficiency is often overlooked as a component of venous, as well as mixed arterial and venous ulcers. Arterial ulcers are mainly due to atherosclerosis of large vessels.

NEUROPATHIC ULCER

Diabetics are more prone to develop neuropathic ulcers. Vascular changes are also common causes of diabetic foot ulcers, and both conditions may be present in the same patient. Sensory neuropathy often leads to a loss of protective sensation. Motor neuropathy leading to small muscle wasting leads to an imbalance between flexors and extensors of the lower limb, causing clawing of toes and prominence of the metatarsal heads, thus providing appropriate conditions for ulceration. (6,7) Sympathetic autonomic neuropathy leads to dry, cracked, and fissured skin over the lower leg. (8) Rarer conditions responsible for neuropathic ulcers include chronic alcoholism with malnutrition, leprosy, tabes dorsalis, spina bifida, and syringomyelia. (6,8)

Location is important in evaluating the cause of a neuropathic foot ulcer. Usually, plantar ulcers are the result of moderate repetitive trauma underneath a metatarsal head. Medial, lateral, and digital ulcers are often the result of pressure from shoes overlying such osseous abnormalities as bunions and hammertoes. (7,9,10) (Pictures 3, 4, and 5)

Figure 5

Picture 3: Foot ulcer in a diabetic patient—note the thick callus surrounding the ulcer

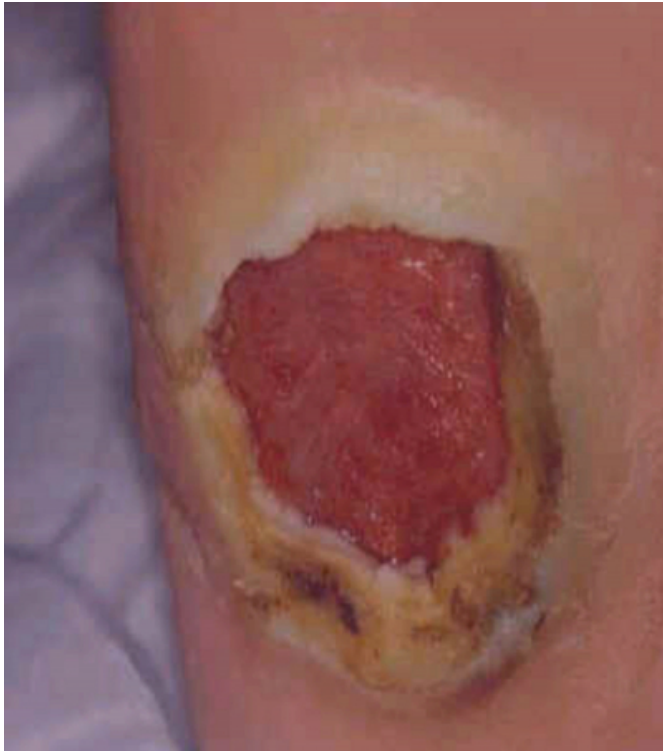

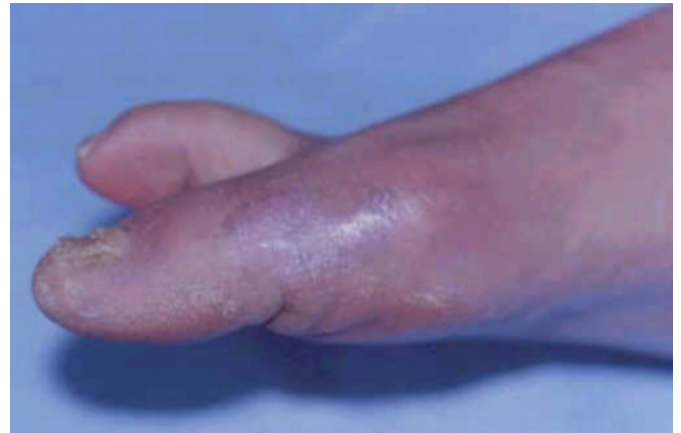
Figure 6

Picture 4: Toe ulcer in a diabetic patient with neuropathy.

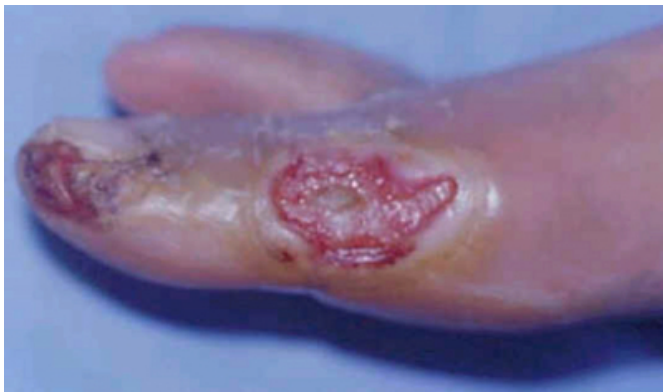

Figure 7

Picture 5: Same patient in picture 4, three months after a weekly dressing change and use of appropriate shoes as recommended by a podiatrist



In patients with ulcers on the sole of the foot, the sole should be examined for signs of ascending infection, including proximal tenderness and appearance of pus on proximal compression of the sole. Surrounding calluses are typical of neuropathic ulcerations, and sinus track formation should be explored by probing the wounds. (7)

Determining the point at which loss of protective sensation develops, and thus the risk of injury increases, is important. The loss of protective sensation is defined as the inability to perceive testing with a 5.07 Semmes-Weinstein monofilament (SWM) standardized to deliver a 10-g force. (11) The SWM is pressed against the skin to the point of buckling. Measurements are usually taken at each of 10 sites on the foot annually. (11) Inability to perceive 4 or more sites is associated with a higher risk of loss of sensation and concomitant risk of ulceration. (11,12) A simplified monofilament examination using only 4 sites per foot (total 8 sites) has been used. (13)

Less common causes of leg ulcers have a wide range of etiologies. Investigation and management of such types of ulcers vary with the underlying causes and often need a multidisciplinary team including a wound specialist.

INITIAL ASSESMENT OF PATIENTS WITH LEG ULCERS

Most of the information about the etiology of leg ulcers is obtained from the patient's history and physical examination. If arterial insufficiency is suspected, with the use of a hand-held Doppler the physician can assess the arterial system in the lower extremities. The ankle brachial index (ABI) is determined by dividing the ankle systolic

pressure by the brachial systolic pressure obtained at the same time. This will provide an objective estimate of arterial insufficiency, and will help in making the decision as to whether compression therapy is appropriate. The ABI of a normal artery ranges from 0.9 to 1.2.

Initial laboratory investigations may include a complete blood cell count (to rule out underlying hematologic disorders), erythrocyte sedimentation rate (which is elevated in patients with many diseases including connective tissue diseases and associated vasculitic ulcers, and infectious processes), and a fasting blood glucose. Serum albumin and transferrin levels are very helpful in assessing the nutritional status in elderly patients.

INVESTIGATING LEG ULCERS

NON-INVASIVE INVESTIGATIONS

VENOUS ULCERS

In patients with the history of recurrent DVT screening for selected acquired and inherited risk factors for deep venous thrombosis may be appropriate. (3,¹⁴) (See table 1)

Exercise programs, the use of compression stockings, smoking cessation and avoidance of estrogen therapies can greatly reduce risks of recurrent DVT. Long term anticoagulation may be necessary in these patients. (3)

Certain non-invasive methods are useful to confirm the diagnosis of venous ulcers and clarify the anatomical and functional defect. This will help determine further diagnostic and therapeutic strategies. Color duplex ultrasound scanning which is becoming the de facto standard for evaluation of venous obstruction is also used to assess the location and extent of reflux.

ARTERIAL ULCERS

The ABI is a basic test, which can be performed at the initial office visit. Severe ischemia may occur at less than 0.5. (¹⁵)

In patients with arterial media calcification (mostly diabetics) the ABI may be elevated (> 1.3) due to incompressible vessels. Arterial duplex ultrasound is also used to assess the leg arterial system, and information regarding areas of stenosis is obtained using this technique.

Patients with severe arterial insufficiency, e.g. ABI<0.5 or severe areas of arterial stenosis documented on duplex ultrasound should be referred to a vascular surgeon.

Plethysmography performed in a vascular laboratory with measurements taken at the thigh, calf, ankle, metatarsal, and

digital levels will assess disease progression through volume recordings, which are quantified through the pulse volume recorder. This procedure measures the small volume changes that occur in tissues during systole.(8,¹⁶)

The transcutaneous pressure of oxygen (TcPO₂) is used to help determine the degree of microvascular perfusion, which reflects the metabolic state of the limb. It may be measured with an oxygen electrode coupled directly to the skin of the foot or leg. The limb is adequately perfused when TcPO₂ >30 mm Hg. TcPO₂ measurements are also obtained to assess improvement after hyperbaric oxygen therapy.

NEUROPATHIC ULCERS

Plain radiographs to rule out osteomyelitis are suggested when there is sinus tracking or when probing to bone is possible. (¹⁷) It is important to evaluate underlying blood flow characteristics and determine the need for surgical consultation. Low ABI and TcPO₂ significantly increase the odds ratio of amputation in diabetics. (¹⁸)

INVASIVE INVESTIGATIONS

Venography may be performed as an investigational procedure prior to valvular surgery. Lower extremities arteriography is indicated in patients with ischemic rest pain, intolerable claudication, impending gangrene, or the presence of non-healing ulcers of suspected arterial origin. (16)

Because leg ulcers are neither sterile nor need to be sterile to heal, a quantitative bacterial culture is more specific, and should be performed once wound infection is suspected. (¹⁹) This is performed by curetting or biopsying the bed of the ulcer. The quantitative biopsy is the current gold standard for assessing the quality and quantity of microbial pathogens within a wound. Quantitative biopsies containing greater than 10⁵ organisms per gram of tissue are considered significant, and systemic antibiotherapy should be considered. (²⁰)

Ulcers that probe to bone should be considered osteomyelitic until proven otherwise. Radiographs will usually show characteristic changes such as translucency corresponding to areas of osteolysis. The sensitivity, specificity, and likelihood ratios of probing to bone are better than those of plain radiograph and bone scan but are worse than those of ¹¹¹indium scanning and magnetic resonance imaging.(²¹) More specific tests such as white blood cell scans are more sensitive than bone or gallium scan.(19) In a comparative study of 107 patients, Sommezoghi et al. (²²) found that

^{99m}Tc-labeled ciprofloxacin (Infecton) has a better specificity for bacterial infections than WBC scans in detecting infectious foci in bones and joints.

One should keep in mind that even in the presence of osteomyelitis, constitutional symptoms and leukocytosis may be lacking in immunocompromised and some diabetic patients.

INVESTIGATING ATYPICAL LEG ULCERS

Guided by the medical history and physical examination, some specific laboratory investigations and procedures may be performed. Significantly elevated antinuclear antibodies, rheumatoid factors, or other more specific immunologic tests may tend to support the diagnosis of vasculitic process. Serologic tests for syphilis, or polymerase chain reaction for mycobacterium DNA may be performed on specimens from an ulcer suspected of being of mycobacterial origin (e.g., erythema induratum of Bazin; Mycobacterial panniculitis with subsequent ulceration usually involving the calves). Cryoglobulins may be associated with hepatitis C and leg ulceration. Therefore, hepatitis C serologies and serum level of cryoglobulins may be helpful tests.⁽²³⁾ Like cryoglobulins, cryofibrinogens may be associated with recurrent leg ulcers, especially if there is a history of worsening of symptoms with exposure to cold. Ulcers due to cryofibrinogenemia may be treated with an anabolic steroid, stanozolol (Winstrol).

Leg ulcers of atypical presentation or those that fail to heal should alert the clinician to consider uncommon etiologies. (1) When a wound fails to heal after three to four months of conventional treatment, biopsy of the ulcer edge (either excisional or multiple punch biopsy techniques) should be performed to rule out malignancy. The most common type of cancer developing in chronic wounds is squamous cell carcinoma. Pyoderma gangrenosum is a non-infective ulcer, which usually presents with undermined borders. It may be associated with inflammatory bowel disease, inflammatory arthropathies, or myeloproliferative disorders. Appropriate work up for associated disease should be considered in patients with pyoderma gangrenosum. Patients with leg ulcers are prone to developing contact dermatitis to dressings. When necessary a patch testing should help determine specific allergens.

CONCLUSION

Leg ulcers are very common and physicians should be familiar with the common methods used for their diagnosis

and management. Some laboratory investigations may be helpful and can be ordered as part of the baseline work up. Unusual leg ulcers need more specific tests. The management of leg ulcers will be described in "Management of Leg Ulcers", The Internet Journal of Dermatology, Volume 1 Number 2, 2002.

ACKNOWLEDGEMENT

We are indebted to Dr. Tania J. Phillips for lending us the pictures

References

1. Bowman PH, Hogan DJ. Leg ulcers: a common problem with sometimes uncommon etiologies. *Geriatrics*. 1999 Mar;54(3):43, 47-8, 50 passim.
2. Phillips T, Stanton B, Provan A, Lew R. A study of the impact of leg ulcers on quality of life: Financial, social, and psychologic implications. *J Am Acad Dermatol* 1994;31:49-53.
3. Ridker PM. Inherited risk factors for venous thromboembolism: implications for clinical practice. *Clin Cornerstone*. 2000;2(4):1-14.
4. Falanga V, Eaglstein WH. The "trap" hypothesis of venous ulceration. *Lancet*. 341(8851):1006-1008, April 17, 1993
5. Sarkar PK, Ballantyne S. Management of leg ulcers. *Postgraduate Medical Journal*. 76(901):674-82, 2000 Nov.
6. Boulton A. The pathogenesis of diabetic foot problems: An overview. *Diab Med* 1996;13(Suppl 1):812-6.
7. American Diabetes Association. Consensus Development Conference on diabetic foot wound care. *Diabetes Care*. 1999;22:1354-1360.
8. Goldstein DR, Vogel KM, Mureebe L, Kerstein MD. Differential diagnosis: assessment of the lower-extremity ulcer -- is it arterial, venous, neuropathic? *Wounds-A Compendium of Clinical Research & Practice*, 10(4):125-31, 1998 Jul-Aug.
9. Muha J. Local wound care in diabetic foot complications: aggressive risk management and ulcer treatment to avoid amputation. *Postgrad Med* 1999;106(1):97-102
10. Albrant D H. Management of Foot Ulcers in Patients with Diabetes *J Am Pharm Assoc* 40(4):467-474, 2000.
11. Armstrong DG, Lavery LA, Vela SA, Quebedeaux TL, Fleischli JG. Choosing a practical screening instrument to identify patients at risk for diabetic foot ulceration. *Archives of Internal Medicine*. 158(3):289-92, 1998 Feb 9.
12. Wunderlich RP, Armstrong DG, Husain K, Lavery LA. Defining loss of protective sensation in the diabetic foot. *Advances in Wound Care*. 11(3):123-8, 1998 May-Jun.
13. Smieja M, Hunt DL, Edelman D, Etchells E, Cornuz J, Simel DL. Clinical examination for the detection of protective sensation in the feet of diabetic patients. *International Cooperative Group for Clinical Examination Research*. *J Gen Intern Med* 1999; 14:418-24.
14. Maessen-Visch MB, Hamulyak K, Tazelaar DJ, Crombag NH, Neumann HA. The prevalence of factor V Leiden mutation in patients with leg ulcers and venous insufficiency. *Archives of Dermatology*. 135(1):41-44, January 1999.
15. Tyrrell MR, Wolfe JHN. Critical leg ischaemia: an appraisal of clinical definitions. *Br J Surg* 1993; 80: 177-80.
16. London N J, Donnelly R. Ulcerated lower limb. *BMJ*. 320(7249):1589-1591, June 10, 2000.
17. Caputo GM, Cavanaugh PR, Ulbrecht JS, Gibbons GW,

- Karchmer AW. Assessment and management of foot disease in patients with diabetes. *N Engl J Med*. 1995;332:854-860.
18. Reiber GE. The epidemiology of diabetic foot problems. *Diabetic Med* 1996; 13:S6-11.
19. Sibbald RG, Williamson D, Falanga V, Cherry GW. Venous leg ulcers. In Krasner DL, Rodeheaver GT, Sibbald RG (eds). *Chronic Wound Care: A clinical Source Book for Healthcare Professionals*, Third Edition. Wayne, PA: HMP Communications, 2001:483-494.
20. O'Meara SM, Cullum NA, Majid M, Sheldon TA. Systematic review of antimicrobial agents used for chronic wounds. *Br J Surg*. 2001 Jan;88(1):4-21.
21. Eckman ME, Greenfield S, Mackey WC, et al. Foot infections in diabetic patients. Decision and cost-effectiveness analyses. *JAMA*. 1995;273:712-20
22. Sonmezoglu K, Sonmezoglu M, Halac M, Akgun I, Turkmen C, Onsel C, Kanmaz B, Solanki K, Britton KE, Uslu I. Usefulness of (99m)Tc-Ciprofloxacin (Infecton) Scan in Diagnosis of Chronic Orthopedic Infections: Comparative Study with (99m)Tc-HMPAO Leukocyte Scintigraphy. *J Nucl Med* 2001 Apr;42(4):567-574
23. Mahabir RC, Taylor CD, Benny WB, Dutz JP, Snelling CF. Necrotizing Cutaneous Cryoglobulinemic Vasculopathy. *Plastic & Reconstructive Surgery*. 107(5):1221-1224, April 15, 2001.
24. Khachemoune A, Phillips TJ. Cost effectiveness in wound care. In Krasner DL, Rodeheaver GT, Sibbald RG (eds). *Chronic Wound Care: A clinical Source Book for Healthcare Professionals*, Third Edition. Wayne, PA: HMP Communications, 2001:191-198.
25. Angle, N. Bergan, JJ. Chronic venous ulcer. *BMJ*. 314(7086):1019-1023, April 5, 1997.
26. McKenna PJ, Lehr GS, Leist P, Welling RE. Antiseptic effectiveness with fibroblast preservation. *Ann Plast Surg*. 1991 Sep;27(3):265-8.
27. Kerstein MD. Moist wound healing: the clinical perspective. *Ostomy Wound Manage*. 1995 Aug;41(7A Suppl):37S-44S
28. Margolis DJ, Berlin JA, Strom B. Risk factors associated with the failure of a venous ulcer to heal. *Arch Dermatol* 1999;135:920-6.
29. Margolis, DJ. Pentoxifylline in the Treatment of Venous Leg Ulcers. *Arch Dermatol*. 136(9):1142-1143, September 2000.
30. Hiatt WR. Medical treatment of peripheral arterial disease and claudication. *NEJM*. 344 (21) 1608-1621. May 24, 2001.
31. Bielanski TE, Piotrowski ZH. Horse-Chestnut Seed Extract for Chronic Venous Insufficiency. *Journal of Family Practice*. 48(3):171-172, March 1999.
32. Evans, D. Land, L. Topical negative pressure for treating chronic wounds. *Cochrane Wounds Group*. Issue 1. 2001. Date of Most Recent Update: 28-11-2000.
33. Atillasoy E. Current and investigative uses of Graftskin (Apligraf) in wound care. *Wounds* 2000; 12(5 Suppl A):3A
34. Veves A, Falanga V, Armstrong DG, Sabolinski ML; The Apligraf Diabetic Foot Ulcer Study. Graftskin, a human skin equivalent, is effective in the management of noninfected neuropathic diabetic foot ulcers: a prospective randomized multicenter clinical trial. *Diabetes Care* 2001 Feb;24(2):290-5
35. Khachemoune A, Bello YM, Phillips TJ. Factors that influence healing in chronic venous ulcers treated with Cryopreserved Human Epidermal Cultures. *Dermatol Surg*. (In-press).

Author Information

Amor Khachemoune, MD, CWS

Medicine, Division of dermatology, Georgetown University Medical Center

Catharine Lisa Kauffman, MD

Chief, Medicine, Division of Dermatology, Georgetown University Medical Center