

A case for biopsying all adult adenoidal tissue

J Mitchell, I Pai, L Pitkin, V Moore-Gillon

Citation

J Mitchell, I Pai, L Pitkin, V Moore-Gillon. *A case for biopsying all adult adenoidal tissue*. The Internet Journal of Otorhinolaryngology. 2008 Volume 9 Number 2.

Abstract

Objective The aims of this study were to determine histological outcome of biopsies of postnasal space (PNS) tissue in adults and the prevalence of a malignant diagnosis. The presenting features of these patients were also examined. **Methods** A retrospective review of adult patients who had biopsies of PNS tissue over a five year period was examined. Case notes were reviewed to determine the presenting symptoms, clinical suspicion, time to biopsy, appearance of the tissue and final histological diagnosis. **Results** After exclusions, a total of 110 adult patients underwent biopsy of PNS tissue. The primary presenting symptom was otitis media with effusion (OME) in 42% of cases, snoring or nasal obstruction in 43%, cervical lymphadenopathy in 11%, bleeding post nasal space in 2 cases, otalgia in 2 cases, postnasal drip in 2 cases, incidental in 2 cases and facial pain in one other case. Biopsies were reported as benign in 92 (84%) patients. A malignant biopsy was found in 18 cases (16%). Of the 18 malignancies, eight were reported as undifferentiated nasopharyngeal carcinoma (NPC), five as squamous cell carcinoma (SCC), one as differentiated non-keratinising NPC and four as lymphoma. Ten of the fourteen patients with NPC presented with symptoms which alerted the clinician as to a potential cancer diagnosis and were biopsied urgently. Four of the fourteen NPC cases presented in a manner which was thought initially to be benign. **Conclusions** The true incidence of adenoidal hypertrophy in adults is unknown. Previous studies have suggested that adenoidal tissue in adults, if present, is usually benign. The findings from our study contradict this. All the patients in our study with malignancy of the postnasal space had additional signs and symptoms and we therefore advocate that if adenoidal tissue is seen in the context of nasal obstruction, OME, cervical lymphadenopathy, bleeding or pain, then the adenoids must always be biopsied or removed irrespective of their macroscopic appearance.

INTRODUCTION

Adenoidal tissue is one of the first line immunological defence mechanisms of the upper aero-digestive tract and reaches its maximal size between three and seven years of age. Atrophy occurs from the age of ten years and is usually complete by the age of twenty.¹² Although conditions associated with adenoidal hypertrophy are generally considered to be a childhood illness, to our knowledge, no study has accurately examined the incidence of adenoidal hypertrophy in adults. In current clinical practice, with the advent of nasendoscopy as a routine part of clinical nasal examination, adenoidal tissue is not uncommonly found in adults. The world literature suggests that adenoidal hypertrophy rarely indicates a malignant diagnosis.³⁴⁵ However, it is clearly not possible to distinguish neoplastic adenoidal tissue from benign hypertrophy based on the macroscopic appearance alone. Therefore many clinicians may sometimes face the dilemma whether or not to biopsy adenoidal mass in adults. With this in mind, we undertook a retrospective review of adult patients undergoing adenoidal

biopsy or adenoidectomy at St George's Hospital, London.

METHODS

A retrospective review was undertaken of all adult patients undergoing adenoidal biopsy or removal between January 2001 and December 2005. Material was sourced from our pathology database and corresponding clinical information was gathered from hospital notes. Patients were excluded if they were under the age of 18 years at time of biopsy or had previous nasopharyngeal carcinoma or tumour arising from other sites and spreading into the postnasal space. A database was constructed with information including; patient age, sex and race, primary and other presenting symptoms, appearance of the postnasal space (PNS) on examination at operation, histological diagnosis and time duration from initial finding of adenoidal tissue to biopsy.

RESULTS

After exclusions, a total of 110 adult patients underwent biopsy of PNS tissue. The mean patient age was 48 years at

the time their respective biopsies (range 19-81). Sex distribution was slightly biased with 58% male and 42% female patients. The primary presenting symptom was otitis media with effusion (OME) in 42% of cases, snoring or nasal obstruction in 43%, cervical lymphadenopathy in 11%, bleeding post nasal space in 2 cases, otalgia in 2 cases, postnasal drip in 2 cases, incidental in 2 cases and facial pain in one other case (graph 1).

Biopsies were reported as benign in 92 (84%) patients. A malignant biopsy was found in 18 cases (16%). Of the 18 malignancies, eight were reported as undifferentiated nasopharyngeal carcinoma (NPC), five as squamous cell carcinoma (SCC), one as differentiated non-keratinising NPC and four as lymphoma (table 1).

Of the 14 patients diagnosed with NPC, the majority (12) had postnasal tissue which was described as moderate or large / obstructing the choanae at the time of biopsy. All of the patients diagnosed with post nasal space lymphoma presented with large / obstructing tissue.

Ten of the fourteen patients with NPC presented with symptoms which alerted the clinician as to a potential cancer diagnosis and were biopsied urgently. In these cases the presenting features included cervical lymphadenopathy in seven patients, otalgia, facial pain and a bleeding postnasal space.

Four of the fourteen NPC cases presented in a manner which was thought initially to be benign. One had large glandular PNS tissue causing nasal obstruction but no other symptoms or palpable neck nodes. The remaining three presented with bilateral glue ear only and none had palpable cervical lymph nodes (graph 2)

Four cases returned a histological diagnosis of lymphoma. One of these patients presented with cervical lymphadenopathy suspicious of lymphoma. The remaining three presented with OME (two cases) and nasal obstruction (one case). None of these three had palpable lymph nodes, but all were found to have sub clinical cervical nodes on subsequent CT scanning (graph 3).

Ethnicity of the NPC cancer cases were White British in 9 patients, Black Afro-caribbean in 3 cases and Chinese in 2 cases.

Figure 1

Graph 1: Primary presenting symptoms of patients in this study (n=110).

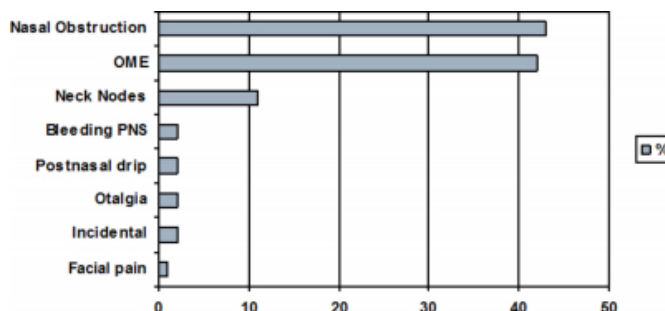


Figure 2

Graph 2: Presenting symptoms of patients with NPC and presence of cervical lymphadenopathy on CT and clinical examination (n=14).

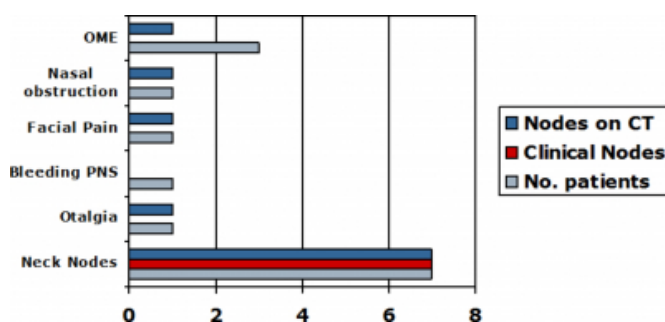


Figure 3

Graph 3: Presenting symptoms of patients with lymphoma and presence of cervical lymphadenopathy on CT and clinical examination (n=4).

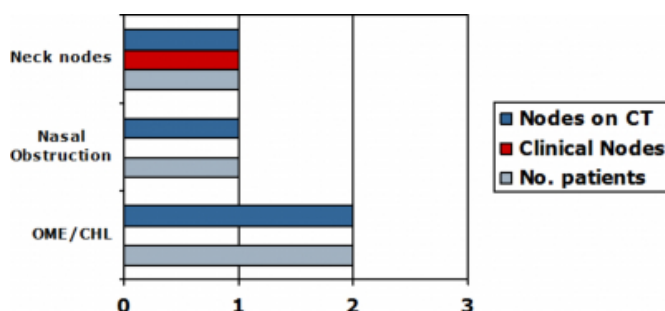


Figure 4

Table 1

| Biopsy diagnosis | No of patients (n=110) | % of total |
|---|------------------------|------------|
| Benign | 92 | 84 |
| Malignant: | 18 | 16 |
| Undifferentiated nasopharyngeal carcinoma (NPC) | 8 | 7.3 |
| Squamous cell carcinoma (SCC) | 5 | 4.5 |
| Differentiated non-keratinising NPC | 1 | 0.9 |
| Lymphoma (various) | 4 | 3.6 |

DISCUSSION

In view of the natural history of development and involution of adenoidal tissue, adult adenoidal tissue in adults has conventionally been considered a rare entity.¹² With nasendoscopic examination of the nasopharynx in the outpatient clinic becoming routine practice, it is increasingly recognised that adenoidal tissue in adults is not a rare finding. What is not known is the likelihood of such patients having a neoplastic nasopharyngeal lesion.

Evidence from the medical literature so far appears to support the conventional teaching that adult adenoidal tissue is benign and does not necessitate biopsy unless there are particular sinister features or if the patient is from an area of high incidence of NPC. Kamel et al (1990) looked at 35 adult patients with adenoidal hypertrophy.³ Five patients had bilateral secretory otitis media (OME), 18 had nasal obstruction and four presented with snoring. Following adenoidectomy, four of the five patients with OME improved, while one required subsequent ventilation tube insertion. Biopsies from all 35 patients were benign. The authors also noted histological differences in the adenoidal tissue between adults and children, in that adult adenoidal tissue was either smooth or irregular and did not show crypts or vertical furrows.

Zong Young-Shey (1989) followed up 43 adult patients with nasopharyngeal lymphoid hyperplasia (NPLH), who had been identified from a mass screening programme for NPC in the high incidence area of Zhongshan City. The authors suggested two types of NPLH in adults and found that none went on to develop NPC after an 8.5 year period.⁴

A prospective study by Finkelstein et al (1994) looked at 167 consecutive patients with adult onset OME and examined all patients with nasendoscopy.⁵ Paranasal sinus disease was thought to be the cause in 110 cases. They described smoking induced NPLH as a disease entity

causing OME in eight patients. These patients had prominent hyperaemia and irregular lymphoid vegetations on examination of the nasopharynx. Five patients were thought to have 'adult onset adenoidal hypertrophy', two of whom also had snoring or obstructive sleep apnoea (OSA). In these patients, the adenoid tissue and mucosa covering two thirds to all of the nasal choanae had a normal appearance. Interestingly, NPC was found in two patients in this study. Both had cervical lymphadenopathy and their otological symptoms were preceded by nasal obstruction and headache. Thus in this series, two out of fifteen patients (13%) presenting with OME were found to have NPC.

A later study by Finkelstein et al (1997) examined the histological differences between a group of 17 heavy smokers with NPLH and 10 non smokers with NPLH. None of these patients showed evidence of malignancy.⁶

Nasopharyngeal carcinoma accounts for approximately 85-95% of malignancy originating in the nasopharynx, the remaining mostly being lymphoma. NPC is relatively rare in white European populations with an incidence of 1:100,000. This is in striking contrast to that in the Southern Chinese population where incidence is 15-50:100,000. Factors that have been implicated in its aetiology include genetic susceptibility, dietary factors (preserved food, salted fish and lack of fresh fruit) and latent infection with the Epstein Barr Virus.⁷ The peak incidence of NPC occurs between 40 to 50 years of age with males outnumbering females by approximately 2:1. Nasopharyngeal carcinoma is divided pathologically into three types: Type I or keratinizing squamous cell carcinoma, Type II or non-keratinizing carcinoma and Type III or undifferentiated carcinoma.

Lymphoma presenting as a postnasal space mass is relatively uncommon; approximately 10% of all non-Hodgkin's Lymphoma occur in extra nodal sites with nasopharyngeal lymphoma accounting for 20% of these.⁸ In contrast, just 0.32% of patients with Hodgkin's Disease have Hodgkin's lymphoma of the nasopharynx.⁹ Nasopharyngeal malignancy tends to present late with early signs and symptoms being subtle and variable. NPC most commonly presents with cervical lymphadenopathy (between 50-90%).⁷ Nasal symptoms occur in approximately half with unilateral nasal obstruction and blood stained mucus and one third presenting with OME and hearing loss.

Nasopharyngeal lymphoma also tends to present late with all patients having a long history of worsening nasal obstruction and subsequent hearing loss secondary to OME. Generalised

or “B” symptoms (unexplained weight loss, fever and night sweats) can also be presenting features.

In our retrospective study, we have shown that 16% (18/110) of patients who had undergone a postnasal space biopsy had a malignant diagnosis. This appears to be contrary to the general consensus in the world literature where adult adenoid tissue is largely regarded as benign. Out of the 14 patients with NPC, ten presented with either lymphadenopathy or “sinister features” namely either pain or bleeding. The remaining four patients had either OME (3/4) or significant nasal obstruction (1/4) only and were initially thought to have a benign diagnosis. All lymphoma patients had additional symptoms (2/4 had OME, 1/4 had significant nasal obstruction and 1/4 had cervical nodal disease).

Our study is not without flaw. Firstly, it is a retrospective study and subject to selection bias. There is anecdotal evidence from detailed departmental discussions that it is not universal practice to biopsy all adult adenoidal tissue. Secondly, the data originate from St George’s Hospital, London, which has a dedicated Head and Neck Cancer Unit with a cancer catchment area of over 2 million people. With this in mind we actively excluded all patients with a previous diagnosis of PNS carcinoma or those with a history of carcinoma originating from an adjacent site.

CONCLUSIONS

The true incidence of adenoidal hypertrophy in adults is unknown. Previous studies have suggested that adenoidal tissue in adults, if present, is usually benign. The findings from our study contradict this. All the patients in our study with malignancy of the postnasal space had additional signs

and symptoms and we therefore advocate that if adenoidal tissue is seen in the context of nasal obstruction, OME, cervical lymphadenopathy, bleeding or pain, then the adenoids must always be biopsied or removed irrespective of their macroscopic appearance. Further study is needed to examine the prevalence of adenoid tissue in adults.

CORRESPONDENCE TO

James E Mitchell 13C Woodside Wimbledon, London.
SW19 7AR Tel: +44 7841 921574 Fax: +44 208 879 1551
Email: jamesmitchell@btpopenworld.com

References

1. Gray LP. The T’s and A’s problem – assessment and reassessment. *J Laryngol and Otol* 1977;91:11-32
2. Fujiyoshi T, Watanbe T, Ichimiya I, Mogi G. Functional architecture of the nasopharyngeal tonsil. *Am J Otolaryngol* 1989;10:124-131
3. Kamel RH, Ishak EA. Enlarged adenoid and hypertrophy in adults: Endoscopic approach and hisopathological study. *J Laryngol Otol* 1990;104:965-967
4. Yong-sheng Z, Wan-jun Z. A morphologic and follow-up study on the nasopharyngeal lymphoid hyperplasia and its relation to cancer. *Chin Med J* 1989;102(8):625-629
5. Finkelstein Y, Ophir D, Talmi Y, Shabtai A, Strauss M, Zohar Y. Adult-onset otitis media with effusion. *Arch Otolaryngol Head & Neck Surg* 1994;120:517-527
6. Finkelstein Y, Malik Z, Kopolovic J, Bernheim J, Djaldetti M, Ophir D. Characterisation of Smoking-Induced Nasopharyngeal Lymphoid Hyperplasia. *Laryngoscope* 1997;107(12):1635-1642
7. Sham JST, Choy D, Wei W. Nasopharyngeal carcinoma: orderly neck node spread. *Int J Radiat Oncol Biol Phys* 1990;19:929-933
8. Thomas JO, Ogunsanwo BO, Ogunbiyi AO. Highlights of extranodal lymphomas in Ibadan, Nigeria. *Cent African J Med* 1999;45(7):173-176
9. Anselmo AP, Cavalieri E, Cardarelli L, Gianfelici V, Osti FM, Pescarmona E, Maurizi Enrici R. Hodgkin’s disease of the nasopharynx: diagnostic and therapeutic approach with a review of the literature. *Ann Haematol* 2002;81(9):514-516

Author Information

James E. Mitchell

Department of Otolaryngology and Head & Neck Surgery, St George's Hospital

Irumee Pai

Department of Otolaryngology and Head & Neck Surgery, St George's Hospital

Lisa Pitkin

Department of Otolaryngology and Head & Neck Surgery, St George's Hospital

Victoria Moore-Gillon

Department of Otolaryngology and Head & Neck Surgery, St George's Hospital