

# Para pharyngeal Space Tumors: A Review Of 10-Year Experience

S Ritesh, J Rashmi, K Nita, C Shelly, M Ashish

## Citation

S Ritesh, J Rashmi, K Nita, C Shelly, M Ashish. *Para pharyngeal Space Tumors: A Review Of 10-Year Experience*. The Internet Journal of Pathology. 2008 Volume 8 Number 2.

## Abstract

Background: Para pharyngeal space tumors (PPS) are rare, representing only 0.5 % of head and neck neoplasm. We report the clinicopathological profile of 28 patients with PPS tumors. Aims: Twenty eight patients diagnosed with PPS tumors were included and detailed clinicopathologic profile was studied. Materials and methods: Twenty eight patients over a period of 10 years (1997-2006) were included in the study. The age of patients ranged from 16 to 55 years with male to female ratio of 1.3: 1. The commonest clinical presentation was a slowly increasing painless neck swelling. Other complaints ranged from dysphagia, dyspnoea, hoarseness of voice, impaired hearing and pain. Results and conclusion: Out of 28 cases, 3 cases were malignant and the rest were benign on histopathology. The most common tumor was neurilemmoma (14 cases). Other histological entities were 5 cases of lipoma, 2 cases each of pleomorphic adenoma and meningioma, and one case each of malignant peripheral nerve sheath tumor, dermoid cyst, neurofibroma, metastatic papillary carcinoma thyroid and squamous cell carcinoma. The knowledge of differential diagnosis of PPS tumors and proper preoperative investigations may prevent delay in diagnosis and unnecessary surgical procedures.

## INTRODUCTION

Para pharyngeal space tumors (PPS) are uncommon tumors, which often present therapeutic and preoperative diagnostic problems due to variable nonspecific symptoms and complex anatomy of the region. Most of the lesions (70-80%) are benign comprising of salivary gland tumors, neurogenic tumors and paragangliomas in descending order of frequency.[1] Other rare tumors include lipoma, hemangioma, aneurysm, branchial cleft cyst, meningioma, chordoma and sarcoma

## SURGICAL ANATOMY

The PPS is an inverted funnel shaped space, bounded above by base of skull, inferiorly by hyoid bone and medially by lateral wall of pharynx. Lateral wall is formed by medial pterygoids, ascending ramus of the mandible, fascia of the parotid gland and part of posterior belly of digastric muscle. Anteriorly, the space is narrow and bounded by pterygomandibular raphe and buccinator muscle. Prevertebral and paravertebral fascia limits the space posteriorly. The space is divided into two compartments. The prestyloid compartment contains internal maxillary artery, inferior alveolar nerve, lingual nerve and the auriculotemporal nerve. The poststyloid compartment contains internal jugular vein, cranial nerves-IX, X, XII,

cervical sympathetic chain and lymph nodes. PPS communicates with the retropharyngeal space, infratemporal fossa and pterygopalatine fossa.

## MATERIAL AND METHODS

The detailed 10-year (1997-2006) clinico histopathological data of 28 patients presenting with PPS at our institute was analyzed and histopathological slides reviewed.

## RESULTS

The ages of the patients ranged from 16-55 years (mean: 29.7 years). There was a slight male predominance with male to female ratio of 1.3:1. The most common mode of presentation was a gradually increasing painless cervical swelling (n=18, Table 1). The duration of symptoms ranged from 8 months to 8 years except in a case of neurogenic sarcoma that presented with painful neck swelling with duration of one month. The other complaints ranged from dysphagia, hoarseness, impaired hearing and pain. Radiological investigations revealed a para pharyngeal space mass lesion in all cases, one case, which was later diagnosed as neurogenic sarcoma showed extensive extensions in to surrounding soft tissues. All cases underwent surgery with histopathological examination to confirm the diagnosis. The most common surgical approach was Trans cervical (23

patients); other surgical approaches used were Trans parotid approach with superficial parotidectomy and facial nerve preservation (2 cases), combined cervical parotid approach (2 cases) and transoral (1 case, Table II). The most common histopathological diagnosis was schwannoma (14 cases, Fig. 1a). Other cases were diagnosed as lipoma (n=5), psammomatous meningioma (n=2), pleomorphic adenoma (n=2), dermoid cyst (n=1), neurofibroma (n=1, Fig. 1b), metastatic papillary carcinoma thyroid (n=1, Fig. 1c, d), basaloid squamous cell carcinoma (n=1) and malignant peripheral nerve sheath tumor (n=1, Table III). Diagnosis of metastatic papillary carcinoma thyroid prompted fine needle aspiration cytology (FNAC) of thyroid, which confirmed the diagnosis of thyroid tumor. The patient underwent a radical thyroidectomy and is well on follow up. An extensive search for the primary tumor was carried out in the patient diagnosed with basaloid squamous cell carcinoma (SCC). Laryngoscopy revealed an ulceroproliferative growth over the right true vocal cord, which was confirmed on biopsy. The patient underwent total laryngectomy with radiotherapy and is on follow up. One case of malignant peripheral nerve sheath tumor had widespread soft tissue extensions; a radical surgery using a combined Trans cervical – parotid approach was carried out with postoperative chemotherapy to treat residual tumor. However the patient succumbed to the disease after 2 years of follow up. Rest of the patients with benign lesions received no further treatment

**Figure 1**

Table 1: Clinical features of patients of PPS tumor

| Clinical Features   | Number of patients |
|---------------------|--------------------|
| Mass in neck        | 22                 |
| Painless            | 18                 |
| Painful             | 04                 |
| Dysphagia           | 03                 |
| Hoarseness of voice | 02                 |
| Impaired Hearing    | 01                 |
| Total               | 28                 |

**Figure 2**

Table 2: Surgical approaches in Para pharyngeal tumors

| Surgical approach              | Number of cases |
|--------------------------------|-----------------|
| Trans cervical                 | 23              |
| Trans parotid                  | 02              |
| Combined Tran cervical-parotid | 02              |
| Trans oral                     | 01              |
| Total                          | 28              |

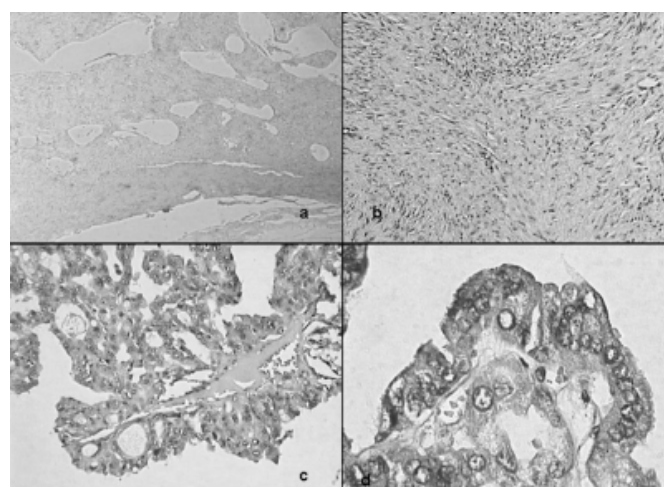
**Figure 3**

Table 3: Histological diagnosis of Parapharyngeal space tumors

| Diagnosis                               | Number of patients |
|---|--------------------|
| Neurilemmoma (Schwannoma)               | 14                 |
| Lipoma                                  | 05                 |
| Pleomorphic Adenoma                     | 02                 |
| Meningioma                              | 02                 |
| Malignant peripheral nerve sheath tumor | 01                 |
| Dermoid cyst                            | 01                 |
| Neurofibroma                            | 01                 |
| Metastatic Papillary carcinoma thyroid  | 01                 |
| Metastatic SCC                          | 01                 |
| Total                                   | 28                 |

**Figure 4**

Figure 1a. Low power view of schwannoma (H & E, 100X) b. Low power view of neurofibroma (H & E, 100X). c. Papillary carcinoma thyroid (H & E, 100X) d. Papillary carcinoma thyroid (H & E, 400X )



## DISCUSSION

The mean age for PPS was 40 years by Stanley.[2] Maran et al [3] and Pang et al[1] reported no sex predominance in their studies. In our study, the mean age was 29.7 years with slight male predominance.

Salivary gland tumors comprise the majority of PPS tumors followed by neurogenic tumors and paragangliomas.[14] In our study, Neurilemmoma was the commonest tumor, compatible with findings of Cai X et al.[5] Salivary gland tumors arise from deep lobe of parotid gland or from the minor salivary gland tissue within PPS fat. Those arising from deep lobe of parotid gland usually acquire a dumb-bell shape as a result of constriction of the tumor in the region of stylomandibular ligament. Rarely, meningioma may protrude through skull foramina and present as cervical swelling. On FNAC, cytomorphology of meningioma mimics that of other head and neck tumors like acinic cell carcinoma and paraganglioma etc.[6] Therefore, possibility of meningioma should be kept in the differential diagnosis of PPS tumors. Occurrence of metastatic papillary thyroid carcinoma in the PPS is extremely rare.[7] Rouviere described that lymphatic bundles connect the posterior and superior compartments of the lateral thyroid lymph vessels to retropharyngeal lymphatics.[8] PPS and retropharyngeal space communicate with each other through the space posterior to superior constrictor muscle. Tumor cells from thyroid, laryngeal and hypopharyngeal carcinomas invading the pharyngeal wall can metastasize to PPS through the same pathway.

Computed tomography (CT) scan and FNAC have a great role in making the diagnosis and deciding the suitable surgical approach. CT scan can demonstrate the size and extent of the tumor and its relationship to surrounding structures.[9] Magnetic resonance imaging has also become a very useful diagnostic tool.

Several surgical approaches have been described. The selection of surgical approach depends on tumor size and site. There are 4 main surgical approaches including transcervical, transoral, transparotid and mandibular swing approach.[1]

Transcervical[1]: Transcervical is the commonest approach used in our series. The main incision is at the level of hyoid. Skin flaps are raised to expose the submandibular salivary gland and tail of parotid. The digastric tendon is followed posteriorly upto styloglossus and stylohyoid ligament. The

Para pharyngeal space is entered by dividing these structures and the mass delivered by blunt dissection.

Transoral[14]: Transoral approach offers a direct route to tumors present in oropharynx; however this is rarely used these days, due to its risk of hemorrhage, infection, facial nerve injury and tumor implantation. It should be used only for small lesions not extending upto styloid process.

Transparotid[14]: Trans parotid approach is generally employed for dealing with deep lobe parotid tumors. It involves a superficial parotidectomy with identification and preservation of facial nerve branches.

Mandibular swing approach[1]: Mandibular swing approach is used for very large and especially vascular tumors or for which maximal exposure at skull base is required for control of bleeding and tumor removal.

Tran's cervical- parotid approach is used in tumors with extensive spread. This approach was used in two cases of our series.

Because of anatomical location of PPS tumors, a wrong diagnosis of tonsillar tumor or retromandibular lymphnode may result in unnecessary operative procedures, as in one of our cases, which underwent a tonsillectomy.

In conclusion, the knowledge of differential diagnosis of PPS tumors and proper preoperative investigations may prevent delay in diagnosis and unnecessary surgical procedures.

## CORRESPONDENCE TO

Dr Ritesh Sachdev A 803, Plot 7A, Navrattan Apartments,  
Sector 23, Dwarka, New Delhi 110075  
sachdev05@gmail.com Ph: 09868011166

## References

1. Pang KP, Goh CH, Tan HM. Parapharyngeal space tumors: an 18-year review. *J Laryngol Otol.* 2002 Mar; 116(3): 170-5.
2. Stanley RE. Parapharyngeal space tumors. *Ann Acad Med Singapore.* 1991 Sep; 20(5): 589-96
3. Maran AG, Mackenzie IJ, Murray JA. The parapharyngeal space. *J Laryngol Otol.* 1984 Apr; 98(4): 371-80.
4. Tak B, Bhuie HS, Gupta A.K. Parapharyngeal space tumors. An overview. *Indian Journal of Otolaryngology and Head and neck surgery* 2001; 53(2): 173-75.
5. Cai X, Shi L, Dong P. Parapharyngeal space neoplasms. *Zhonghua Er Bi Yan Hou Ke Za Zhi.* 1998 Jun; 33(3): 178-80.
6. Tan LH. Meningioma presenting as a parapharyngeal tumor: report of a case with fine needle aspiration cytology. *Acta Cytol.* 2001 Nov-Dec; 45(6): 1053-9.
7. Saydam L, Kalcioğlu T, Demirkiran A, Gurer M. Occult

papillary thyroid carcinoma presenting as a parapharyngeal metastasis. Am J Otolaryngol. 1999 May-Jun; 20(3): 166-8.

8. Rouviere H. Anatomy of the Human Lymphatic system: A Compendium translated from the original 'Anatomie des Lymphatiques de Homme' and Rearranged for the use of

students and Practitioners by M.J.Tobias. Ann Arbor, MI, Edward Bros, 1938.

9. Whyte AM, Hourihan MD. The diagnosis of tumors involving the parapharyngeal space by computed tomography. Br J Radiol. 1989 Jun; 62(738): 526-31.

**Author Information**

**Sachdev Ritesh, M.D., D.N.B**

Maulana Azad Medical College

**Jain Rashmi, M.D.**

Maulana Azad Medical College

**Khurana Nita, M.D.**

Maulana Azad Medical College

**Chadha Shelly, M.D.**

Maulana Azad Medical College

**Mandal K. Ashish, MD**

Maulana Azad Medical College