

A Case of Primary Osteoma Cutis in an Infant

K G, S Chitra

Citation

K G, S Chitra. *A Case of Primary Osteoma Cutis in an Infant*. The Internet Journal of Pathology. 2008 Volume 9 Number 2.

Abstract

Neck nodules in an infant can occur due to varied etiology. One such condition is Osteoma Cutis. Osteoma Cutis is the organized deposition of calcium and phosphate within the skin, arranged in a manner seen in normal bone formation. It can occur de novo or secondary to systemic disease. We present here an infant with a primary Osteoma Cutis, which would help in understanding the presentation and treatment of the same.

CASE REPORT

A 4 month old baby boy was brought by his parents with the complaint of a small nodule noted in the back of the neck, since 3 weeks. There was no preceding history of trauma. Also, the possibility of birth trauma was denied by mother.

On examination, the baby was active and playful without any systemic problems. There was a 3*2 cm firm non tender nodule in the subcutaneous plane in the postero lateral aspect of the neck. The skin overlying the swelling appeared normal. There were no other skin lesions and cervical lymph nodes were not palpable. Baseline bloods were within normal limits.

The parents were keen in getting the nodule removed. The nodule was excised without difficulty after informed consent, under general anesthesia. Post operative course was uneventful and at 1 yr follow up the child is doing well with a fine scar.

The specimen was a 4*3*2 cm lesion of skin with subcutaneous tissue. There was a gritty feel on sectioning the tissue. Upon hematoxylin and eosin stain, the lesion revealed a circumscribed nodule in the dermis, extending into the subcutaneous tissue. Characteristic appearance of Osseous trabeculae enclosing fat and marrow cells pointed to the diagnosis of Osteoma Cutis (Fig 1 & 2).

Figure 1

Fig : 1 Low power * 100, H&E stain – circumscribed nodule in the dermis consisting of Osseous tissue

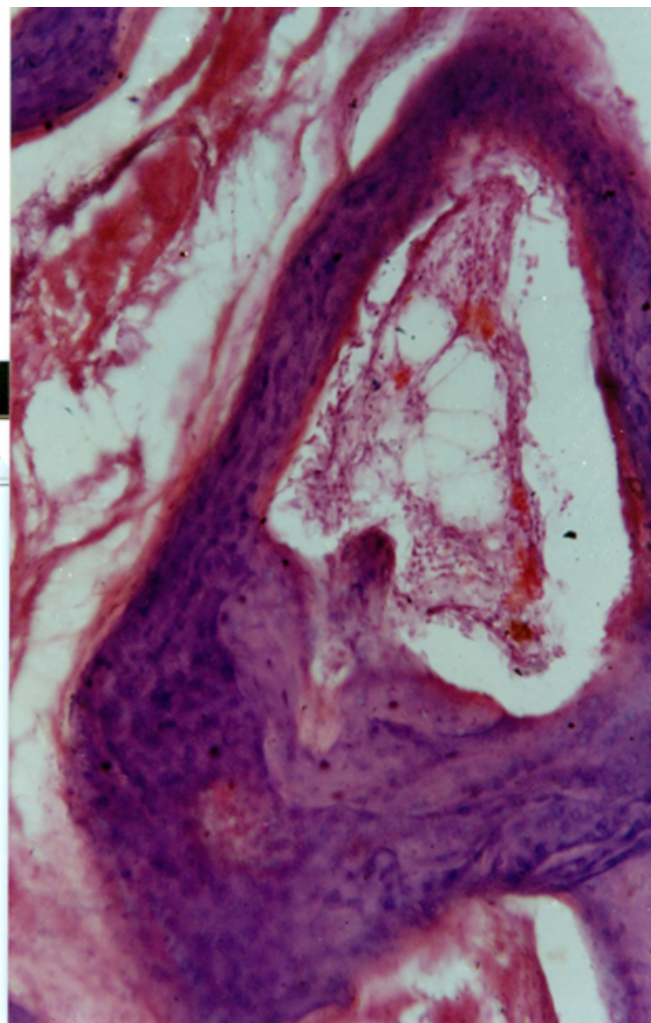
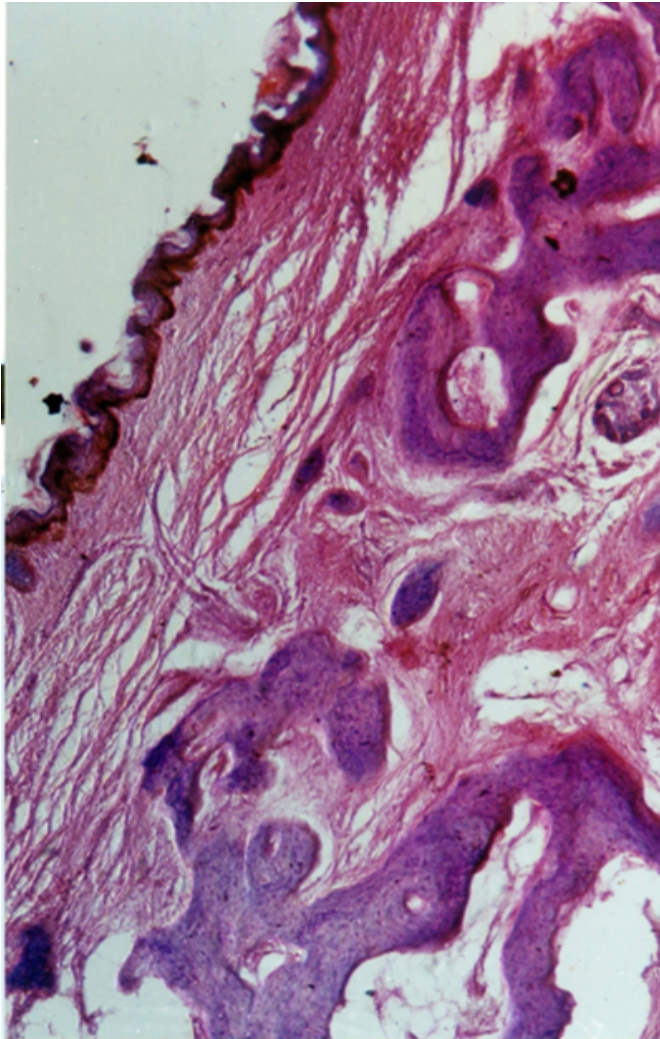


Figure 2

Fig : 2 High power *200, H&E stain – Osseous trabeculae enclosing fat and marrow cells



DISCUSSION

Primary Osteoma Cutis may be defined as a true bony new growth arising within the skin from bone forming tissue, showing no tendency to invade or metastasise, without evidence of Albright's hereditary Osteodystrophy in either the patient or his family¹.

Most Osseous nodules in the skin are not true neoplasms, but result from metaplastic ossification, which usually occurs in a focus of calcification. The initiating lesion is frequently an inflammatory granuloma or scar. Osteomas can occur secondary to Scleroderma, Melanocytic Nevus, Basal cell Carcinoma, Pilomatrixoma, Histiocytoma, Chondroid Syringoma, Acne cyst and Hematoma²³. At times Diaphyseal aclasia can be associated with Osteoma Cutis¹.

Typically the histopathological features of the lesion include Osseous tissue with trabeculae containing fat and marrow cells³.

Following groups have been described to occur

Patient with widespread Osteoma

Patient with a single large plaque like Osteoma present since birth either in the skin or scalp

Patient with a single small Osteoma arising in later life in various locations

Osteomas of the face seen exclusively in females⁴

Osteoma Cutis is believed to develop from displaced bone fragments or embryonal cell nests. The connective tissue and supporting tissue elements are closely related and may acquire each other's potentiality¹.

The child illustrated in the case report was otherwise well and there was no positive family history pertaining to Osteodystrophy. Thus the occurrence of primary Osteoma Cutis in our patient is an infrequent condition calling for high index of clinical suspicion, when encountering a skin nodule in an infant. The standard management is simple excision of the lesion, which is curative.

CONCLUSION

Primary Osteoma Cutis is an infrequent lesion of the skin, which can present as a firm to hard lesion, without any sinister features of neoplasm or dissemination. It also has an excellent prognosis due to the curative nature of the lesion once excision is undertaken.

References

1. Donaldron EM, Summerly R. Primary Osteoma Cutis and Diaphyseal Aclasia. Arch Dermatol 1962;85:261-5.
2. Duperrat B. Cutaneous Osteomas. Study based on 24 personal cases. Ann dermatol Syphiligr 1961;88:11-31.
3. Roth L, Stowell RE, Hehrig EB. Cutaneous Ossification. Report of 120 cases and review of literature. Arch Pathol 1963;76:44-54.
4. Mackie RM. Soft tissue tumours. In: Textbook of Dermatology (RH Champion, JL Burton, DA Burur, SM Breathnach, Eds), 6th edition, Vol 3 Oxford, Blackwell Scientific publications 1998; 2370.
5. Jerajani HR, Amladi ST, Patwardhan MP, Mahajan SA. Skin tumours and lymphoproliferative disorders. In: Textbook and Atlas of Dermatology (RG Valia, AR Valia, K Siddapa, Eds), I ed, Vol 2, Mumbai, Bhalani Publishing house, 1994:1068.

Author Information

Krishna Kumar G, MCh

Specialist Paediatric Surgeon, HTAA, 25100 Kuantan, Malaysia

S. Chitra, MD

Consultant Pathologist, Institute of Child Health, Chennai 600008, India