

Penile Transplants: To Do or Not To Do: Medical, Legal, Psychosocial, and Ethical Issues of Penile Transplants for Injured Veterans in the United States

A Ochasi, N Sopko, G Mamo, V Pepe, A L Burnett, II

Citation

A Ochasi, N Sopko, G Mamo, V Pepe, A L Burnett, II. *Penile Transplants: To Do or Not To Do: Medical, Legal, Psychosocial, and Ethical Issues of Penile Transplants for Injured Veterans in the United States*. The Internet Journal of Law, Healthcare and Ethics. 2016 Volume 11 Number 1.

DOI: [10.5580/IJLHE.47425](https://doi.org/10.5580/IJLHE.47425)

Abstract

The genitourinary injuries sustained by soldiers in Iraq and Afghanistan, which make urination, sexual intimacy and fathering a child, more difficult, can cause psychological distress for men, and may even lead to depression. To help ease the burden, Johns Hopkins University has approved a series of 60 experimental penile transplants on wounded veterans with such injuries following the first successful surgery in the US in May of 2016. This article addresses the permissibility of this procedure from the medical, legal, regulatory, sociocultural, religious and ethical perspectives. Medically, since penile transplant fits into the emerging new field of vascularized composite allograft (VCA) there are concerns about the risks for life-long immunosuppression, infection and malignancy. Other concerns include patient's expectations, donor shortage and lack of public awareness. Legally, the procedure raises issues about the informed consent of donor and recipient, compliance and privacy, as well as need to require a different set of screening procedures and criteria for donation. Psychosocially, the penis is a physical representation of masculinity and is intrinsically tied to gender identity for cisgender men, such that a loss of manhood could be psychologically damaging and socially challenging. Religiously, most major religious groups who approve of organ donation and transplantation are inclined to accept penile transplants. Ethically, the principles of respect for persons/autonomy, beneficence, and justice are used to defend the permissibility of this procedure. Finally, recommendations are offered on the cosmetic use of the procedure and inclusion of transgendered persons when it becomes the medical standard of care.

INTRODUCTION

Organ transplantation has been an acceptable form of medical treatment for many decades. For many patients, it is crucial and can be life-saving. Research has shown that one person is added to the national transplant registry approximately every ten minutes. In addition, twenty-two patients die each day waiting for organ transplantation. These statistics demonstrate how critical organ transplants have become. There is evidence suggesting that just one donor can save the lives of eight people in need of organs. Organs, such as the heart, liver, kidneys, small intestines, pancreas, and lungs, as well as tissues, such as corneas, skin, heart valves, tendons, bones, and veins, can all be donated after death. On the other hand, a healthy individual can donate a non-vital organ, such as blood products, bone marrow, or part of the liver. This is known as living donation [i].

In May of 2016, the first penile transplant performed in the United States took place in Boston, MA, at Massachusetts General Hospital. The operation was performed on Thomas Manning, a 60-year-old man who had a partial penectomy for the treatment of penile cancer. After this surgery, Manning was left with a one-inch stump, making his urination very difficult. He was also unable to have sexual intercourse, which greatly affected his relationships. The compatible donor was a deceased individual with similar skin tone. The operation appears to have been successful despite a hemorrhagic post-operative complication that was managed effectively. The surgical team is cautiously optimistic that the patient will eventually regain urinary and sexual function[ii]. The head of the surgical team, Dr. Curtis Cetrulo, a plastic and reconstructive surgeon, reported that a second patient with penile damage from burns that occurred during a motor vehicle accident will be prepared for penile transplantation as soon as a compatible donor is

identified[iii].

Johns Hopkins University in Baltimore, MD has approved an ambitious penile transplant program for the near future. The university has accepted to fund their first penile transplant surgery, at an estimated cost of \$200,000 to \$400,000, and has agreed to perform a total of 60 other such operations on wounded soldiers for this project. The Department of Veterans Affairs has also agreed to compensate for the postoperative immunosuppressive treatments. Johns Hopkins, in collaboration with the Living Legacy Foundation, the local organ procurement organization, has identified the first patient[iv]. He is a wounded soldier from the Afghanistan war, who suffered a severe penile injury from an explosion. He has been on the transplant waiting list for several months now. The success of the surgery will be carefully evaluated and monitored with the hopes that this will eventually become a standard treatment. The procedure will consist of the careful reconnection of blood vessels, nerves and other vital tissues from a new penis, which will be harvested from a deceased matched donor[v],[vi].

The Johns Hopkins Genital Transplant Program has designed this project for the benefit of wounded United States veterans who suffer from post-traumatic deformities[vii]. The Department of Defense Trauma Registry reported that between 2001 and 2013, approximately 1,300 men in the military experienced genitourinary injuries, in which they lost a segment or the entire penis. Almost all of these men were under the age of 35, and most of the injuries were sustained by homemade explosives in the Iraq and Afghanistan wars. As a result, U.S. veterans are a major focus of attention for penile transplants, especially since suicide rates are remarkably high in soldiers with such injuries. Physicians and investigators also hope that once this procedure is refined and deemed successful, military surgeons will potentially be trained to perform these transplants[viii].

Two penile transplants have already been performed in countries outside the United States. The first took place at Guangzhou General Hospital in China in 2006. This involved a 44-year-old man whose penis was accidentally severed, leaving him with a 1-inch stump that affected his ability to urinate properly and have sexual intercourse. The surgical team reported that the operation was successful as the organ regained proper blood supply and the recipient was able to urinate effectively. Despite the initial success, the

allograft was subsequently removed as a result of psychological concerns and difficulties with the management of the immunosuppression medications required to prevent rejection[ix],[x]. The second penile transplant, however, was a success and was performed in South Africa in 2014, at Tygerberg Hospital. The recipient was a 21-year-old male with an amputated penis that was the result of an infectious complication following a commonly performed ritualistic circumcision. The operation was performed after four years of intense medical research, ethical groundwork, practice on cadavers, and a search for donors. The recipient was later able to fully regain sexual and urinary function, and eventually fathered a child[xi].

The team of surgeons at Johns Hopkins believes that these transplants can be of great benefit to those whose penises cannot be repaired or rebuilt. However, there are many potential questions and concerns that will arise from this operation. Can these men acclimate to the fact that the most identifying and intimate part of their body is derived from another man?[xii] Will there be ethical and moral issues? Where will the line be drawn between this potentially life-saving and life-enhancing procedure if this becomes a routine surgical operation in the United States? Not only can the use of this surgical procedure be extended to the transgendered and transsexual individuals, but it could also potentially become a booming part of the cosmetic industry. For instance, questions may arise such as whether the recipient is able to have a choice about the size or skin tone of the penis, or whether or not there should be a priority list for this organ transplant[xiii].

This procedure has the potential for impacting the field of organ transplantation. The focus of this paper is to review the medical, legal, psychosocial, and ethical issues associated with the proposed penile transplants for injured U.S. veterans. The paper is divided into five sections. The first section will discuss the medical management, surgical technique, and the potential risks and complications of the procedure. The second section will address the various regulatory and legal issues regarding informed consent and organ donation, as they pertain to the protection of both the donor and recipient. The third section will explore the possible psychosocial consequences, and the fourth section will be an ethical analysis of the issues arising from the transplant, with a particular focus on the arguments for and against penile transplants. The final section will offer several recommendations for the future of this operation if it

becomes a standard procedure in the United States.

[i.] Facts and Myths about Transplant. (n.d.). Retrieved August 1, 2016, from <http://www.americantransplantfoundation.org/about-transplant/facts-and-myths/>

[ii] First Genitourinary Vascularized Composite Allograft (Penile) Transplant in the Nation Performed at Massachusetts General Hospital. (2016, May 16). Retrieved July 11, 2016, from <http://www.massgeneral.org/News/pressrelease.aspx?id=1937>

[iii] Grady, D. (2016b, May 16). Man Receives First Penis Transplant in the United States. *The New York Times*. Retrieved from <http://www.nytimes.com/2016/05/17/health/thomas-manning-first-penis-transplant-in-us.html>

[iv] Q&A: Penile Transplantation | Johns Hopkins Comprehensive Transplant Center. (n.d.). Retrieved August 12, 2016, from http://www.hopkinsmedicine.org/transplant/news_events/penis_transplant_qa.html

[v] Grady, D. (2015, December 6). Penis Transplants Being Planned to Help Wounded Troops. *The New York Times*. Retrieved from <http://www.nytimes.com/2015/12/07/health/penis-transplants-being-planned-to-heal-troops-hidden-wounds.html>

[vi] Grady, D., supra note iii.

[vii] Q&A: Penile Transplantation | Johns Hopkins Comprehensive Transplant Center, supra note iv.

[viii] Grady, D., supra note iii.

[ix] First Genitourinary Vascularized Composite Allograft (Penile) Transplant in the Nation Performed at Massachusetts General Hospital. (2016, May 16), supra note ii.

[x] Sample, I. (2006, September 17). Man rejects first penis transplant. Retrieved May 21, 2016, from <http://www.theguardian.com/science/2006/sep/18/medicineandhealth.china>

[xi] Bateman, C. (2015a). World's first successful penis transplant at Tygerberg Hospital. *South African Medical Journal = Suid-Afrikaanse Tydskrif Vir Geneeskunde*, 105(4), 251–252.

[xii] Grady, D., supra note v.

[xiii] Zhang, L.-C., Zhao, Y.-B., & Hu, W.-L. (2010). Ethical issues in penile transplantation. *Asian Journal of Andrology*, 12(6), 795–800. <https://doi.org/10.1038/aja.2010.88>

MEDICAL AND SURGICAL APPROACH

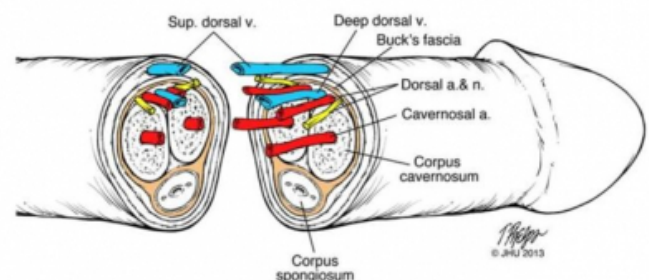
The penile transplant operation is extremely complex and challenging. As demonstrated by the transplant team at Massachusetts General Hospital, meticulous pre-planning and coordination of many resources and expertise is required to complete this major undertaking. Contingency plans must be put in place in anticipation of unexpected outcomes. Additionally, various surgical experts are needed to perform the operation. These include the urologist who is intimately familiar with the anatomy and functions of the genitourinary and male sexual organs, a plastic and reconstructive surgeon who provides the skills and expertise in microsurgical techniques, and a transplant surgeon who can offer the experience and knowledge of the transplant process.

Penile transplantation entails the joining of a donor penile

composite graft to a recipient penile stump. Both tissues need to be prepared with surgical debridement of unwanted tissues and exposure of vital vessels and nerves. The goal is to reconstruct a naturally appearing external genitalia, and to reestablish urinary, ejaculatory and sexual function[i.]. The indication for penile transplantation and degree of tissue transplanted may greatly influence the surgical approach and functional expectations of the transplanted graft.

The penis is a dynamic organ with the physiological roles of urinary transport and sexual function. This requires a complex architecture incorporating an extensive vascular network and an intricate arrangement of nerves that provide both sensory and functional enervation to the organ. There are three critical vascular territories: the glans (tip of penis) and corpus spongiosum (inferior portion of the shaft surrounding the urethra), the corpora cavernosa (two elongated cylinder-like structures that make up the bulk of the penile shaft), and the penile skin[ii]. It is the surge of blood flow into the erectile tissue of the corpora cavernosa that provides the rigidity during sexual arousal. During transplantation all three of these territories need to be re-established to maximize graft perfusion and function. The small caliber of these vessels and their paired nature requires at least six microvascular arterial anastomoses. Another vein on the dorsal aspect of the shaft (the deep dorsal vein) must also be anastomosed to provide sufficient venous drainage away from the graft[iii]. Additionally, the thickened fascial layers surrounding the corpora cavernosa needs to be carefully approximated to create the elongated cavity required for vascular engorgement and rigid erections. Lastly, the transplant is completed by adjoining the corpora spongiosum and urethra for urinary and ejaculatory functions, and the skin to restore proper appearance.

Figure 1
Penile anatomy[iv]



Urinary and semen transport is established through the graft by surgically approximating the urethral ends. Tactile

sensation of the penis is provided by two dorsal nerves. They need to be joined together using a microsurgical approach. The parasympathetic nerves, which provide the signaling required for erection, and the sympathetic nerves, responsible for causing softening following ejaculation, are often too small to be reliably identified and manipulated[v]. Although it is possible that spontaneous natural growth and reinnervation of these nerves may occur over time, erections without them could take place if the recipient's cavernosal structures are intact and can initiate vascular engorgement. It is then feasible that this can be propagated to the transplanted graft and result in sufficient erectile rigidity for sexual intercourse. This outcome is supported by initial reports of erectile function achieved by the recipient of the first successful human penile transplantation[vi]. According to the Johns Hopkins transplant team, nerves can potentially grow as much as one 1 mm per day. At this rate, they anticipate that the newly transplanted tissue could achieve full function between six and twelve months after the procedure[vii]. However, it is unclear how transplantation and immunotherapy will affect erection physiology[viii].

Given the complexity and the many unknowns of this new operation, it is inevitable that unexpected complications and adverse events will occur. There are many potential immediate and delayed risks. Early complications include infection of the surgical wound and lack of vascular perfusion to the graft. This could lead to partial or total destruction of the new organ. Experience with penile transplantation following amputation has demonstrated that break down and sloughing of the implanted penile skin commonly occurs due to insufficient passive blood perfusion and new vessel formation. Although the graft structures and skin eventually bridge across and blend in with the corresponding tissues of the stump, the resulting organ may be cosmetically unpleasant and distressing for the patient in the interim[ix],[x]. Acute rejection, a grave concern during the immediate postoperative recovery period, needs to be addressed promptly. Cardiovascular complications such as deep vein thrombosis, pulmonary embolism and myocardial infarction are typically associated with prolonged operative times, especially in patients with a history of obesity, hypertension, dyslipidemia, and hyperglycemia.

Delayed complications, on the other hand, could occur a few months or many years later. One of the most important concerns in any transplant is immune rejection. The recipient's immune system naturally mounts a response

aimed at destroying the foreign graft. Consequently, immunosuppression has become vital for the survival of the graft. Many immunosuppressive agents are typically utilized to prevent rejection. Induction drugs, such as CD3 monoclonal antibodies and anti-thymocyte globulins, are typically given at the time of transplant, while maintenance drugs such as steroids, calcineurin inhibitors and antiproliferative agents are used for long term suppression[xi],[xii]. Such agents are used in penile transplants and are very similar to those used in kidney and other transplants. They can have their own adverse side effects, but some newer agents can actually be beneficial in this case, as they are known to be potent agents for nerve regeneration and growth[xiii],[xiv]. The weakened immunity associated with the use of these agents can also lead to infections, organ damage and certain types of cancer. Penile transplant patients will require a lifelong routine of immunosuppressant medications, imposing a great risk to the patient's quality of life[xv],[xvi]. Physicians at Johns Hopkins have suggested performing a bone marrow infusion from the donor to the recipient 10-14 days after the operation. This could potentially lessen the overall number of lifelong anti-rejection drugs the patient would need to take[xvii].

Other potential adverse effects that one would also anticipate include the narrowing of the urethra leading to obstruction of the urinary flow, scarring, and poor blood flow within the corpora cavernosa. This results in inadequate erections or penile curvature, and poor skin healing from lack of blood flow or infection causing disfigurement and poor appearance. Penile length and skin tone should also be seriously assessed and considered during preoperative screening as they could have a significant long-term psychological and functional impact on the recipient.

In summary, short and long term expectations following penile transplants are difficult to predict. The most important immediate goal is to assure graft survival through adequate blood flow and prevention of acute rejection. Restoration of urinary, ejaculatory, and sexual functions along with a cosmetically acceptable appearance are important long-term expected outcomes. The success of such is determined by continuous monitoring and proper medical management of adverse events, the degree of nerve regeneration, and minimization of rejection. Finally, if the testes are intact and have not been damaged by the genitourinary injury, fathering children remains a hypothetical possibility[xviii].

Penile Transplants: To Do or Not To Do: Medical, Legal, Psychosocial, and Ethical Issues of Penile Transplants for Injured Veterans in the United States

[i.] First Genitourinary Vascularized Composite Allograft (Penile) Transplant in the Nation Performed at Massachusetts General Hospital, *supra* note ii.

[iii] Tuffaha, S. H., Sacks, J. M., Shores, J. T., Brandacher, G., Lee, W. P. A., Cooney, D. S., & Redett, R. J. (2014). Using the Dorsal, Cavernosal, and External Pudendal Arteries for Penile Transplantation. *Plastic and Reconstructive Surgery*, 134(1), 111e–119e. JOUR. <https://doi.org/10.1097/prs.0000000000000277>

[iii] Walsh, Retik, Stamey, & Vaughan. (1992). *Campbell's Urology* (6th ed., Vol. 1). W. B. Saunders Company.

[iv] How Does A Penis Transplant Work? (n.d.). Retrieved November 23, 2016, from <http://www.popsoci.com/how-does-penis-transplant-work>

[v] Walsh, *supra* note xvi.

[vi] Bateman, C., *supra* note xi.

[vii] Q&A: Penile Transplantation | Johns Hopkins Comprehensive Transplant Center, *supra* note iv.

[viii] Sopko, N. A., Matsui, H., Lough, D. M., Miller, D., Harris, K., Kates, M., ... Bivalacqua, T. J. (2016). Ex Vivo Model of Human Penile Transplantation and Rejection: Implications for Erectile Tissue Physiology. *European Urology. JOURNAL ARTICLE*. <https://doi.org/10.1016/j.euro.2016.07.006>

[ix] Dellon, A. L., Hashemi, S. S., Tollstrup, T. H., Tuffaha, S. H., Budihardjo, J. D., Sarhane, K. A., ... Redett, R. J. (2014). Expect Skin Necrosis following Penile Replantation. *Plastic and Reconstructive Surgery*, 134(6), 1000e–1004e. JOUR. <https://doi.org/10.1097/prs.0000000000000901>

[x] Jezior, J. R., Brady, J. D., & Schlossberg, S. M. (2001). Management of Penile Amputation Injuries. *World J Surg*, 25(12), 1602–1609. JOUR. <https://doi.org/10.1007/s00268-001-0157-6>

[xi] Gabardi, S., Martin, S. T., Roberts, K. L., & Grafals, M. (2011). Induction Immunosuppressive Therapies in Renal Transplantation. *American Journal of Health-System Pharmacy*. Retrieved from <http://www.medscape.com/viewarticle/736426>

[xii] Immunosuppressants. (2015, December 24). Retrieved November 23, 2016, from <https://www.kidney.org/atoz/content/immuno>

[xiii] First Genitourinary Vascularized Composite Allograft (Penile) Transplant in the Nation Performed at Massachusetts General Hospital, *supra* note ii.

[xiv] Gold, B. G., Katoh, K., & Storm-Dickerson, T. (1995). The Immunosuppressant FK506 Increases the Rate of Axonal Regeneration in Rat Sciatic Nerve. *The Journal of Neuroscience*. Retrieved from <http://www.jneurosci.org/content/jneuro/15/11/7509.full.pdf>

[xv] Bichu, P., & Chaudhary, K. (2012). Non-infectious complications of immunosuppressant medications in renal transplant patients. *Current Clinical Pharmacology*, 7(4), 254–262.

[xvi] Zhang, L.-C., *supra* note xiii.

[xvii] Q&A: Penile Transplantation | Johns Hopkins Comprehensive Transplant Center, *supra* note iv.

[xviii] Q&A: Penile Transplantation | Johns Hopkins Comprehensive Transplant Center, *supra* note iv.

REGULATORY AND LEGAL ISSUES

A shortage in viable organs for transplantation has long been a prevalent problem and public health issue in the United States. For instance, as of June 2016 there are more than 20,000 Americans in need of a tissue or organ transplant, and are currently on a waiting list[i.]. Legislation and policies such as the National Organ Transplant Act of 1984 and the Uniform Anatomical Gifts Act (UAGA) have been

enacted to address this shortage, develop regulations, and protect the individuals involved[ii],[iii]. Organizations and networks such as the Organ Procurement Transplantation Network (OPTN) and the United Network for Organ Sharing (UNOS) have been established to increase awareness, improve the donor registration process, facilitate the procedure of matching donors to recipients, and improve communication between organ procurement organizations and hospitals[iv],[v]. Consequently, organ donation has become widely regulated in all U.S. states.

The success of solid organ transplants has led many transplant centers to apply the process to other nontraditional body parts. This new process is called vascularized composite allotransplantation. This involves the transfer of a donated body part from compatible donors to recipients as a single functional unit. This unit is called a vascularized composite allograft (VCA). The transplanted organ, such as a face, hand or penis, is a “composite” of essential tissue structures such as skin, muscle, nerves, and blood vessels[vi]. This field is in its early stages of development, although interest in this new discipline is rapidly growing. Despite encouraging early results, many challenges remain such as the need for life-long immunosuppression for graft survival, the potential risks to the recipient, including infection and malignancy, donor shortage, and lack of public awareness. As a result, a different set of screening procedures and criteria for donation and transplantation have been established in preparation for this emerging new field[vii].

In July 2013, the National Organ Transplant Act of 1986 was amended by the U.S. Department of Health and Human Services recognizing VCAs as organs. This definition of “organs” is based on nine criteria that were published in the Final Rule[viii],[ix]. Some of the body parts that fit the definition included face, limbs, larynx, and abdominal wall[x]. In 2014, the OPTN assumed responsibility for the oversight and the development of policies regarding VCA transplantations. In June of 2014, OPTN and UNOS approved the first national policies and bylaws related to VCAs[xi]. Since then these policies and bylaws have required additional alterations[xii]. In December of 2015, the list of body parts covered by the policies had to be expanded and revised to include genitourinary organs, such as uterus, internal and external genitalia (male and female) and urinary bladder[xiii].

Most VCA organ donations fall under the category of

reconstructive or non-reconstructive. Reconstructive, also known as “restorative,” vascularized composite allotransplantation procedures involve transplanting certain organs, such as hand or face, in order to “restore musculoskeletal function and/or body form to the affected recipient in the setting of trauma, tumor, infection, and congenital differences”[xiv]. Conversely, non-reconstructive, also known as “non-restorative,” VCA transplantation restores function of a non-vital organ to an otherwise healthy patient. Examples of this are uterine and penile transplants, in which the missing non-essential function is reproductive. The benefits of VCA organ transplantation are also considered life-changing, while those for solid organ transplants are generally life saving[xv].

The process for vascularized composite allotransplantation is comparable to solid organ transplantation for the most part. Because of the complexity of the operation, the many unknowns, and the potential psychological impact associated with this new field, preparation for a transplant requires a very rigorous evaluation process. This includes more comprehensive screening procedures, an in-depth psychological evaluation, more explicit consent, and a specified assessment of the donor’s physical characteristics (e.g. skin tone or size)[xvi],[xvii].

The current established registration process for organ donation does not contain a specific consent for vascularized composite allotransplantation. The OPTN emphasized the importance of a separate authorization process for VCA organ donations to insure transparency and to provide more specific information in the consent process. In December of 2014 the OPTN approved and published specific guidelines regarding this authorization process. First, consent for VCA donation should not be assumed and OPOs must seek a separate consent, other than the consent for organ donation authorized by the donor prior to their brain death. Second, this consent must be obtained from an authorized individual, such as family or next of kin. Third, asking for consent for a VCA donation should not negatively influence or jeopardize the authorization for a life saving solid organ donation[xviii],[xix].

Much of our knowledge and understanding of VCA organ donation is derived from research and clinical experience from solid organ transplants. A major difference between the two is that VCAs are usually performed in healthier individuals, which raises many new questions including the

long-term effects of immunosuppressive medications, and psychological impact in an otherwise relatively healthy recipient.

[i.] Organ Procurement and Transplantation Network. (n.d.). U.S. Department of Health & Human Services. Retrieved from <https://optn.transplant.hrsa.gov>

[ii] Anatomical Gift Act (2006) Summary. (2016). Retrieved June 23, 2016, from [http://www.uniformlaws.org/ActSummary.aspx?title=Anatomical%20Gift%20Act%20\(2006\)](http://www.uniformlaws.org/ActSummary.aspx?title=Anatomical%20Gift%20Act%20(2006))

[iii] Organ Procurement and Transplantation Network (OPTN) Charter. (2004, June 24). U.S. Department of Health & Human Services.

[iv] [organdonor.gov](http://www.organdonor.gov) | Legislation & Policy. (2011, April 11). [html]. Retrieved June 20, 2016, from <http://www.organdonor.gov/legislation/>

[v] Organ Procurement and Transplantation Network (OPTN) Charter, supra note xxxiv.

[vi] Bueno, E. M., Diaz-Siso, J. R., Sisk, G. C., Chandawarkar, A., Kiwanuka, H., Lamparello, B., ... Pomahac, B. (2013). Vascularized composite allotransplantation and tissue engineering. *The Journal of Craniofacial Surgery*, 24(1), 256–263. <https://doi.org/10.1097/SCS.0b013e318275f173>

[vii] Brandacher, G., Sachs, D. H., & Lee, W. P. A. (2014). Inaugural Issue of VCA-Vascularized Composite Allotransplantation. *Vascularized Composite Allotransplantation*, 1(1-2), 1–2. <https://doi.org/10.4161/23723505.2014.973775>

[viii] McDiarmid, S. V., Levin, L. S., & Lusk, R. S. (2016). Vascularized Composite Tissue Allografts (VCA): the Policy Side. *Current Transplantation Reports*, 3(1), 50–56. <https://doi.org/10.1007/s40472-016-0094-9>

[ix] Rahmel, A. (2014). Vascularized Composite Allografts: Procurement, Allocation, and Implementation. *Current Transplantation Reports*, 1(3), 173–182. <https://doi.org/10.1007/s40472-014-0025-6>

[x] Rahmel, A., supra note xl.

[xi] The Status of Vascularized Composite Allograft Allocation. (2014, November 11). Retrieved from <https://optn.transplant.hrsa.gov/news/the-status-of-vascularized-composite-allograft-allocation/>

[xii] McDiarmid, S., supra note xxxix.

[xiii] Wholley, C. (n.d.). List Covered Body Parts Pertaining to Vascularized Composite Allografts (VCAs). U.S. Department of Health & Human Services. Retrieved from https://optn.transplant.hrsa.gov/media/1241/06_list_vca.pdf

[xiv] VCAs from living donors. (2015, June 2). U.S. Department of Health & Human Services. Retrieved from [https://optn.transplant.hrsa.gov/resources/by-organ/vascular-composite-allograft/vcas-from-living-donors/#Reconstructive=](https://optn.transplant.hrsa.gov/resources/by-organ/vascular-composite-allograft/vcas-from-living-donors/#Reconstructive)

[xv] Brandacher, G., supra note xxxviii.

[xvi] Q&A: Penile Transplantation | Johns Hopkins Comprehensive Transplant Center, supra note iv.

[xvii] Understanding Allografts: What They are and the Role They’ll Play in Your Surgery. (2016). Retrieved from https://www.mtf.org/tissue_recipients.html

[xviii] McDiarmid, S., supra note xxxix.

[xix] Rahmel, A., supra note xl.

SOCIOCULTURAL ISSUES

Religious Groups

Organ donation is an incredible act of corporal charity. Most of them require brain death of the donor prior to transplantation, but many organs and tissues can also be gifted by living donors. Consequently, most religious groups have developed tenets regarding morality and ethics of organ donation and transplantation. With the advent of the penile transplant, there is an additional component of sexuality which complicates the moral determinations of religious organizations. Very little is known about each major faith group's opinion on penile transplants; however, there are doctrines related to organ donations and general sexuality. Through the combination of both fields, it is the hope of this section to extrapolate and elucidate their possible opinions regarding the novel penile transplant.

The Catholic Church has favored organ donation, with the past three popes lauding those who legally donate their organs. Pope Francis most recently referred to organ donation as a "testimony of love for our neighbor"[i]. His opinion is in accordance with the Catechism of the Catholic Church, which states that "Organ donation after death is a noble and meritorious act and is to be encouraged as an expression of generous solidarity"[ii]. In terms of sexuality, the Catholic Church's stance has been relatively stagnant. Within the context of marriage, a man and a woman may have sexual intercourse as a means to procreate and to grow in union with one's partner[iii].

One of the main goals of the penile transplantation is to restore sexual function to the recipient's damaged or missing organ. In this sense, it is still in accordance with natural law, because post-transplant patients will be able to use their bodies as they could before and as nature intended. So long as the patient remains chaste until marriage, and once married uses his newly transplanted penis monogamously for both procreation and union with his wife, it can be considered permissible by the Catholic Church.

Judaism shares the same views regarding the altruism of organ donation. "Transplantation does not desecrate a body or show lack of respect for the dead, and any delay in burial to facilitate organ donation is respectful of the decedent. Organ donation saves lives and honors the deceased"[iv]. Judaism also shares similar ideals on sexuality. Sex within the context of marriage is permissible as it serves the purpose of procreation and union. Consequently, the same argument used above can be made for allowing penile transplants.

Islam has also approved organ transplantation during the Islamic Fiqh Council, assuming that the operation meets the requirements of beneficence of the recipient, non-maleficence of the donor, voluntary donation, and medical necessity[v]. According to the Quran, Islam has a rather sex-positive viewpoint, stating that sex is not something to be suppressed and that sex within a marriage is more than a means for procreation[vi]. These views are also similar to those of the Catholic Church, and the same argument can be made to surmise the approval from Muslim officials.

Psychosocial

The penis is undoubtedly an important organ of the male body; not only does it serve as a means to urination, intercourse, and sexual reproduction, but it also has profound psychological relevance. For many men, their sense of manhood derives consciously or subconsciously from the presence and appearance of their penis[vii]. For these men, the penis is an organ that gives them a sense of self. Unlike kidney and liver transplants, the organ is visible, which makes it personal and unique. Damage or loss of a penis is more than just a physical injury. It can be psychologically devastating, resulting in the feeling of loss of masculinity and shame. This could ultimately lead to negative effects on family and marital stability[viii].

Most of the men slated for the penile transplant have had either a partial or total penectomy due to trauma or from penile carcinoma. In a Brazilian study that evaluated the pre and postoperative sexual function for partial penectomy patients, there was a significant decrease in self-reported erectile function, orgasmic function, sexual desire, intercourse satisfaction, and overall satisfaction during intercourse. Only six patients out of eighteen sustained their degree of sexual satisfaction postoperatively[ix]. Six patients stopped having sexual intercourse entirely after the operation due to "low self-esteem and shame for the small size of the penis"[x]. A more recent dissertation from Texas Woman's University supports Romero's study, stating that 38% of participants chose abstinence postoperatively and 31% experienced marital problems as a result of the procedure. In addition, participants also mentioned that the loss of their penis "challenged their manhood"[xi]. However, it was noted that for those with familial and spousal support, recovery was comparatively easier.

The penile transplant is not considered a life-saving procedure, because it is not vital in nature. However, the loss

of one's penis clearly has the ability to hinder a man's psychosexual health and his relationship with a significant other. Consequently, because of the immense psychological toll, it certainly could be a life-changing procedure for those men who have suffered from conditions such as severe penile trauma, partial or total penectomy secondary to penile carcinoma, congenital microphalus, or gender dysphoria. These patients are definitely in need of transplantation, and from a psychological perspective they would benefit tremendously from this surgery.

Transgender/Transsexual Inclusion

Transgender individuals are those for whom their gender identity (man, woman, gender fluid) does not align with their biological sex (male, female, intersex). As a result, transgender people experience what is called gender dysphoria, which is the distress caused by the incongruence between gender identity and biological sex. Not all transgender people wish to transition via hormone therapy or gender confirming procedures. However, those that do are considered transsexual. This section will discuss the application of the penile transplant specifically for trans men (FtM), meaning those who were assigned female at birth and wish to transition to male.

Currently, the course of treatment for transsexual men includes hormone therapy (testosterone and estrogen-blockers), followed by "top surgery" or breast reduction surgery, cosmetic procedures such as vocal surgery, and "bottom surgery" which is surgery of the genitals. "Genital surgical procedures for FtM persons may include hysterectomy, ovariectomy (salpingo-oophorectomy), vaginectomy, metoidioplasty, scrotoplasty, urethroplasty, placement of testicular prostheses, and phalloplasty"[xii]. The phalloplasty, or construction of a new penis, is a very complicated procedure, which may require multiple operations and is frequently unsuccessful. As a result, many transsexual men are left with only partial function of their new phallus or knowingly opt for just the salpingo-oophorectomy instead to avoid this outcome[xiii].

It is clear that suitable treatment options for transsexual men are few and limited, and their efficacy in restoring both coital and urinary function can be inconsistent and unreliable. While the first penile transplant in South Africa appeared to have succeeded in providing the patient with return of sensation and urinary and sexual function, this operation would be complex in transsexual men[xiv]. An

ovariectomy, vaginectomy, and perhaps a scrotoplasty would have to be performed before a penile transplant could proceed. If successful, this advanced treatment approach could become the newest and most efficacious option for transsexual men. Assuming there are no major technical differences between a penile transplant for injured cisgender men and transsexual men, transsexual men are equally qualified and deserving of this procedure from a medical perspective. In addition, it has been shown that the success of the current gender confirming surgical procedures is directly related to the reduction of gender dysphoria in transsexual patients[xv]. Therefore, this could not only be medically effective, but also the most psychologically advantageous option.

[i.] Finger Lakes Donor Recovery Network. (2014, October 11). Pope Francis: Organ donation is a "testimony of love for our neighbor." Retrieved from <http://www.donorrecovery.org/2014/10/pope-francis-supports-organ-donation/>

[ii] Catholic Church. (1997). *Catechism of the Catholic Church: with modifications from the editio typica*. New York: Doubleday.

[iii] Ibid.

[iv] US Department of Health and Human Services. (2016). Retrieved from <http://www.organdonor.gov/about/religiousviews.html>

[v] Muslim World League and Islamic Fiqh Council. (1977, 2006). *Resolutions of Islamic Fiqh Council*. Retrieved from <http://themwl.org/downloads/Resolutions-of-Islamic-Fiqh-Council-1.pdf>

[vi] Ahlul Bayt DILP. (1995, 2016). Chapter Two: The Islamic Sexual Morality (1) Its Foundation. Retrieved from <https://www.al-islam.org/marriage-and-morals-islam-sayyid-muhammad-rizvi/chapter-two-islamic-sexual-morality-1-its-foundation>

[vii] Sample, I. (2006, September 17). *supra* note x

[viii] Grady, D. (2015, December 6). *supra* note v

[ix] Romero, F. R., Pereira dos Santos Romero, K. R., Elias de Mattos, M. A., Camargo Garcia, C. R., De Carvalho Fernandes, R., & Cardenuto Perez, M. D. (2005). Sexual Function After Partial Penectomy For Penile Cancer. *Elsevier Science Inc*, 66, 1292–1295.

[x] Ibid.

[xi] Gordon, H. (2013). *The Lived Experience of Men with Penile Cancer*. Texas Woman's University, Ann Arbor. Retrieved from <http://search.proquest.com.ezproxy2.library.drexel.edu/docview/1496772599/fulltextPDF/57499FE67AAB4A4DPQ/1?accountid=10559>

[xii] Selvaggi, G., Dhejne, C., Landen, M., & Elander, A. (2012). The 2011 WPATH Standards of Care and Penile Reconstruction in Female-to-Male Transsexual Individuals. *Advances in Urology*, 2012, 13. <https://doi.org/10.1155/2012/581712>

[xiii] Ibid.

[xiv] Bateman, C. (2015b). World's first successful penis transplant at Tygerberg Hospital. *S Afr Med J*, 105(4), 251. *JOUR*. <https://doi.org/10.7196/samj.9602>

[xv] Selvagii, G. (2012) supra note lxiii

ETHICAL ISSUES

The proposed penile transplant operations for veterans with genitourinary injuries raise many ethical concerns. First, do the physical risks outweigh the benefits of this experimental and non-life saving transplant? The risk-benefit calculus demands that the potential benefits of a procedure be weighed against its risks and disadvantages. Besides the possible complication that may arise from this complex procedure, there could be a rejection of the transplanted penis and the recipient may need to be on immunosuppression medication. There is 15-18% risk of rejection in the first year of the transplant, which may necessitate the need for lifelong immunosuppressant[i.],[ii]. Immunosuppression drugs have inherent side effects, which include diminished immunoresponse, propensity to dispose patients to opportunistic infections, organ damage, diabetes, and lymphoma[iii],[iv][v]. The question then follows: Are the benefits of regaining urinary and sexual functions, and the restoring of psychosocial identity, commensurate with the risks involved?

The risk-benefit ratio also invokes the ethical debate about therapy versus enhancement. The penis is not a “life-saving” or “life-sustaining” organ, such as the heart, kidney or liver. Rather, it is classified as “life-enhancing”, because it improves the quality of the recipient’s life[vi],[vii]. Are the injured veterans willing to bear these potential risks, for such a nonlife-saving procedure? Is it justified for medical professionals to offer such a novel procedure to the veterans, considering the inherent risks? In response to the latter issue, some opine that the proposed penile transplant for injured veterans fall under the normal therapeutic category, because the intention is to return a person to normal urinary and sexual function after a trauma, and likened it to rebuilding a breast for a woman after mastectomy[viii]. Approximately 1,300 male service members sustained life-altering urogenital injuries between 2001 and 2013. For these men, urinary and sexual functions were made difficult, and one could argue that these proposals are primarily therapeutic, because the injured patients want to be made whole again[ix],[x].

The second ethical concern is the informed consent process. Typically, for every procedure, surgeons fully disclose the risks and benefits in a manner that the patient understands, in order for the patients to make informed decisions to consent or refuse therapy/treatment. But in the case of penile

transplants, the paucity of information about this novel procedure makes the full disclosure component of informed consent problematic. There are things we do not know and need to learn about the procedure to prove that it is safe and effective. So far only three of these procedures have been performed, in China, South Africa and U.S, which make John Hopkins’s proposed transplant with the veteran the fourth. The available information so far on penile transplants indicates that it involves a plethora of anatomic structures, multiple reconstructive techniques, and complicated pharmacological treatments[xi]. How can we guarantee that the veterans fully understand this complex information to give a valid and informed consent? Given the emotional trauma these wounded servicemen deal with daily, and the propensity to suffer from PTSD (which can constitute mental instability), are they in the frame of mind and thoughts to evaluate the risks against the benefits before giving their consents to such an invasive procedure?

The third ethical concern is family consent and public’s attitude toward penile transplants. The primary source of graft donation is from deceased donors. Legally, in the U.S., additional and specific consent is required from families for the donation of a deceased family member’s organs, such as hands, faces and penises. Would families be willing to donate the penises of deceased loved ones? Members of the general public already have concerns and reservations about graft donations for hand and face transplants which belong to the class of vascularized composite allotransplantation with penile transplant[xii],[xiii]. Will penile transplants be treated differently? Given the sensitivity and symbolism of the penis, and the fact that it is tied to ideas of masculinity[xiv], it is fair to assume that at the initial stage the public may have concerns about it and be unwilling to donate. Additionally, the thought of having the body of a deceased loved one without his penis may be unfathomable for some families to consent. For instance, it took years to find a donor in the South African penile transplant, and when the surgeons identified one, the family of donor insisted on reconstructing a phallus to replace the one transplanted to the recipient [xv],[xvi]. Asking a grieving family if they would want to donate the penis of their husband, son or brother may be a difficult task, unlike making similar requests for kidneys, liver, heart and other tissues. If the request for family consent is not handled properly by the Organ Procurement and Transplantation Network, the sensitivity and symbolism of the penis has the potential for scaring families away from donation.

Against the backdrop of the above concerns, is it ethical then to proceed with penile transplant for wounded veterans?

Yes; a case could be made for the permissibility of penile transplants for veterans, based on the ethical principles of respect for persons/autonomy, beneficence and justice.

Respect for persons entails the right of a person to freely exercise self-determination and to be treated with fundamental dignity and respect. The principle of respect for persons has two integral but separate moral requirements: the requirement to acknowledge autonomy and the requirement to protect those with diminished autonomy[xvii]. In other words, “to respect autonomous agents is to acknowledge their right to hold views, to make choices, and to take actions based on their personal values and beliefs”[xviii]. Competent patients have a common-law and constitutional right to decide whether to accept or refuse a proposed treatment. This right extends to full and active participation in health decisions that affect their lives, even if those decisions may be wrong or counterproductive. Every competent adult, including injured veterans, have this right of autonomy. Therefore, if the surgical team at John Hopkins has duly followed the 10 guidelines that emerged in 2006 after the transplant in China, which includes physical and psychological evaluations for potential recipients, approval from the hospital’s Institutional Review Board (IRB), and obtained informed consent from the recipients, then surgery should proceed[xix]. It is the gold standard in clinical practice and biomedical research that competent adults choose or decide on any form of medical procedure (including experimental procedures and clinical trials, such as penile transplant) available to them. Injured veterans should not be denied this right of self-determination. John Hopkins has established some safeguards for this series of operations. For example, patients would only be considered for the penile transplant if they do not qualify for more traditional types of genital reconstruction, are mentally healthy, have good family support, understand the risks (including need for additional surgeries and lifetime use of immunosuppressive drugs), and have spousal involvement[xx]. Denying competent veterans the opportunity to be part of this experimental procedure violates the ethical principle of respect for persons.

The principle of beneficence entails the moral obligations to confer benefits and to prevent, remove, or minimize harm and risk to others. It also incorporates weighing an action’s possible goods against its costs and possible harms [xxi].

Beneficence, whose focus is the promotion and enhancement of the good of others, encompasses nonmaleficence, which specifically prohibits the infliction of harm, injury, or death upon others. This ethical principle traces its roots to the Hippocratic Oath that stipulates “Above all, do no harm” (primum non nocere). In clinical practice and biomedical research, this principle demands that as moral agents, physicians have an ethical responsibility to treat their patients in a way that will maximize benefits and minimize harm. Hundreds of young wounded veterans have a diminished quality of life due to the urogenital injuries they sustained at war, which makes urination, sexual intimacy and fathering a child difficult. Penile transplants hold the promise of restoring their qualities of life. It has the potential for helping these veterans not only to regain urinary functions and sexual identity, but to also boost their psychosocial persona, jeopardized by the loss of their penises[xxii]. Given the prospects, potentials, and positivity expressed by the surgical team that those who meet the selection criteria will adapt to it and accept the graft, the principle of beneficence demands that we offer the procedure to veterans [xxiii],[xxiv]. Similarly, to minimize the need for immunosuppression medications and reduce the risks of cancer, graft-host disease, and rejection, the surgical team will employ a protocol originally developed for hand transplants that uses donor-derived bone marrow[xxv],[xxvi]. The efforts by the surgical team to minimize the risks of the procedure pass the test of nonmaleficence. Therefore, arguing for a total rejection of the procedure based solely on the risks, without looking at the benefits and improved quality of life for these wounded veterans is a violation of the principle of beneficence.

Finally, the principle of justice recognizes that each person should be treated fairly and equitably, and be given his or her due. Distributive justice requires that everyone receive equitable access to the basic health care, which is necessary for living a fully human life [xxvii]. Hundreds of wounded soldiers who suffer from urogenital injuries were robbed of their normal male functions. They received these injuries while fighting to defend the freedom of Americans and people all around the globe. These young veterans had plans of engaging in relationships and raising families before deployment, but returned with devastating injuries, including loss of penises, which is quintessentially interwoven with their identity. Not only might their dreams of sexual intimacy have been shattered, but also simple actions such as urinating while standing or going into public restrooms have

become burdensome[xxviii]. Justice demands that these individuals, who have made huge sacrifices for society, be cared for by offering them a redeeming (though experimental) procedure. These injured veterans should be given the opportunity to participate in the trial that may hold a promise of restoring their masculinity, especially the capability of even fathering their own children. To deny them of this opportunity is a violation of the principle of justice.

[i.] Yuko, E. (2016). The complicated ethics of penile transplants. *The Establishment*, 1-7; Available at <http://www.theestablishment.co/2016/03/23/the-complicated-ethics-of-penis-transplants/>

[ii] Swearingen, B. et al., (2008). The science of composite tissue allotransplantation. *Transplantation*, 86(5), 627-635.

[iii] Zhang, L., Zhao, Y. & Hu W. (2010). Ethical Issues in penile transplantation. *Asian Journal of Andrology*, 12(6), 795-800.

[iv] Dunn, D. L., (1990). Problems related to immunosuppression: Infection and malignancy occurring after solid organ transplantation. *Critical Care Clinics*, 6(4), 955.

[v] Kuehn, B. M. (2016). U.S hospitals prepare for penis transplants. *JAMA*, 315(13), 1322- 1324.

[vi] Caplan, A. L., et al. (2016). The ethics of penile transplantation: Preliminary recommendations. *Transplantation*, 1-6. Available at academia.edu.

[vii] Yuko, E. (2016). supra note lxxv

[viii] Klugman, C. (2015). Ethics of penile transplants. *Bioethics.net*. Available at <http://www.bioethics.net/2015/03/ethics-of-penile-transplants/>

[ix] Janak, J. C., Orman, J. A., Soderdahl, D. W., & Hudak, S. J. (2016). Epidemiology of Genitourinary Injuries among Male U.S. Service Members Deployed to Iraq and Afghanistan: Early Findings from the Trauma Outcomes and Urogenital Health (TOUGH) Project. *The Journal of Urology*. <https://doi.org/10.1016/j.juro.2016.08.005>

[x] Kuehn, B. M. (2016) supra note lxx

[xi] Zhang, L.-C., supra note xiii.

[xii] Denadai, R. et al., (2016). Public's knowledge and attitudes toward vascularized composite allotransplantation and donation. *Aesthetic Plastic Surgery*, 40(2), 301-308. doi: 10.1007/s00266-016-0623-z.

[xiii] Organ Procurement and Transplantation Network, supra note xxxii

[xiv] Yuko, E. (2016). supra note lxxv

[xv] Kuehn, B. M. (2016) supra note lxx

[xvi] Yuko, E. (2016). supra note lxxv

[xvii] United States. (1978). *The Belmont report: Ethical principles and guidelines for the protection of human subjects of research*. Bethesda, Md.: The Commission.

[xviii] Beauchamp, T. L., & Childress, J. F. (2009). *Principles of Biomedical Ethics*, 6th ed. New York, N.Y.: Oxford University Press.

[xix] Zhang, L.-C., supra note xiii.

[xx] Kuehn, B. M. (2016) supra note lxx

[xxi] Beauchamp, T. L. (2009) supra note lxxxiii

[xxii] Yuko, E. (2016). supra note lxxv

[xxiii] Kuehn, B. M. (2016) supra note lxx

[xxiv] Goldschmidt, D. & Kounang, N. (2016). Doctors perform first U.S. penis transplant. CNN news report, Available at <http://www.cnn.com/2016/05/16/health/first-u-s-penis-transplant/>

[xxv] Kuehn, B. M. (2016) supra note lxx

[xxvi] Schneeberger S, et al (2013). Upper-extremity transplantation using a cell-based protocol to minimize immunosuppression. *Annals of Surgery*, 257, 345-351.

[xxvii] Ascension Health. Key Ethical Principles: Principle of Distributive Justice. Available at: http://www.ascensionhealth.org/index.php?option=com_content&view=article&id=80:principle-of-distributive-justice&Itemid=171

[xxviii] Caplan, A. L. (2015). Penis transplant: Will getting donors be a problem? *Medscape*. Available at <http://www.medscape.com/viewarticle/843343>

RECOMMENDATIONS

As penile vascularized composite allotransplantation navigates through its developmental stages and matures into a successful operation, it may become a routine operation in the United States. Eventually, this procedure may expand to transsexual men in addition to just civilians with urogenital injuries (including U.S. veterans with urogenital trauma). Since there has currently been very little research published in scholarly literature evaluating penile transplantation, this operation should not be executed unless specific guidelines are set in place and publicized[i.]. Johns Hopkins has already established some guidelines for identifying potential donors. Other additional recommendations should include the following:

1. Any individual interested in organ donation should be informed about the possibility of a VCA transplant. A more precise definition of "organ donor" should also be established. Donors may not be completely aware of the organ(s) he or she is potentially donating, which could cause some concern. For instance, male donors may be reluctant to register for organ donation if they assume that their penis may be harvested. Organ donation could be classified based on the type of organ the donor is willing to provide. For example, donors can choose to be placed into one of three different categories or classifications when registering for organ donation. Class 1 donors would allow the use of only life-saving vital organs, such as the heart, lung, kidney, and liver. Class 2 would allow the use of non-life saving organs, including skin, eyes, hands, and penis. Class 3 would allow the use of all bodily parts and tissues. OPOs, hospitals, and transplant teams should have easy access to this information prior to any transplant.
2. Very specific information should be accessible to individuals and family members registering for organ donation, including information regarding

penile transplantation, in case they want to further research this option. This would include potential psychological effects on family members, cost of the procedure, benefits to recipients, and cosmetic repairs to the donated site. The Department of Motor Vehicles (DMV) should be more proactive in ensuring that potential donors are well informed during the driver's license registration process. This can be accomplished by raising awareness through public service announcements, brochures, and information on their website.

3. Consent from family and legal guardians should be obtained as detailed in the OPTN policies for VCA donation. In addition, those providing the consent should be informed that this procedure remains experimental in nature until it becomes more established. It might be beneficial to introduce a family advocate to assist in the consent process and discussion, especially when potential coercion and conflict of interest by ambitious researchers could play a role [ii],[iii].
4. Any discussion of penile transplants with potential donor or family members must not impede the process of registration or obtaining consent for other potentially life-saving solid organs, such as a kidney or heart [iv].
5. Procurement programs should provide interested families with detailed information about the transplant, including logistical and emotional support. This will ultimately make it easier for them to consent. For example, they could offer the skin grafting of the open wound following the removal of the penis, so that they are more willing and comfortable with burying the deceased without this organ. Alternatively, the option of cremation could be offered to families instead.
6. Penile transplantation could potentially fail in some patients. This could be the result of poor revascularization of the graft, a postoperative complication such as an infection, or from immune rejection. As a result, the penis may need to be removed, which could have a tremendous impact on the patient. The patient may also need to be placed back onto the transplant list for a new organ. In order to manage such medical, emotional and logistical issues, a standardized process should be put in place to provide guidance, along with access to medical and psychological counseling for these patients and their families.
7. Most major religious groups approve of organ donation and transplantation. Because of the sexual nature of the penile transplant, the tenets of sexual practice within each faith group should be examined before determining the permissibility of such a transplant. Consultation with faith leaders should be advised if the patient is concerned about the moral implications of the procedure.
8. Because of the potential implications relative to sexuality, marriage, masculinity, and overall mental health, explicit consent and an in-depth psychological evaluation of the recipient and

significant other should be carefully considered prior to penile transplantation.

9. Once the procedure for penile transplantation has been tailored to transsexual males, the procedure should be expanded to this marginalized demographic of patients, and possibly even replacing current phalloplasty options. Because the penile transplant procedure is being developed for biological males, the standard of care for transsexual males must be adjusted to meet their specific circumstances. However, once this standard is developed, they should be considered equally deserving recipients of the penile transplant.
10. Due to certain constraints such as the limited number of donors and trained surgeons for this type of transplant, use of the penile transplant as a strictly cosmetic enhancement is not advisable for the time being. Priority on the transplant list should be given to those based on medical need rather than cosmetic enhancement for physically "normal" males.

[i.] Caplan, A. L., Kimberly, L. L., Parent, B., Sosin, M., & Rodriguez, E. D. (2016). The Ethics of Penile Transplantation: Preliminary Recommendations. *Transplantation*.
<https://doi.org/10.1097/TP.0000000000001352>

[ii] Brandacher, G., supra note xxxviii.

[iii] Zhang, L.-C., supra note xiii.

[iv] Rahmel, A., supra note xl.

CONCLUSION

The penile transplant has become one of the newest frontiers in the transplant medical community. After only a few attempts, physicians have managed to successfully perform the surgery, and in doing so, appear to have restored urinary, sexual, and procreative function to their recipients. Due to the several controversial aspects of this procedure, more regulations need to be put in place before this becomes a standard operation in the United States. In addition, the specifics of the procedure, including donor/recipient matching and inclusion of certain demographics in the recipient pool, must also be confirmed as this procedure gains popularity. Ethically, this procedure is permissible via the principles of respect for persons/autonomy, beneficence, and justice. Ultimately, the penile transplant has the potential to greatly improve the physiological and psychological health of future recipients.

References

Author Information

Aloysius Ochasi, D.BE

Institute of Clinical Bioethics, St. Joseph's University
PA, USA

Nikolai Sopko, MD, PhD

The James Buchanan Brady Urological Institute and Department of Urology. The Johns Hopkins School of Medicine
Baltimore, MD, USA

Gabriella Mamo, Research Fellow

Institute of Clinical Bioethics, St. Joseph's University
PA, USA

Vincent Pepe, Research Fellow

Institute of Clinical Bioethics, St. Joseph's University
PA, USA

Arthur L. Burnett, II, M.D., M.B.A.

Department of Urology, The James Buchanan Brady Urological Institute, The Johns Hopkins Hospital
Baltimore, MD, USA