

Histoplasmosis Of The Skull Bone In An HIV Positive Patient

S Olatoke, P Olaitan, K Ojemakinde, O Olakulehin, S Fadiora

Citation

S Olatoke, P Olaitan, K Ojemakinde, O Olakulehin, S Fadiora. *Histoplasmosis Of The Skull Bone In An HIV Positive Patient*. The Internet Journal of Surgery. 2005 Volume 8 Number 1.

Abstract

Histoplasmosis is a common fungal infection endemic in many regions of America, Asia, India and Africa, with sporadic cases also occurring throughout the world. The usual manifestation of histoplasmosis is in the form of respiratory illness¹. The disease presents itself in many ways. The commonest route of infection is by inhalation and the commonest presentation is as a mild respiratory illness similar to a cold or influenza. However this infection affects the skin and bones may times presenting as a tumour. Histology usually settles the dilemma. Histopathological examination of the biopsy allows the diagnosis in 87% of the cases². The histoplasmosis represents an opportunist mycotic infection, particularly during the immunodeficiency periods. Presentation in an unusual way in an HIV patient is therefore not unexpected and physicians should be aware of this in considering the differentials of a tumour in such patients.

CASE REPORT

A 50 year old woman presented with left sided frontal swelling of six months duration. There was associated headache and pain. No history of trauma. Mass gradually increased in size with no fever or night sweat, no swelling in any other part of the body. No associated breast, neck or abdominal mass.

On examination, she was a middle aged woman, not pale afebrile, anicteric no associated peripheral lymph node enlargement. Head and neck examination revealed a fronto-parietal mass which measures about 5x10cm, circumscribed, not warmer than surrounding skin, soft, tender, attached to the skin and underlying structure, swelling was none emptying. No lymph node enlargement was observed. Other systems were essentially normal.

An assessment of metastatic lesion was made? X-ray of the skull showed an osteolytic lesion with irregular non-sclerotic margin seen in the left frontal bone. No calcification was seen. Impression of osteolytic frontal bone most probably metastatic? 1° site was also suggested.

Fine needle aspiration shows numerous organisms with thick wall and refractive properties (yeasts). The organisms show boldly with narrow base. There were numerous macrophages and polymorph nuclear cells and cellular debris at the background. Features were in keeping with fungal infection

probably Histoplasmosis duboisii.

Patient had excision biopsy done findings at which were left frontal mass measuring about 5x10cm circumscribed, soft with mucopurulent fluid. Erosion of underlying frontal-parietal bone down to the dura but with intact dura and with extension to the orbital roof. Excision was done and the wound closed after copious irrigation with saline water. Biopsy confirmed Histoplasmosis duboisii with a section with numerous round to oval retractile organisms invading the surrounding fibrous tissue with inflammatory reaction in the background. There were few multinucleated giant cells engulfing these organisms. Patient had Tablet Fluconazole 100mg daily for three months. Wound healed perfectly with no complications and patient was referred to Haematologist for management of the HIV.

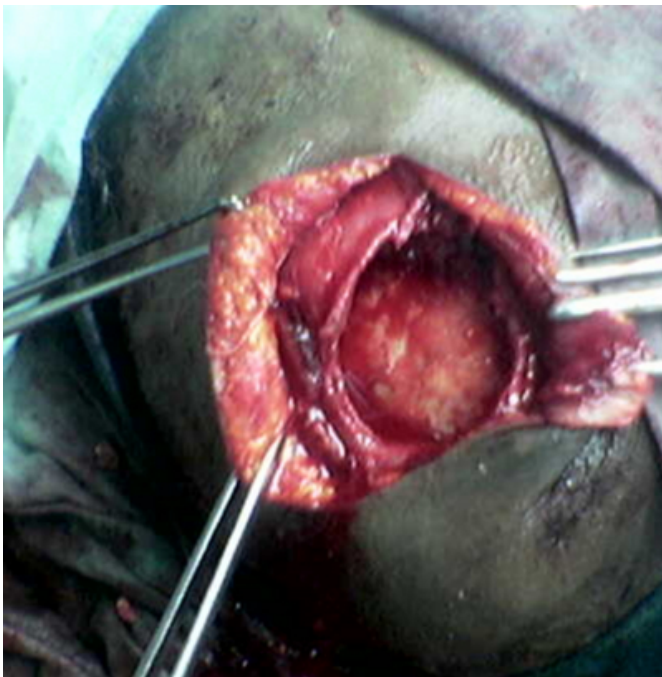
Figure 1

Figure 1: Preoperative finding of a frontal mass with a punctum.

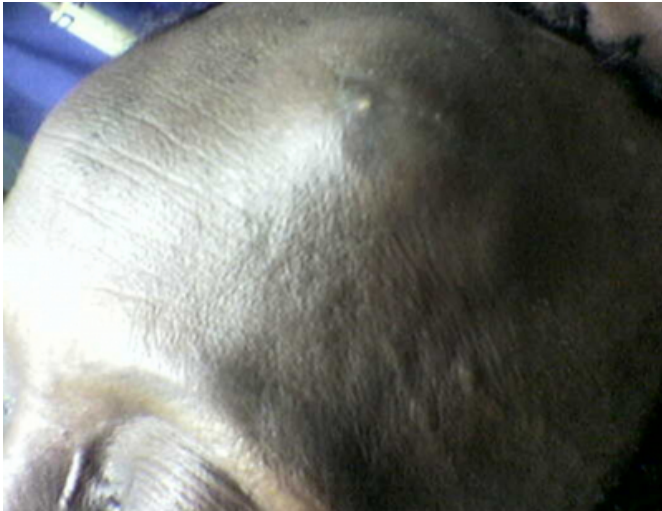

Figure 2

Figure 2: Intraoperative finding of a full thickness defect of the skull with intact dura mater.



DISCUSSION

Histoplasma is a mycotic infection due to dimorphic mushrooms. There are two forms described by Vanbrenseghrm in 1952 using morphological and clinical criteria³. The American Histoplasmosis with small yeast due to "Histoplasma capsulatum" and the African form due to "Histoplasma duboisii" with etiologic agent growing as large yeasts within giant cells.

A case of African Histoplasmosis of the skull associated with neurological deficit has been reported. There was complete recovery of neurological features after excision of the lesion followed by a course of co-trimoxazole⁴. Histoplasmosis of the maxillary bone have also been reported^{5, 6} and described as a diagnostic problem, mimicking malignant jaw tumours. Histoplasmosis has also presented as a facial tumour in a 13 year old child and diagnosis was established by histological examination of biopsy material⁷. Orbital cysts due to histoplasmosis have also been reported^{8, 9}. Fine needle aspiration for cytology was helpful in the current case with histological confirmation of the pathology after excision.

The current case is a case of Histoplasmosis duboisii of the skull with no neurological deficit and with the mass being confused for secondary/metastatic lesion in a patient with HIV infection. Excision biopsy with Fluconazole tablet led to resolution of the infection with perfect wound healing.

We conclude that Histoplastomosis duboisii should be considered as one of the differentials of skull masses, which may mimic metastases especially in an HIV/ AIDS patient with a swelling in the craniofacial area. It should also be noted that fine needle aspiration for cytology was actually adequate in making the diagnosis therefore allowing prompt diagnosis and treatment. The HIV status of this patient did not adversely affect the healing of the wound.

CORRESPONDENCE TO

Dr.P.B.Olaitan Department of Surgery, Ladoke Akintola University of Technology Teaching Hospital, Osogbo, Osun state, Nigeria. E-MAIL: emiolaitan@yahoo.com

References

1. Jain S, Koirala J, Castro-Pavia F. Isolated gastrointestinal histoplasmosis: case report and review of the literature. South Med J. 2004 Feb; 97(2): 172-4.
2. Gentilini M, Brucker G, Danis M et al: Dix cas d'histoplasme: aspects cliniques, biologiques et thérapeutiques. Ann Med Interne, 1980, 4: 209-212.
3. Khalil M A, Hassan AW, Gugnani HC: African histoplasmosis: report of four cases from northeastern Nigeria. Mycosis, 1998, 41: 293-295.
4. Ige AO, Nwosu SO, Odesanmi WO. African histoplasmosis (Duboisii) of the skull with neurological complication--a case report and review of literature. Afr J Med Med Sci. 1992 Dec;21(2):19-21.
5. N'Golet A, N'Gouoni BG, Moukassa D, Nkoua-Mbon JB. Maxillary African histoplasmosis: unusual diagnostic problems of an unusual presentation. Pathol Res Pract. 2005; 200(11-12): 841-4.
6. Daramola JO, Ajagbe HA, Abioye AA, Ogunba EO. Maxillary African histoplasmosis mimicking malignant jaw tumour. Br J Oral Surg. 1979 Mar; 16(3): 241-7.

7. Shoroye A, Oyedeji GA. African histoplasmosis presenting as a facial tumour in a child. *Ann Trop Paediatr*. 1982 Sep; 2(3):147-9.
8. Olurin O, Lucas AO, Oyediran AB. Orbital

histoplasmosis due to *Histoplasma duboisii*. *Am J Ophthalmol*. 1969 July; 68(1): 14-8.
9. Bansal RK, Suseelan AV, Gugnani HC. Orbital cyst due to *Histoplasma duboisii*. *Br J Ophthalmol*. 1977 Jan; 61(1): 70-1.

Author Information

S. A. Olatoke

Department of Surgery, Ladoke Akintola University of Technology Teaching Hospital

P. B. Olaitan

Department of Surgery, Ladoke Akintola University of Technology Teaching Hospital

K. O. Ojemakinde

Department of Morbid Anatomy, Ladoke Akintola University of Technology Teaching Hospital

O. A. Olakulehin

Department of Surgery, Ladoke Akintola University of Technology Teaching Hospital

S. O. Fadiora

Department of Surgery, Ladoke Akintola University of Technology Teaching Hospital