

Incidental Morgagni Hernia Diagnosed and Repaired at Laparoscopic Cholecystectomy

R Owen, N Kosai, J Varghese

Citation

R Owen, N Kosai, J Varghese. *Incidental Morgagni Hernia Diagnosed and Repaired at Laparoscopic Cholecystectomy*. The Internet Journal of Surgery. 2009 Volume 24 Number 2.

Abstract

Morgagni hernias form through a defect in the anterior part of the diaphragm. They are a rare form of diaphragmatic hernia. We present the case of a 57-year-old female presenting with intermittent epigastric pain and vomiting. She was previously fit and well. Examination was unremarkable. Blood tests were within normal limits. Chest radiograph revealed a slightly elevated right hemidiaphragm. Barium meal was reported as normal. Ultrasound scanning of her abdomen revealed gallstones. MRCP confirmed a normal biliary duct system. The impression from clinical history and imaging was that her symptoms were due to gallstones. She proceeded to an elective laparoscopic cholecystectomy. At surgery an incidental 10x8cm Morgagni hernia containing a significant portion of the transverse colon was identified. The hernia was reduced easily, and the defect was repaired using a 20x15cm mesh (Parietex™) fixed with staples (Protac®). This was followed by a routine cholecystectomy. Postoperatively, she made an uneventful recovery and was discharged the following day.

INTRODUCTION

At laparoscopic cholecystectomy we diagnosed a Morgagni hernia which was repaired laparoscopically with mesh during the same operation. This is the first case of incidental finding and laparoscopic mesh repair of an anterior diaphragmatic hernia in the literature.

CASE HISTORY

We present the case of a 57-year-old female presenting with intermittent epigastric pain and vomiting. She was previously fit and well. Examination and liver function tests were normal. Chest radiography revealed a slightly raised right hemidiaphragm but was reported to be normal. Ultrasound scanning of her abdomen revealed cholelithiasis. Magnetic resonance cholangiopancreatography confirmed a normal biliary duct. The impression from clinical history and imaging was that her symptoms were due to biliary colic secondary to gallstones. She proceeded to an elective laparoscopic cholecystectomy.

At surgery an incidental 10x8cm diaphragmatic hernia containing a significant portion of the transverse colon was identified protruding through the right anterior part of the patient's diaphragm (figure 1). The hernia was reduced easily laparoscopically (figure 2). The hernia sac was left in situ; but the defect was repaired laparoscopically using a 20x15cm composite mesh (Parietex™) and staples

(Protac®) (figure 3). This was followed by a routine laparoscopic cholecystectomy. No additional ports were required with two 5mm and two 10mm ports used.

Postoperatively, she made an uneventful recovery and was discharged the following day.

Figure 1

Figure 1 – Morgagni hernia defect containing loop of transverse colon

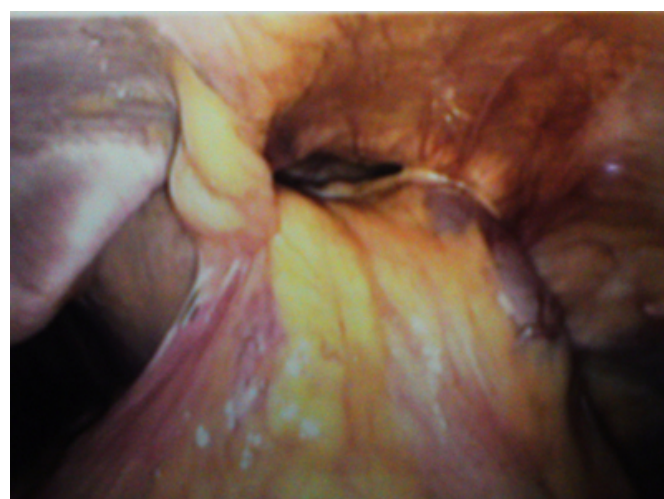

Figure 2

Figure 2 – Diaphragmatic defect (marked with blue arrows), with empty hernia sac in situ following reduction of its content (transverse colon). Large black arrow demonstrates falciform ligament

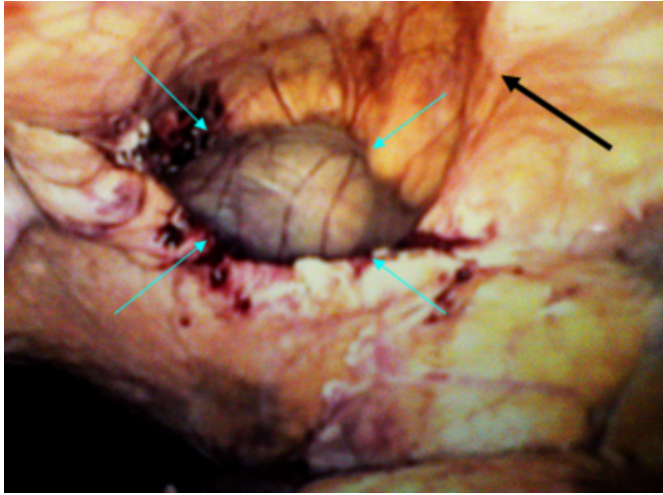
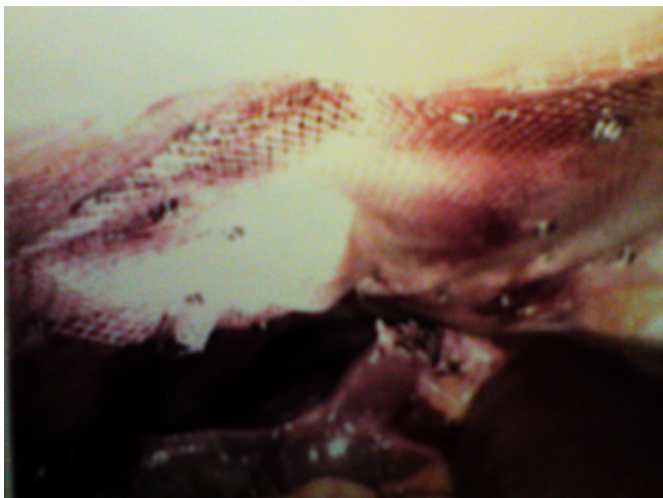


Figure 3

Figure 3 – Mesh repair of defect



DISCUSSION

Morgagni hernias account for 2% of diaphragmatic hernias. They protrude through a defect in the anterior part of the diaphragm, the majority on the right side. The defect is thought to be a result of incomplete closure of the space through which the superficial epigastric vessels pass prior to entering the rectus muscle due to a disorder in diaphragmatic differentiation¹. Morgagni hernia may present in the neonatal period with respiratory distress or later in life with non-specific gastrointestinal or respiratory symptoms. These

include upper abdominal pain, bloating, recurrent chest infection and shortness of breath. Diagnosis is made with chest radiography or ultrasound scanning. Barium study or computed tomography can confirm the diagnosis and aid operative planning². Repair is advocated due to respiratory compromise or the potential for severe complications in the event of strangulation of the hernia³.

Following reduction of the hernia into the abdomen the issue of excising the hernia sac is controversial. Leaving the sac in situ may leave a risk of fluid collection and infection as well as recurrence of the hernia⁴. Removal of the sac may lead to iatrogenic injury to pleura or pericardium. Retrospective studies have so far failed to show any significant long-term morbidity from leaving the hernia sac in situ⁵.

The role of mesh to repair the diaphragm depends on the size of the defect and the ability to successfully complete a tension-free repair. There are no reports of significant morbidity related to the use of mesh in this situation⁶.

CONCLUSION

Laparoscopic cholecystectomy is a very common operation worldwide. Knowledge of other diagnoses that may be encountered during laparoscopy is important for surgeons performing this procedure. Morgagni hernia is a rare diagnosis that may be found incidentally. We show that it is amenable to laparoscopic repair at the same operation. Resection of the hernia sac is not a mandatory part of the operation. Mesh can be used successfully if a large defect is found in keeping with tension-free principles of hernia surgery.

References

1. Chin EF, Duchesne ER: The parasternal defect. *Thorax*; 1955; 10(3): 214-9.
2. Loong TP, Kocher HM: Clinical presentation and operative repair of hernia of Morgagni. *Postgrad Med J*; 2005; 81(951): 41-4.
3. Comer TP, Clagett OT: Surgical treatment of hernia of the foramen of Morgagni. *J Thorac Cardiovasc Surg*; 1966; 52: 461-468.
4. Korkmaz M, Güvenç BH, Senel U: Minimal access surgical repair of Morgagni hernia: the fate of the unresected hernia sac. *J Laparoendosc Adv Surg Tech A*; 2007; 17(6): 833-6.
5. Akbiyik F, Tiryaki TH, Senel E, Mambet E, Livanelioğlu Z, Atayurt H: Is hernial sac removal necessary? Retrospective evaluation of eight patients with Morgagni hernia in 5 years. *Pediatr Surg Int*; 2006; 22(10): 825-7.
6. Marin-Blazquez AA, Candel MF, Parra PA, Mendez M, Rodenas J, Rojas MJ et al.: Morgagni hernia: Repair with a mesh using laparoscopic surgery. *Hernia*; 2004; 8: 70-72.

Author Information

Richard P Owen, MB ChB MRCS (Eng)

Department of Surgery, Royal Bolton Hospital

Nik R Kosai, BSc MB ChB MRCS FRCS (Gen Surg)

Department of Surgery, Royal Bolton Hospital

Joseph T Varghese, MBBS FRCS (Gen Surg)

Department of Surgery, Royal Bolton Hospital