

Situs Inversus Totalis And Laparoscopic Cholecystectomy: Are They Compatible?

V G, A J, F G, S G, P E

Citation

V G, A J, F G, S G, P E. *Situs Inversus Totalis And Laparoscopic Cholecystectomy: Are They Compatible?*. The Internet Journal of Surgery. 2009 Volume 26 Number 1.

Abstract

The aim of this presentation is to show that laparoscopic cholecystectomy (LC) is possible in a patient with situs inversus totalis (SIT). SIT is rare condition (1:5000-1:10000 of hospital admissions) and till now a small number (43) of laparoscopic cholecystectomies in such patients has been reported worldwide. In our material of 5569 laparoscopic cholecystectomies we have only one patient with SIT. The reported case was a 66-year-old woman with recurrent episodes of cholecystitis and an already diagnosed SIT. All theater equipment was placed in a mirrored position and the positioning of the surgeons had to be adapted to the abnormal anatomy of the liver and the hepatic structures. The operation was successful without any intraoperative or postoperative complications. Conclusion: As we noticed in international literature, SIT is not a contraindication for laparoscopic cholecystectomy. We believe that well experienced laparoscopic surgeons can successfully perform laparoscopic cholecystectomy on SIT patients having always in mind the reversed anatomic relationships and possible further anatomic abnormalities.

INTRODUCTION

Situs inversus totalis (SIT) is a very uncommon entity and its incidence is thought to be in the range of 1:5000-1:10000 of hospital admissions¹ or 1:10000-1:20000 living births². It was first reported by Fabricius in 1600³ and may be combined with several cardiovascular, respiratory and alimentary anatomic abnormalities^{1,4,5}. The first laparoscopic cholecystectomy was performed by Erich Muhe (Germany) in 1985 (Reynolds W Jr: The first laparoscopic cholecystectomy. JSLS 2001;5(1):89-94), but the first laparoscopic cholecystectomy in patients with SIT announced by Campos et al in 1991, followed in 1992 by Lipschutz et al, Takei et al, Drover et al, Huang et al, Goh et al. Till now (31. 12. 2009). In English-language literature we found 43 laparoscopic cholecystectomies performed on patients with SIT (Table 1).

CASE REPORT

This case is a 66-year-old woman with recurrent episodes of cholecystitis due to gallstones (referring epigastric and left quadrant pain) and an already diagnosed well-known SIT. This is the only case among 5569 laparoscopic cholecystectomies operated at our Surgical Ward in the period from January 1, 1992 to Dec. 31, 2009. The diagnosis of gallstones was settled by upper abdomen ultrasound that

confirmed also the diagnosis of the already known SIT (Fig 1). Chest plain film confirmed the position of the heart on the right side (Fig 2). All theatre equipment was in a mirrored position and this was the positioning of surgeons, too. The surgeon was positioned on the right side of the patient and manipulated the camera (10mm umbilical trocar) and the dissectors and scissors (10mm subxiphoidal trocar), while the assistant was standing on the left side of the patient working through a 5mm midclavicular left subcostal trocar and a 10mm left subcostal trocar in the anterior axillary line. All procedures were done in mirror-image technique using a zero-degree laparoscope. The operation was successful without any intraoperative or postoperative complications and lasted much longer than usual because of some dense pericholecystical adhesions and our meticulous step-by-step technique. The patient was discharged on the second postoperative day because we always put in a subhepatic drain till the first postoperative day. Pathologic examination revealed a chronic cholecystitis.

Figure 1

Fig. 1: Ultrasonography: Liver and gallbladder on the left side

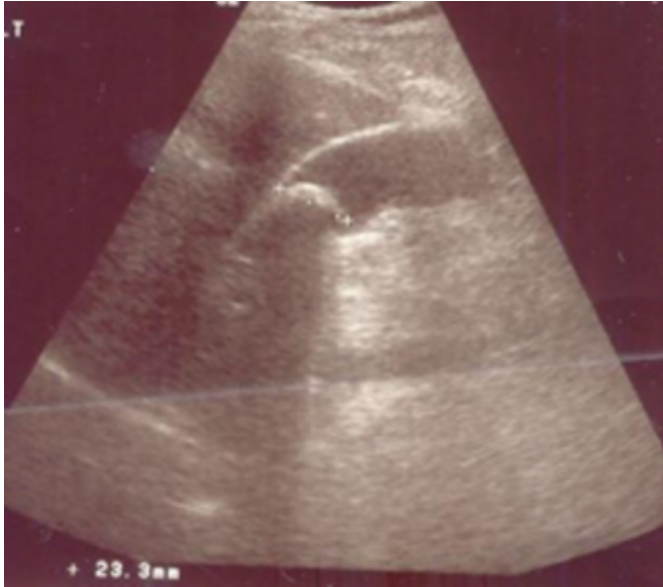

Figure 2

Fig. 2: Chest plain film: Heart on the right side

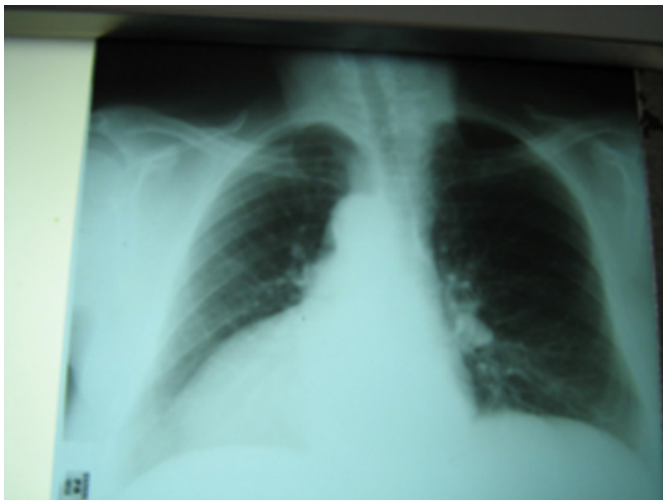


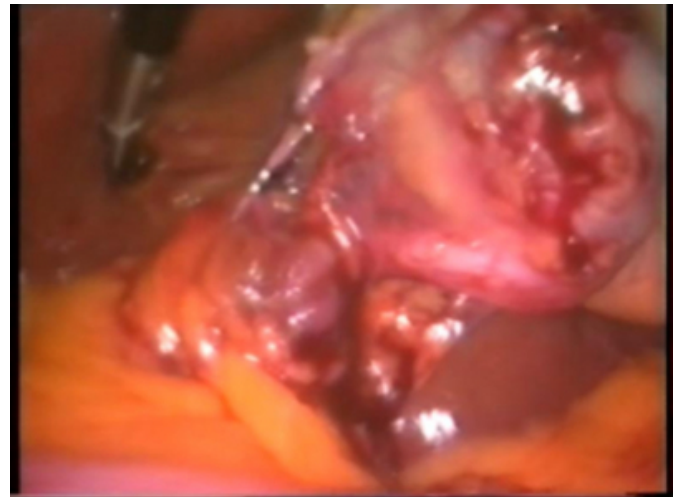
Figure 3

Fig. 3: Operation field: Liver and gallbladder on the left side



Figure 4

Fig. 4: Intraoperative image: Traction on the gallbladder, clips on the cystic duct



DISCUSSION

Situs inversus totalis is a rare condition first announced in 1600 by Fabricius with its incidence thought to be 1:5000-1:10000 of hospital admissions, and is considered to have a genetic predisposition that is autosomal recessive^{3,6}.

In the majority of cases, the SIT carriers are not associated with other abnormalities and have a normal life but in a small part of patients things are different. SIT may be combined with cardiovascular anomalies (i.e., tetralogy of Fallot, interatrial septal defects, transposition of the great arteries), malformations of the respiratory system (congenital absence of one lung, bronchiectasis), and anomalies of the digestive system (atresia or stenosis of the duodenum, absence of appendix, Meckel's diverticulum,

megacolon, atresia of the anus). When these abnormalities present in groups, they several syndromes such as Kartagener (SIT, sinusitis, bronchiectasis), Yosikawa (SIT, bilateral renal dysplasia, pancreatic fibrosis, meconium ileus), Ivemark (SIT, cardiac anomalies and asplenia)^{1,4,5}.

SIT patients present cholelithiasis, but there is no evidence for increased incidence for them.⁷

Our patient presented with symptomatic cholelithiasis revealed by ultrasonogram. She complained of recurrent episodes of epigastric and left upper quadrant pain, but some patients may have only epigastric pain (30%), whereas in 10% the pain was localized to the right upper quadrant⁸.

In our patient, SIT was diagnosed many years before and she had been investigated for possible malformations in the past. In order to minimize the possibilities of bile system malformations, ERCP, MRI, and maybe an angiography to exclude arterial variations are recommended.⁹

Since 1991, at least 43 patients from 39 authors have been appeared in English-language literature (table 1) about laparoscopic cholecystectomy performed successfully on patients with SIT not only for plain cholelithiasis but for empyema¹⁰, for cholangitis¹¹, for choledocholithiasis¹², for acute cholecystitis¹³⁻¹⁵ and even for laparoscopic exploration of the common bile duct^{16,17}.

Laparoscopic cholecystectomy in patients with situs inversus totalis is compatible according to international and our experience. Cornerstones of excellent outcome are the meticulous preoperative investigation, the mirror-image position of equipment and the continuous vigilance of the surgeon with step-by-step operation. The surgeon must always have in mind the possible anatomic abnormalities, must not be in a hurry and must be working with meticulous dissection and step-by-step recognition of anatomic structures, always upon the gallbladder.

Figure 5

Announced laparoscopic cholecystectomy in patients with SIT		Patients
Authors	Journal	
1. Campos L et al	J Laparoendosc Surg 1991(1): 123-125	1
2. Lipschutz JH et al	Am J Gastroenterol 1992 87:218-220	1
3. Takei HT et al	J Laparoendosc Surg 1992;2:171-176	1
4. Drover JW et al	Can J Surg 1992 35: 65-66	1
5. Huang SM et al	Endoscopy 1992 24:802	1
6. Goh P et al	Endoscopy 1992 24:799-800	1
7. Schiffrino L et al	Minerva Chir 1993 48:1019-1023	1
8. Mc Dermott JP et al	Surg Endosc 1994 8:1227	1
9. Idu M et al	Br J Surg 1996 83:1442	1
10. Demetriades H et al	1999 Dig Surg 16(6):519-521	2
11. Grosher RF et al	J R Coll Surg Edinb 1996 41:183	1
12. D Agata A et al	Minerva Chir 1997 52:271-275	1
13. Habib Z et al	Ann Saudi Med 1998 247-248	1
14. Djohan RS et al	JSLs 2000 4:251-254	1
15. Yaghan RJ et al	J Laparoendosc Adv Surg Tech A 2001 11(4):233-237	2
16. Nursal TZ et al	J Laparoendosc Adv Surg Tech A 2001 11:239	1
17. Al-Jumaily M et al	J Laparoendosc Adv Surg Tech A 2001 11:229-231	1
18. Wong J et al	Surg Endosc 2001 15:218	1
19. Polychronides A et al	Surg Endosc 2002 16(7):1110	1
20. Singh K et al	Surg Technol Int 2002 10:107-108	1
21. Oms LM et al	Surg Endosc 2003 17:1859-1861	1
22. Kang B et al	J Laparoendosc Adv Surg Tech A 2004 14(2):103-106	1
23. Docimo G et al	Hepatogastroenterology 2004 958-960	1
24. Antal A et al	Magy Seb 2004 81-83	1
25. Pitiakoudis M et al	Acta Chir Belg 2005 105(1):114-117	1
26. Mc Kay D et al	BMC Surg 2005 5:5	1
27. Kamitani S et al	World J Gastroenterol 2005 11(33):5232-5234	1
28. Puglisi F et al	Chir Ital 2006 58(2):179-183	1
29. Bedioui H et al	Ann Chir 2006 131(6-7):398-400	1
30. Machado NO et al	JSLs 2006 10(3): 386-391	1
31. Aydin U et al	World J Gastroenterol 2006 21:12(47):7717-7719	1
32. Kirstein B et al	Surg Lap Endosc Perc Techn 2006 169-171	1
33. Kumar S et al	Ann R C S Engl 2007 89(2):W 16-18	1
34. Pavlides Th et al	Diagn Ther Endosc 2008:465272	1
35. Hamdi J et al	Saudi J Gastroenterology 2008:14(1):31-32	1
36. Garcia-Nunez L et al	Rev Gastroenterol Mex 2008 73(3):149-152	2
37. Pereira-Graterol F et al	Cir Cir 2009:77(2):145-148	1
38. Romano GG et al	G Cir 2009:30(8-9):369-373	1
39. Taskin M et al	Obes Surg 2009 19(12):1724-1726 e-pub	1
Total		42

References

- Mayo CW, Rice TG: SIT: A statistical review of data on 76 cases with special reference to disease at the biliary tract. *AMA Arch Surg*; 1949; 58: 724-730.
- Varano NR, Merkin RJ: Situs inversus: Review of the literature: Report of four cases and analysis of the clinical implications. *J Int Coll Surg* 1991; 33: 131-135.
- Yaghan RJ, Gharaibeh KI, Hammori S: Feasibility of laparoscopic cholecystectomy in situs inversus. *J Laparoendosc Adv Surg Tech A*; 2001:11:233-7.
- Fonkalsrud FW, Tompkins R, Clathworthy HW: Abdominal manifestations of situs inversus in infants and children. *Arch Surg*; 1966; 92: 791-795.
- Johnson JR: Situs inversus with associated abnormalities. Review of the literature and report of three cases. *Arch Surg*; 1949; 58: 149-154.
- Brueckner M, D'Eustachio P, Horwich AL: Linkage mapping of a mouse gene, iv, that. *Proc Natl Acad Sci USA*; 1989; 86: 5035-5038.
- Southam JA: Left-sided gallbladder: Calculous cholecystitis with situs inversus. *Ann Surg*; 1975; 182: 135-137.
- Rao PG, Katariya RN, Sood S, Rao PLNG: SIT with calculous cholecystitis and mucinous cystadenomas of ovaries. *J Postgrad Med*; 1977; 23: 89-90.
- Kamitani S, Tsutamoto Y, Hanasawa K, Tani T: Laparoscopic cholecystectomy in SIT with "inferior" cystic artery: A case report. *World J Gastroenterol*; 2005; 11(33): 5232-5234.

10. Goh P, Tekant Y, Shang NS, Ngoi SS: Laparoscopic cholecystectomy in a patient with empyema of the gallbladder and situs inversus. *Endoscopy*; 1992; 24:799-800.
11. Mc Dermott JP, Caushas RF: ERCP and laparoscopic cholecystectomy for cholangitis in a 66-year-old male with situs inversus. *Surg Endosc* 1994; 8: 1227-9.
12. Lipschutz JH, Canal DF, Hawes RH, Ruffolo TA, Besold MA, Lehman GA: Laparoscopic cholecystectomy and ERCP with sphincterotomy in an elderly patient with situs inversus. *J Gastroenterol*; 1992; 87: 218-220.
13. Demetriades H, Botsios D, Dervenis C, Evangelou J, Agelopoulos S, Dadoukis J: Laparoscopic cholecystectomy in two patients with symptomatic cholelithiasis and situs inversus totalis. *Digestive Surgery* 1999; 16(6): 519-521.
14. Mc Kay D, Blake G: Laparoscopic cholecystectomy in situs inversus totalis: a case report. *BMC Surg*; 2005; 5: 5.
15. Bedioui H, Chebbi F, Ayadi S, Makni A, Fteriche F, Ksantini R, Jouini M, Kacem M, Ben Safta Z: Laparoscopic cholecystectomy in a patient with situs inversus. *Ann Chir*; 2006; 131(6-7):398-400.
16. Wong J, Tang CN, Chau CH, Luk YW, Li MK: Laparoscopic cholecystectomy and exploration of common bile duct in a patient with situs inversus. *Surg Endosc*; 2001; 15: 218.
17. Kang B, Han HS: Laparoscopic exploration of the common bile duct in a patient with situs inversus totalis. *J Laparoendosc Adv Surg Tech A*; 2004; 14(2): 103-106.

Author Information

Velimezis G

Surgical Ward, Western Attica General Hospital

Antoniades J

Surgical Ward, Western Attica General Hospital

Fraggedakis G

Anesthesiology Ward, Western Attica General Hospital

Sisamakis G

Radiology Ward, Western Attica General Hospital

Perrakis E

Surgical Ward, Western Attica General Hospital