

Actinomycosis of the Tongue

M Enoz

Citation

M Enoz. *Actinomycosis of the Tongue*. The Internet Journal of Infectious Diseases. 2006 Volume 6 Number 1.

Abstract

Actinomycetes are prominent among the normal flora of the oral cavity but less prominent in the lower gastrointestinal tract and female genital tract. As these microorganisms are not virulent, they require a break in the integrity of the mucous membranes and the presence of devitalized tissue to invade deeper body structures and cause human illness.

Actinomycotic infections of the cervicofacial region are not uncommon. However, actinomycosis of the tongue is rare. A mass that may mimic both benign and malignant neoplasms can be seen at clinical presentation and may mislead the diagnosis. I report a case of actinomycosis that mimicked a neoplasm of the tongue, diagnosed as Actinomycosis. The patient recovered completely after surgical incision, drainage of the abscess and six weeks of tetracycline.

INTRODUCTION

Actinomycosis is a suppurative and chronic bacterial infection caused by *Actinomyces israelii*. The clinical manifestations are in three areas: cervical (50%), thoracic (17%) and abdominal (23%) (1,2,3). The most common is the Cervico-facial, in the shape of a fluctuating mass, with little pain and of progressive growth adjacent to the mandible (1,2,3,4). It often coincides with dental manipulation or maxillofacial trauma. The skin usually appears to be involved and purplish and it is not usually accompanied by palpable adenopathies. Allowed to develop, the mass suffers a central necrosis and becomes abscessed: a fistula appears that exudes a purulent material with yellowish, granular characteristics; this material is denominated granules of sulfur (colonies of actinomyces) (1,2,3,4).

The term actinomycosis is misleading. Because of the derivative term mycosis (from the Greek mykes), some believe that actinomycosis is a fungal infection, although it is not a fungal infection. Aktino referred to the radiating organism in the sulfur granule as ray fungus. Human actinomycosis was first described in the medical literature in 1857, although a similar disease in cattle had been described in 1826 (5). In 1877, Bollinger found *Actinomyces bovis* in granules from cattle with a condition called lumpy jaw. In 1878, Israel discovered granules in human autopsy material and described actinomycosis in humans in 1885 (5).

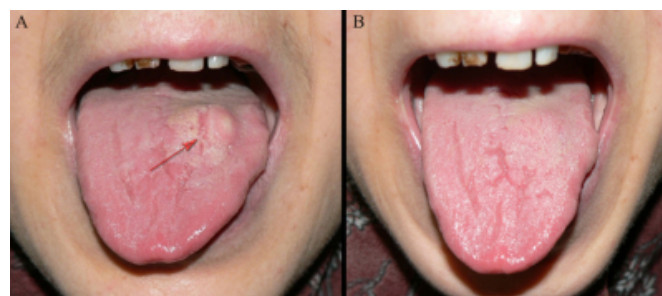
CASE REPORT

A 39-year old female patient referred to our clinic for well localized nodule in the anterior portion of the tongue for one

month. To the patient history, this nodule transformed slowly to the abscess formation. The head and neck examination was normal. The patient has no pertinent medical history other than penicillin allergy and poor oral hygiene. The mass that is fluctuant and smooth surface was showed on the middle of tongue (Figure I-A red arrow). Diagnose is made at the admittance of patient as tongue abscess and that is drained. Actinomycosis is diagnosed with histopathologic examination of the abscess material. Antibiotherapy with tetracycline is started (200 mg per day) and symptoms have resolved at the second week (Figure I-B), treatment is continued for up to 6 weeks. We believe that microorganisms are inoculated to tongue tissue with teeth of patient. Therefore she is forwarded to primary oral care center for treatment of poor oral hygiene. We are following up the patient for 6 months without any problem.

Figure 1

Figure 1: A photograph of patient who has poor oral hygiene and tongue Actinomycosis. The nodule and abscess formation is showing on anterior part of the tongue (red arrow).- The mass is seen as resolved after the surgical drainage (at the second week of tetracycline therapy).



DISCUSSION

Actinomycosis can rightly be called the “masquerader” of the head and neck. Because its symptoms are vague and nonspecific, its diagnosis can be delayed until a vital organ becomes eroded or obstructed (₆). It is a commensal saprophyte often found in the oral mucus, teeth cavities and the tonsillar crypts, especially in cases of bad hygiene, and also in the respiratory and digestive tract. In order to become pathogenic, they need a microenvironment that is favorable to them in competition with other bacteria (₇), and possibly an area that has been previously ulcerated (₈). In fact, there is often a previous history of trauma to the tongue (₉). In the present case, there is not any history of trauma to the tongue but the patient was having poor oral hygiene (Figure I).

Surgery plays an important role for diagnosis and treatment of Actinomycosis. Antibiotherapy must be followed the surgery because of recurrence following surgery alone is very common and 2-4 weeks high dose intravenous antibiotics are fundamental part of treatment, followed by 3-6 months of oral antibiotics (_{10,11,12}). Penicillin is the first choice; tetracycline and erythromycin are employed in patients allergic to penicillin (_{10,11,12}). In the acute phase of treatment, penicillin can be replaced by cephalosporins which are also effective if a co-infection with other bacteria not responding to penicillin causes the persistence of symptoms due to Actinomyces (_{13, 14}).

The present case that has penicillin allergy is completely responded to the tetracycline after the surgical drainage. This case emphasizes the Actinomycosis must be kept in mind in

patient with poor oral hygiene and tongue nodule.

References

1. Lahoz Zamorro MT, Laguia Perez M, Muniesa Soriano JA, Martinez Sanz G. [Base tongue actinomycosis] *Acta Otorrinolaringol Esp*. 2005 May;56(5):222-5.
2. Belmont MJ, Behar PM, Wax MK. Atypical presentations of actinomycosis. *Head Neck*. 1999 May;21(3):264-8.
3. Atespare A, Keskin G, Ercin C, Keskin S, Camcioglu A. Actinomycosis of the tongue: a diagnostic dilemma. *J Laryngol Otol*. 2006 Aug;120(8):681-3.
4. van der Wal KG. [Actinomycosis of the head and neck region] *Ned Tijdschr Tandheelkd*. 2000 Sep;107(9):381-2.
5. Richtsmeier WJ, Johns ME. Actinomycosis of the head and neck. *CRC Crit Rev Clin Lab Sci* 1979 Nov; 11(2): 175-202.
6. Ryan KJ. Actinomyces and Nocardia. In: Ryan KJ, ed. *Sherris Medical Microbiology*. Norwalk, Conn.: Appleton and Lange, 1994:417-9.
7. Ortega M, Arias J, Zambrano L. Actinomycosis cervicofacial. *An Med Int* 1988;5:647-648.
8. Deshpande RB, Bharucha MA. Median rhomboid glossitis: secondary to colonisation of the tongue by actinomyces. *J Postgrad Med* 1991;37 (4):238-240.
9. Brignall ID, Gilhooly M. Actinomycosis of the tongue. A diagnostic dilemma. *Br J Oral Maxillofac Surg* 1989;27:249-253.
10. Weese WC, Smith IM. A study of 57 cases of actinomycosis over a 36-year period. A diagnostic 'failure' with good prognosis after treatment. *Arch Intern Med*. 1975 Dec;135(12):1562-8.
11. Kwartler JA, Limaye A. Pathologic quiz case 1. Cervicofacial actinomycosis. *Arch Otolaryngol Head Neck Surg*. 1989 Apr;115(4):524-7.
12. Leafstedt SW, Gleeson RM. Cervicofacial actinomycosis. *Am J Surg*. 1975 Oct;130(4):496-8.
13. Hamed KA. Successful treatment of primary Actinomyces viscosus endocarditis with third-generation cephalosporins. *Clin Infect Dis*. 1998 Jan;26(1):211-2.
14. Skoutelis A, Petrochilos J, Bassaris H. Successful treatment of thoracic actinomycosis with ceftriaxone. *Clin Infect Dis*. 1994 Jul;19(1):161-2.

Author Information

Murat Enoz, M.D.

Department of Otolaryngology, Head & Neck Surgery, Maresal Cakmak Military Hospital