

# Hemangioma Of The External Auditory Canal

R Kazi

## Citation

R Kazi. *Hemangioma Of The External Auditory Canal*. The Internet Journal of Otorhinolaryngology. 2002 Volume 2 Number 1.

## Abstract

Hemangiomas, which are vascular hamartomas of a benign nature, have been well reported in the head and neck region.<sup>1</sup> We report the case of a patient with an hemangioma of the external auditory canal that appears to represent the sixth such case reported in the literature to date. In general, our findings confirm earlier descriptions of external auditory canal hemangiomas.

## CASE REPORT

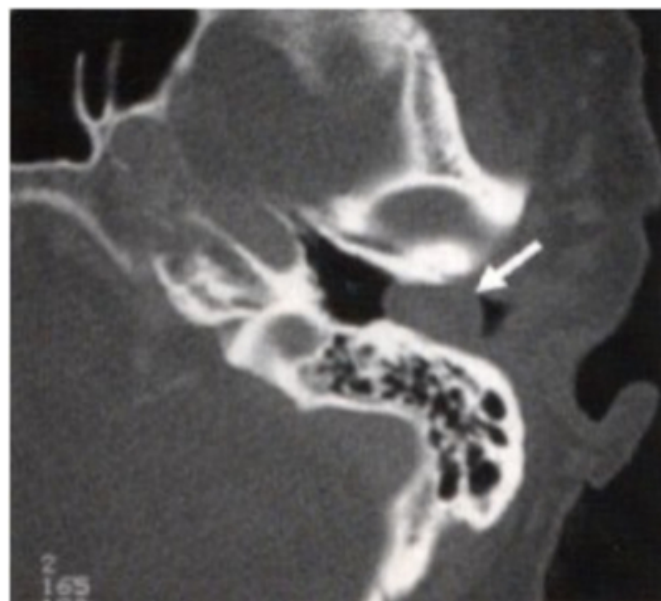
A 67-Years-Old woman was referred to the Cancer Clinic of Masina Hospital for evaluation of an external auditory canal mass. The patient described a 1 – month history of left – sided hearing loss, tinnitus, and aural fullness. She denied any vertigo and had no evidence of facial palsy. Her medical history was significant for breast cancer, status post mastectomy in 1993 without chemotherapy or radiation therapy.

On physical examination, left otoscopy revealed a purple mass that appeared to be vascular. The tympanic membrane could not be seen, because the mass occluded almost the entire external auditory canal. The mass did not blanch on pneumatic otoscopy. Right – sided otoscopy was normal. Tuning fork tests were consistent with a left conductive hearing loss. Vestibular examination was unremarkable. There was no lymphadenopathy, and the remainder of the head and neck and neurologic examination was unremarkable.

The patient had audiographic testing that revealed a moderate – to – profound mixed hearing loss on the left side.

## Figure 1

Figure 1: Computed tomography scanning with contrast agent showed a 1.5 - cm nonenhancing mass lateral to the tympanic membrane that filled the left external auditory canal (see arrow in Fig).



The tympanic membrane appeared to be intact, and the ossicles and middle ear were normal on radiography. Penetration with a 25 – gauge needle resulted in venous bleeding.

Angiography was performed to delineate the blood supply to the mass and to embolize any feeding vessels. There was no evidence of vascular blush in the region of the left external auditory canal, and there were no identifiable blood vessels for embolization. The patient was taken to the operating room on the next morning for surgical resection of the mass.

An endaural approach was used to remove the mass. The

lesion was based posterosuperiorly in the ear canal and was lateral to the annulus. The mass was excised en bloc by elevating the skin in continuity with the lesion from the bony canal without entering the middle ear space. The bone of the external auditory canal was normal in appearance. A split – thickness skin graft taken from the postauricular area was used to reconstruct the defect. The patient had an uneventful postoperative recovery. Pathologic analysis was consistent with cavernous hemangioma.

### DISCUSSION

The first 2 cases of external auditory canal hemangioma were reported by Freedom et al<sub>2</sub> in 1972. Both of these patients were men in their 50s, and they had normal hearing and normal middle ear spaces and hemangiomas of cavernous histopathology that arose from the posterior or posterosuperior canal wall. The tumors were attached to the tympanic membrane in both cases. Kemink et al<sub>3</sub> described a third case that occurred in a man aged 52 years, with a sessile mass arising from the posterior canal wall and extending onto the posterosuperior tympanic membrane. This patient also had normal hearing. Hawke and van Nostrand<sub>4</sub> described a fourth case of cavernous hemangioma in the external ear in a 55-year-old man in whom the tympanic membrane was not involved. The patient had no hearing loss. Interestingly, this mass arose from the anteroinferior canal wall. The fifth case of canal hemangioma was described in 1990 by Jackson et al<sub>5</sub> in a 60 – year – old woman with hearing loss. The tumors arose from the inferior canal wall and had a mixed capillary – cavernous histology. This tumor recurred after initial excision, a feature not noted in any of the other reported cases.

The case that we report in this article represent, to my knowledge, the sixth reported case of external auditory canal

hemangioma and the second case to occur in a woman. The hemangioma that we described was based posterosuperiorly in the canal and caused a conductive hearing loss. Although the number of total cases is few, there are similarities between the cases that may indicate characteristic tendencies of this disease entity. External auditory canal hemangiomas seem to occur in individuals in their sixth and seventh decades of life. Males and females are thus far affected in a 2:1 ratio. Most commonly, these masses arise from the posterior canal wall and tend to adhere partially to the tympanic membrane. A conductive hearing loss may be present. Cavernous histology is the most common histopathologic type, and these hemangiomas do not usually have invasive feature. The middle ear is generally unaffected by external auditory hemangiomas, although hemangiomas of the internal auditory canal or middle ear may protrude into the external auditory canal.<sub>1</sub> Simple resection of the hemangioma is curative, and preoperative embolization is not typically required.

In summary, we report a case of external auditory canal cavernous hemangioma that appears to be the sixth such case in the literature. Although these cases are extremely rare, our findings generally confirm previous findings and allow us to make preliminary observations regarding this disease entity.

### References

1. Nager GT. Hemangiomas and vascular malformations. In: Nager GT, editor. Pathology of the ear and temporal bone. Baltimore: Williams & Wilkins; 1993.
2. Freedman SI, Barton S, Goodhill V. Cavernous angiomas of the tympanic membrane. Arch Otolaryngol 1972;96:158-60.
3. Kemink JL, Graham MD. Hemangioma of the external auditory canal. Am J Otol 1983;5:125-6.
4. Hawke M, van Nostrand P. Cavernous hemangioma of the external ear canal. J Otolaryngol 1987;16:40-2.
5. Jackson CG, Levine SC, McKennan KX. Recurrent hemangioma of the external auditory canal. Am J Otol 1990;11:117-8.

**Author Information**

**Rehan A. Kazi, M.S.(ENT), DNB, DLORCS (Eng), Fc.Oncology, FAAOHNS, FIAOMS.**

Fell. in H&N Onc.(JMS, Poland),Fell. in H&N Onc.(RMH, London),UICC Fellow, Dept. of ENT & Head, Neck Surgery,  
Masina Hospital