

# Ambulatory Anesthesia in Deficiency Glucose 6-phosphate dehydrogenase

E Del Massa, S Federmann

## Citation

E Del Massa, S Federmann. *Ambulatory Anesthesia in Deficiency Glucose 6-phosphate dehydrogenase*. The Internet Journal of Anesthesiology. 2006 Volume 11 Number 2.

## Abstract

This report aimed at presenting a case of a Glucose 6-phosphate dehydrogenase (G6PD) deficient patient, undergoing ambulatory anesthesia with inhalatory anesthesia associated to caudal block.

Case Report: Male patient, 2 years old, with G6PD deficiency diagnosed to the birth after jaundice for the exam neonatal, without hemolytic crisis in his development, submitted to inguinal hernia repair, hydrocelectomy and posthectomy under inhalatory anesthesia with sevoflurane in the induction and isoflurane to maintenance anesthesia with LM associated to caudal block with bupivacaine 0,125%. At the end of surgery the patient awakened with agitation and fentanyl did optimize recovery. After this initial recuperation another alterations was not found.

Conclusions: According to the evolution of this case, the profile of complications such as stress, hemolytic problems, malignant hyperthermia, or methemoglobinemia, can be managed and become a success in this G6PD patient.

## INTRODUCTION

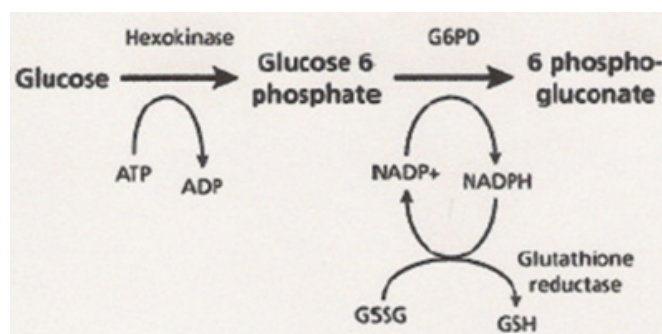
Glucose 6-phosphate dehydrogenase (G6PD) deficiency is a relatively common enzymopathy, but there are few publications relating such condition to anesthesia<sup>1</sup>. More than 400 mutations have been identified, most being missense mutations<sup>2</sup>.

G6PD deficiency is a hereditary disease caused by the heritage of abnormal alleles of the gene responsible for the G6PD molecule synthesis. These genes are located in the chromosome X so, clinical manifestations are more frequent among males or homozygote women for the abnormal chromosome<sup>3</sup>.

G6PD catalyzes nicotinamide adenine dinucleotide phosphate (NADP) to its reduced form, NADPH, in the pentose phosphate pathway (Figure 1<sub>9</sub>). NADPH protects cells from oxidative damage. Then the erythrocytes do not generate NADPH in any other way, they are more susceptible than other cells to destruction from oxidative stress<sup>2</sup>. A total deficiency of G6PD is incompatible with life<sup>2</sup>.

## Figure 1

Figure 1: G6PD catalyzes NADP<sup>+</sup> to its reduced form, NADPH, in the pentose phosphate pathway. (ATP = adenosine triphosphate; ADP = adenosine diphosphate; G6PD = glucose-6-phosphate dehydrogenase; NADP<sup>+</sup> = nicotinamide adenine dinucleotide phosphate [oxidized form]; NADPH = reduced NADP; GSSG = oxidized glutathione; GSH = reduced glutathione.) Adapted with permission from Glucose 6 phosphate dehydrogenase deficiency. Accessed online January 14, 2006, at: .



G6PD deficiency is responsible for the clinical manifestation of acute and intense hemolytic syndrome, is self-limited<sup>2</sup>, and is in general triggered by oxidative drugs (Chart I) or by the ingestion of certain foodstuffs which allow for the formation of the sulfhydryl group, such as beans (favism), peas, dyes, etc. Stress situations or infections may also

trigger hemolytic crises in those patients, although the action mechanism is not yet well known<sup>3</sup>.

## Figure 2

Chart 1: Drugs Able to Induce Hemolysis in G6PD-Deficient Patients 2,3

Analgesics	Other drugs
Acetylsalicylic Acid (in high doses)	
Nitrofurantoin	
Acetaminophen	
Methylene blue	
Acetophenetidin	
Vitamin K	
Acetanilid	
Nalidixic acid	
Antimalaria	
Probenecid	
Primaquine	
Ascorbic acid (in high doses)	
Chloroquine	
Nitrates	
Pentaquine	
Quinidine	
Sulfonamides	
Naphthalene	
Sulfones	
Chloramphenicol	
Quinine	
Quinidine	

Enzymes are responsible for the excretion of the sulfhydryl group formed in oxyhemoglobin when exposed to the above-mentioned drugs and foodstuffs, leading to its precipitation within the erythrocyte and causing intravascular hemolysis.

Patient who are G6PD-deficient may show methemoglobinemia due to an abnormal form of hemoglobin in which the iron molecule is in the ferric (3+) state rather than the normal ferrous (2+) state. These individuals can tolerate a methemoglobinemia between 10-50% with no health risk<sup>10</sup>.

This is a report on a pediatric G6PD-deficient patient

submitted to inguinal hernia repair, hydrocelectomy and posthectomy under inhalatory anesthesia associated to caudal block.

## CASE REPORT

A male patient, 2 years old, 1.01m heights, 18 kg, with G6PD deficiency was admitted for inguinal hernia repair, hydrocelectomy and posthectomy. At the newborn period, the patient had a several jaundice because the medications given for your mother and but was treated with phototherapy. A G6PD deficiency was diagnosed. Another hospitalization was not observed. The patient was seen by pediatrics and hematologists in your newborn and neonate period. Since then, after all care had been taken to prevent hemolytic crises triggering factors, the patient had a good evolution without new crises.

At preanesthetic during evaluation the patient was in good conditions, active without cardiovascular, respiratory, digestive and renal systems abnormalities. Preoperative blood test was normal: red cells 4.700/mm<sup>3</sup>; Hemoglobin 13,5 g % and hematocrit 38,9 %, time of coagulation 5 minutes and 30 seconds, time of activated thromboplastin 87,96% and INR 1,12, platelet 341.000/mm<sup>3</sup>.

The patient was anxious and not cooperative needing preanesthetic medication with midazolam 5 mg orally. After 15 minutes the patient was taken to the operate room. This child was monitored without difficult or resistance with pulse oximeter (SpO<sub>2</sub>), cardioscope (ECG at DII, AVL), cutaneous temperature (T), no invasive blood pressure (NIBP) and capnography (PETCO<sub>2</sub>). Induction of anesthesia in double T of Baraka system Mapleson D. Anesthesia was done with sevoflurane and mixture 50% of O<sub>2</sub>/N<sub>2</sub>O, initiated sevoflurane with 1% until 8%. After completed induction it was changed to sevoflurane by isoflurane 2,5% and venous puncture was performed with a 22 G catheter in the left upper limb, and a number 2 Laryngeal Mask was introduced without trouble. Following, with the patient in the right lateral position, caudal block was performed with a 25G needle and bupivacaine 0,125% 18 ml was administered.

Surgery was started 15 minutes later with the patient in the supine position, and lasted 45 minutes. He had showed few alterations. Changes in temperature that increased 1±C and the SpO<sub>2</sub> decreased from 98 to 92%, while maintaining the same respiratory frequency and O<sub>2</sub>/N<sub>2</sub>O concentration. The isoflurane concentration was decreased from 1,5% to 0,8%.

At surgery completion, the patient awakened with agitation and fentanyl  $1,5 \text{ mcg}^{-1} \cdot \text{kg}^{-1}$  in bolus and infusion  $1,5 \text{ mcg} \cdot \text{kg}^{-1} \cdot \text{h}^{-1}$  was given. The patient was directed to the Post Anesthetic Care Unit (PACU) without pain or other complaints and was referred to the postanesthetic recovery unit where he remained for 60 minutes without interurrences or medications. Accomplished the criteria discharged from PACU according to Aldrete-Kroulick table and was referred to the ward. The patient had a good recovery without interurrences and was discharged 24 hours after surgery, and all recommendations were given to the relatives.

### DISCUSSION

The early diagnosis of this enzymopathy is relatively difficult because blood enzymes may be normal during an acute hemolytic crisis triggered by oxidants or stress. In general, hemolysis is seen 1 to 3 days after contact with triggering factors. This consideration was sufficient to maintain the patient interned by 24 hours, in spite of the surgery to be ambulatorial.

Diagnosis is achieved through a direct or indirect evidence of G6PD activity decrease in red cells. Immediately after a hemolytic episode, young reticulocytes and red cells predominate and these young cells have enzymatic activity well higher than older ones, so, the test has to be postponed for some weeks to show a low enzymatic level confirming the diagnosis <sup>5</sup>.

Hemolysis prevention is paramount for the anesthetic management of such patients, avoiding in all surgery period of the administration of oxidative drugs, prevention of or stress situations. Acute hemolysis is self-limited, but in rare instances it can be severe enough to warrant a blood transfusion<sup>1</sup>. Others factors with prevention of methemoglobinemia, malignant hyperthermia was preventioned. In spite of to against indication of the use, the patient made use of acetaminophen in analgesia or fever, without problems.

We have not found in the literature studies relating hemolytic crises induced by inhalatory general anesthesia although some authors have already related G6PD

deficiency to Malignant Hyperthermia <sup>6</sup>. A literature review suggests that G6PD deficiency in general does not result in anesthesia-triggered side effects when oxidative drugs are avoided, always reminding that patients with infection are more susceptible to hemolytic crises during anesthesia. Folic acid and iron potentially are useful in hemolysis, although G6PD deficiency usually is asymptomatic and the associated hemolysis usually is short-lived. Antioxidants such as vitamin E and selenium have no proven benefit for the treatment of G6PD deficiency.<sup>2</sup>

Basing on concepts of ambulatory anesthesia, we took for conduct the total relief of the stress, minimizing this factor in the pre, per and postoperative period. The use of midazolam in preanesthesia, the association anesthetizes inhalatory and epidural flow still reducing both anesthetics needs and the immediate fentanyl use in the beginning of the awakening and maintenance in PACU obtained success, as the analgesia and acetaminophen need in immediate postoperative period that was of a single dose 12 hours after the end of the surgery. No antibiotic was given.

### References

1. Smith CL, Snowdon SL: Anaesthesia and Glucose-6-Phosphate Dehydrogenase Deficiency. *Anaesthesia*, 1987; 42:281-288.
2. Frank JE: Diagnosis and Management of G6PD Deficiency. *Am Fam Physician* 2005; 72:1277-82.
3. Abreu MP, Freire CCS, Miura RS: Anesthesia in Glucose-6-Phosphate Dehydrogenase-Deficient Patient. Case Report; *Rev Bras Anesthesiol* 2002; 52: 6: 707 - 711
4. Smith CL, Snowdon SL: Anaesthesia and Glucose-6-Phosphate Dehydrogenase Deficiency. *Anaesthesia*, 1987; 42:281-288.
5. Muñoz C, Domingues E, Mourelle I et al: Perioperative management of glucose 6 phosphate dehydrogenase deficiency. *Minerva Anesthesiol* 1999; 65(9); 641-5.
6. Younker D, DeVore M, Hartlage P: Malignant hyperthermia and glucose-6-phosphate dehydrogenase deficiency. *Anesthesiology*, 1984; 60:601-603.
7. Basora M, Villaonga A, Ayuso MA: Glucose-6-phosphate dehydrogenase deficiency: anesthetic implications. *Rev Esp Anesthesiol Reanim*, 1990; 37:380.
8. Jreige MM, Sobreira DP, Saraiva RA: Evaluation of the fresh Gas flow in the Rees-Baraka System. *Rev Bras Anesthesiol* 1998; 48:2: 095-102.
9. Glucose 6 phosphate dehydrogenase deficiency. Accessed January 20, 2006, at: <http://www.malariasite.com/malaria/g6pd.htm>.
10. Methemoglobinemia - <http://www.med.umich.edu/ccmu/methgb.htm> . Accessed January 20, 2006

**Author Information**

**Emilio C. Del Massa**

Anesthesiologist, São Camilo Hospital and Maternity - Unit Santana

**Sidney Federmann**

Pediatric Surgeon, São Camilo Hospital and Maternity - Unit Santana