

# An Abbreviated cementing technique for Thompson's Hemiarthroplasty.

S Naqvi, R Spencer

## Citation

S Naqvi, R Spencer. *An Abbreviated cementing technique for Thompson's Hemiarthroplasty.* The Internet Journal of Orthopedic Surgery. 2009 Volume 16 Number 2.

## Abstract

Thompsons Prosthesis is one of the most commonly used hemiarthroplasty for the neck of femur fractures. We describe an abbreviated cementing technique for Thompson Hemiarthroplasty which has the benefit of preserving the bone stock and reduction in operating time. We looked at 24 patients who underwent hemiarthroplasty using this technique with a very good outcome.

## INTRODUCTION

Surgery is the treatment of choice for displaced intra-articular fracture but debate continues on the role of internal fixation versus hemiarthroplasty, unipolar versus bipolar prostheses, and whether to cement the prosthesis or not.<sup>1</sup>

Thompson's prosthesis was originally introduced in 1950's for non-union of femoral neck fractures<sup>2</sup>. It was used uncemented in the beginning. Cement fixation has the advantage of lower revision rate, reduced incidence of thigh pain, loosening and better mobility.<sup>3,4</sup>

Many surgeons employ 'third generation' cementing technique (which includes use of an intramedullary cement restrictor, a cement gun, pulsatile lavage; pressurization of the cement; and reduction of porosity of the cement by centrifugation).<sup>5</sup> We describe an abbreviated cementing technique for Thompsons hemiarthroplasty.

## MATERIALS AND METHODS

We performed a retrospective analysis of patients who underwent Thompson's hemiarthroplasty between December 2006 and July 2008 using an abbreviated cementing technique, recording the amount of pain, dislocation rate, death and other complications. Mobility was assessed using the New Mobility Score pre and post operatively (Table2).

Alignment of the prosthesis, lateral offset and remaining neck length were measured postoperatively.

An anterolateral surgical approach was used in all cases. The medullary cavity was identified by advancing a closed

Kocher's clamp, following which a femoral rasp was inserted to half its potential depth (Picture 1). The phantom stem was then carefully fully impacted (Picture 2), followed by the selected implant to allow a trial reduction. A Hardinge restrictor was inserted followed by lavage and early introduction of cement and implant. Because of bone impaction considerable stability was noted in most cases allowing 'wet' reduction.

## RESULTS

The technique described has been used in over 200 cases since 1996. Our study analysed the outcome in 24 patients with a mean age of 85 (range 74 – 95 yrs, mode 87 years) treated between December 2006 and July 2008. No patients complained of thigh pain post operatively and early pain control was achieved with simple analgesics. Recorded blood loss was less than 250 ml in all cases. There was a mean drop in haemoglobin of 2.5gm/dl post operatively and transfusion was required in only 2 patients (8.3%). There were 4 deaths during the study period (16.7%). One patient developed a seroma and wound infection (Table 1). There were no recorded thrombo-embolic events. Only 6 patients regained their pre-operative mobility and there was mean reduction of 2.30 in the New Mobility Score. There was one dislocation (4.2%) in a patient treated for a one month old fracture who had a flexion deformity on presentation. None of the patients required revision surgery. The mean duration of hospital stay was 18 days. The alignment of the prosthesis was satisfactory (prosthesis neck-femoral shaft angle and offset) with minimal cement mantle in Gruen zones 1, 7, 8 and 14 in most cases.

**Figure 1**

Table 1- Complications

	Complication	Incidence(Percentage)
1	Dislocation	1 (4.2%)
2	Infection/Seroma	1 (4.2%)
3	Death	4 (16.7%)
4	Pneumonia	3 (12.5%)
5	Ischemia (MI/TIA)	2 (8.33%)

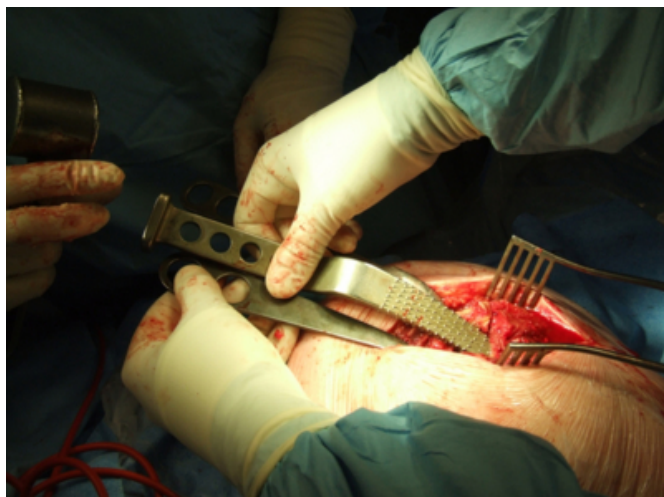
**Figure 2**

Table 2- New Mobility Score

Mobility	No Difficulty	With Aid	With Help from other person	Not at all
Able to get about the house	3	2	1	0
Able to get out of the house	3	2	1	0
Able to go shopping	3	2	1	0

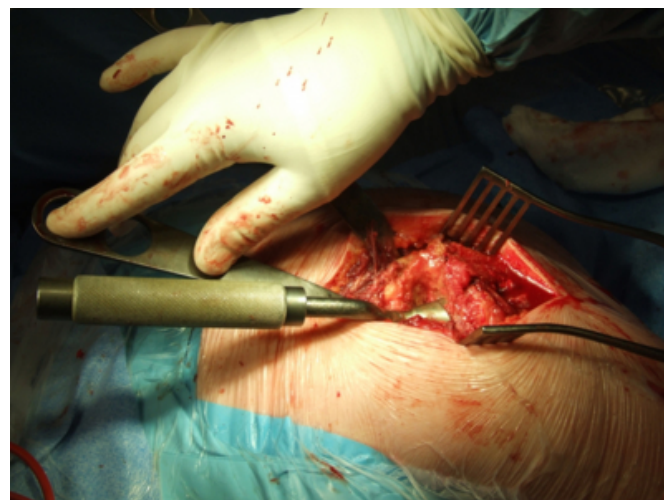
**Figure 3**

Figure 1



**Figure 4**

Figure 2



## DISCUSSION

The debate relating to cement in hemiarthroplasty surgery relate to well documented effects on the cardiopulmonary system of cement insertion, ranging from transient hypotension and hypoxemia to sudden death<sup>6</sup> and fat and marrow embolism is believed to be the underlying factor.<sup>7,8</sup> Although cemented prostheses are associated with greater blood loss and operative time, the revision rate is less with significant reduction in thigh pain, dislocation, loosening and better mobility<sup>3,4</sup>. Opponents of the use of cement claim that it is more demanding and difficult to revise<sup>1,9</sup>. Browett (1981) showed that tight fit requirement of an uncemented prosthesis makes an iatrogenic femoral shaft fracture more likely<sup>10</sup>. Emery et al. observed less dependence on walking aids in the cemented compared with uncemented hemiarthroplasty patients<sup>11</sup>. There is no difference in mortality rate between cemented and uncemented techniques.<sup>4, 9-11</sup>

We believe third generation cementing techniques may not be necessary in many cases requiring hemiarthroplasty. A reduction of operating time by about 10-15 minutes by an abbreviated cementing technique and early reduction of the hip may be of benefit in elderly and frail patients. The method described carries the additional advantage of conserving femoral bone stock should subsequent revision be required. Traditional cementing techniques frequently result in a large volume of cement in contact with thin and porotic cortex.

## References

1. Parker MJ (2000) The management of intracapsular fractures of the proximal femur. J Bone Joint Surg [Br] 82:

937–941

2. Thompson FR (1954). Two and a one-half years experience with a Vitallium intramedullary hip prosthesis. *J Bone Joint Surg [Am]*. 36A(3):489-502
3. Khan RJK, MacDowell A, Crossman P, Keene GS. (2002) Cemented or Uncemented hemiarthroplasty for displaced intracapsular fractures of the hip-a systematic review. *Injury* 33: 13-17
4. Muirhead-Allwood W, Hutton P.(1983) A comparative study of cemented and uncemented Thompson prosthesis: an abstract. *J Bone Joint Surg [Br]*. 65B:2.
5. Oishi CS, Walker RH, Colwell CW. (1994) The femoral component in total hip arthroplasty. Six to eight-year follow-up of one hundred consecutive patients after use of a third-generation cementing technique. *J Bone Joint Surg Am*. 76:1130-1136
6. Dandy DJ. (1971) Fat embolism following prosthetic replacement of the femoral head. *Injury* 3(2):85–8.
7. Byrick RJ, Bell RS, Kay JC, Waddell JP, Mullen JB.(1989) High-volume, high pressure pulsatile lavage during cemented arthroplasty. *J Bone Joint Surg*. 71A(9):1331–6.
8. Pitto RP, Blunk J, Kossler M. (2000) Transesophageal echocardiography and clinical features of fat embolism during cemented total hip arthroplasty. *Arch Orthop Trauma Surg*. 120:53–8.
9. Gingras MB, Clarke J, McCollister Evarts C.(1980) Prosthetic replacement in femoral neck fractures. *Clin Orthop Relat Res*. 152:147–57.
10. Browett JP.(1981) The uncemented Thompson prosthesis. *J Bone Joint Surg*. 63B(4):634–5.
11. Emery RJH, Broughton NS, Desai K, Bulstrode CJK, Thomas TL.(1991) Bipolar hemiarthroplasty for subcapital fracture of the femoral neck. *J Bone Joint Surg*. 73B(2):322–4.

**Author Information**

**Syed G. A. Naqvi, MBBS, MRCS**

Registrar Trauma and Orthopaedics, Weston General Hospital

**Robert Spencer, MD, FRCS**

Consultant Trauma and Orthopaedics, Weston General Hospital