

# Postmenopausal Bleeding Due to Unusual Presentation of Colorectal Cancer

S Aella, K Chandra Reddy, T Maulik

## Citation

S Aella, K Chandra Reddy, T Maulik. *Postmenopausal Bleeding Due to Unusual Presentation of Colorectal Cancer*. The Internet Journal of Gynecology and Obstetrics. 2006 Volume 7 Number 1.

## Abstract

Postmenopausal bleeding is a common problem of varied etiology in the age group 50 –75. It is more likely to be caused by pathologic disease than is bleeding in younger women and must always be investigated. The most common cause is exogenous hormones<sup>1</sup>. Other causes are endometrial cancer, polyps and hyperplasia, cervical cancer and lesions, uterine tumours, ovarian cancer and estrogen secreting tumours in other parts of the body. Colonic cancer presenting as postmenopausal bleeding is unusual and very rare. The clinicians dealing with postmenopausal bleeding need to be aware of rare causes including colorectal cancer, especially in hysterectomised patients.

## INTRODUCTION

A 60-year-old lady presented to the clinic with history of postmenopausal bleeding since three months. There were no gastrointestinal symptoms, loss of weight or loss of appetite. She was a known hypertensive and had total abdominal hysterectomy and left salpingo-oophorectomy 15 years ago for menorrhagia. Histology was benign. Her previous cervical smears are normal. Patient was not on HRT. Her vitals are stable. Pelvic examination was inconclusive due to bleeding and pain. She was posted for 'Examination Under Anaesthesia, possible Laparoscopy'.

Examination in theatre revealed increased thickness on the right side of the vaginal vault. Punch biopsy was taken from the thickened area. Rest of the vault appeared normal. Laparoscopy showed a small mass in the right adnexa of uncertain origin. Right ovary could not be visualised as this was buried in the adhesions from the previous surgery. Cystoscopy was normal. Histology showed moderately well differentiated adenocarcinoma, appeared to be of bowel origin.

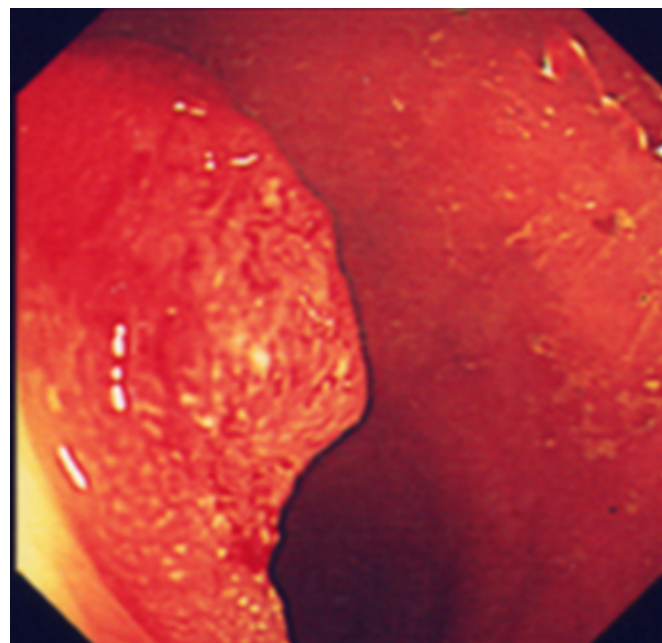
Carcinoembryonic antigen (CEA) was 5.3 (normal <3 ng/ml). All other tumour markers were within normal limits {CA125 – 6.9(2.6-24 U/ml), CA19.9 – 3.9(0-33U/ml), AFP – 5.7(0-5 IU/ml)}.

CT scan was arranged and patient was referred to the surgical team. CT scan of chest, abdomen and pelvis showed a mass of about 5 cm in the right fornix of the vaginal vault.

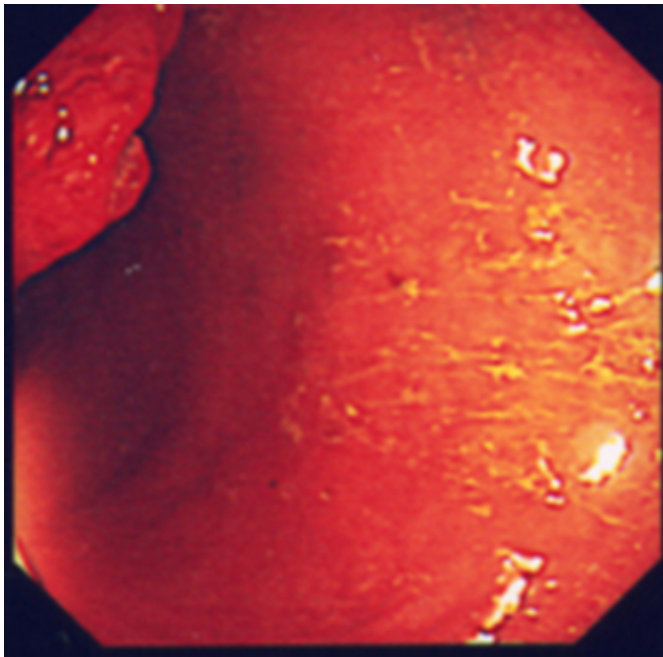
It was nodular and irregular, extending laterally as far as lateral wall of pelvis. There was no evidence of trans-coelomic spread or invasion to bladder or bowel. No evidence of any lymph nodal, lung or bone metastasis. Sigmoidoscopy was performed which showed a 2cm polypoidal tumour. Multiple biopsies were taken.

## Figure 1

Pictures: Colorectal tumour



**Figure 2**



Histology showed foci of severe dysplasia and invasion in one area. Barium enema demonstrated mucosal abnormality in the right lateral wall of rectum. The remainder of colon did not reveal any abnormality. Laparotomy showed the mass at recto sigmoid, infiltrating right side of vaginal vault, ovary and ureter. Bladder base was adherent to the vaginal vault. The entire mass was not resectable surgically. Rectum was freed and sigmoid loop colostomy was performed. She was referred to oncology centre for chemotherapy and radiotherapy.

## DISCUSSION

Postmenopausal bleeding is a common problem of varied etiology in the age group 50–75. It is more likely to be caused by pathologic disease than is bleeding in younger women and must always be investigated. The most common cause is exogenous hormones<sup>1</sup>. Other causes are endometrial cancer, polyps and hyperplasia, cervical cancer and lesions, uterine tumours.

Postmenopausal bleeding in post-hysterectomy patients is rare. Causes include atrophic vaginitis, cervical stump cancer, infiltrating ovarian tumours, estrogen secreting tumours in other parts of the body. Endometriosis of the vault sometimes can cause postmenopausal Bleeding. Diverticulitis of the bowel may give rise to vaginal discharge due to fistula but bleeding is rare. Bladder pathology may cause vaginal bleeding.

Investigations should include endometrial biopsy as

outpatient procedure, transvaginal ultrasound and hysteroscopy. Investigations of vaginal bleeding in post-hysterectomy patients include detailed clinical examination including speculum. If difficult, gold standard will be Examination Under Anaesthesia, Cystoscopy and or Laparoscopy if needed. If any lesion is suspected, full biochemical investigations along with tumour markers, radiological (CT/MRI and chest X-ray) and bimanual examination under anaesthesia must be carried out<sup>2,3</sup>.

The case we have reported had hysterectomy and left salpingo-oophorectomy at the age of 45 years. She came through rapid access clinic with history of vaginal bleeding. She did not give any history of bowel symptoms. The signs and symptoms of colorectal cancer are bleeding per rectum, change of bowel habits, abdominal pain, anaemia, intestinal obstruction and perforation<sup>4,5,6</sup>.

Looking through the literature, the most common metastatic sites of colorectal cancer are liver and regional lymph nodes, common sites are peritoneum, lung and ovaries and rare sites are central nervous system, bone, testis, uterus and oral cavity<sup>4,6</sup>. Case reports of very rare metastasis to adrenal gland and hilar lymph node are also published. Epidermal anal carcinoma can spread to vagina by local extension<sup>7</sup>.

Another case report of colon cancer with postmenopausal bleeding secondary to ovarian metastasis<sup>8</sup> was reported as well. So far in published cases postmenopausal bleeding due to metastases were identified in patients already diagnosed having colorectal cancer. Our case is unique, patient never reported any bowel symptoms. The patient presented with postmenopausal bleeding first and the bowel cancer is diagnosed later.

## CONCLUSION

While dealing with patients presenting with post hysterectomy vaginal bleeding, the differential diagnosis of metastasis from bowel cancer should be borne in mind as in this case, although it is very rare.

## CORRESPONDENCE TO

Mr. Koli Chandra Reddy, MD, MRCOG. Specialist Registrar Prince Charles Hospital Merthyr Tydfil. U.K CF47 9DT Email: drcreddy13@yahoo.com Tel: 01685 721721 Bleep: 515 Mobile: 07883032434

## References

1. Silberstein T(2003), Complications of Menstruation: Abnormal Uterine Bleeding : Current Obstetric and Gynaecologic Diagnosis and Treatment IX edition, pp

629-630.

2. Quinn M, Jones B, Dina R, Soutter P.(2003) Malignant Disease of the Uterus.

In Gynaecology, III edition, pp 638-639, Edinburgh, Churchill Livingstone.

3. Soutter W P (1999) Malignant diseases of the Uterus. In Dewhurst's Textbook

of Obstetrics and Gynaecology for Postgraduates. VI edition. pp 564-566,

Oxford, Blackwell Science

4. Rosai J (1996). Gastrointestinal Tract: Large Bowel. In: Ackerman's Surgical

Pathology VIII edition, pp 768, 775. St. Louis, Mosby

5. Motwani B T, Shafir M, Merrick M, Tepper J, Bruckner H W. (1997)

Neoplasms of Alimentary Canal In: Cancer Medicine IV

edition. pp2040.

Baltimore, Williams & Wilkins

6. Williams N S, Northover J M A, Arnoff S J, Jass J R (1995) Oxford Textbook

of Oncology I edition, pp 1139-1140, 1142-1143. Oxford, Oxford University

Press.

7. Shank B, Cunningham J D, Kelsen D P (1997) Cancer, Principles and Practice

of Oncology V Edition, pp 1238-1239, Philadelphia, Lippincott-Raven.

8. Richard L.M., Coleman (1981). Colon cancer with Postmenopausal bleeding,

American Journal of Obstetrics and Gynaecology.140 (8): 891-1,1981 Aug 15.

**Author Information**

**Sanjeetha Aella, MBBS**

Senior House Officer, Prince Charles Hospital

**Koli Chandra Reddy, MD, MRCOG**

Specialist Registrar, Prince Charles Hospital

**T. G. Maulik, FRCOG**

Consultant, Prince Charles Hospital