

Keratinized Gingiva Width Alteration during Orthodontic Alignment and Leveling Phase; a Preliminary Investigation

A Dannan, M Darwish, M Sawan

Citation

A Dannan, M Darwish, M Sawan. *Keratinized Gingiva Width Alteration during Orthodontic Alignment and Leveling Phase; a Preliminary Investigation*. The Internet Journal of Dental Science. 2008 Volume 7 Number 2.

Abstract

Aim: To evaluate changes of keratinized gingiva width of frontal teeth during the phase of orthodontic alignment and leveling. **Materials and Methods:** 10 patients having front teeth crowding (120 teeth divided into 20 groups) were recruited in the study. Orthodontic alignment and leveling movements were initiated. Periodontal assessment was achieved including plaque index, probing depth, gingival index and papillary bleeding index. The width of keratinized gingiva was measured at every tooth in every group and expressed as the average of keratinized gingiva width (aKGW). All clinical parameters and aKGW were assessed at baseline, at 1 month, at 3 months and at 6 months. **Results:** No statistically significant changes were observed in the scores of periodontal indices recorded during the whole period of study ($P > 0.05$). Concerning aKGW records, no statistically significant changes were found between the measurements during the whole period of observation ($P > 0.05$). **Conclusion:** Orthodontic tooth alignment and leveling do not lead to significant changes in the width of keratinized gingiva when adequate plaque control is maintained.

INTRODUCTION

During orthodontic tooth movement, it is very important for the periodontal tissues to be in a balanced situation along with the tooth at the cervical areas (1).

The attached gingiva is the part of gingival tissues that is continuous with the marginal gingiva. It is firm, resilient, and tightly bound to the underlying periosteum of alveolar bone. The width of the attached gingiva is defined as the distance between the mucogingival junction and the projection on the external surface of the bottom of the gingival sulcus or the periodontal pocket. It should not be confused with the width of the keratinized gingiva (or keratinized gingiva width KGW) because the latter also includes the marginal gingiva.

It has been assumed that a minimal width of attached gingiva is required for optimal gingival health to be maintained. However, several studies have challenged the view that a wide keratinized gingiva is more protective against the accumulation of plaque than a thin or a nonexistent zone. Moreover, it seems to be that a sufficient amount of keratinized gingiva is more valuable for the gingival health and to allow the orthodontic appliances, whether removable or fixed, to achieve the corrective treatment without any

harmful effect on the periodontal hard and/or soft tissues (2).

Orthodontic alignment and leveling are - usually - the first two stages when an orthodontic treatment with fixed appliances is to be initiated. The goal of alignment in orthodontic treatment is to correct crowding by lining up all of the teeth into a smooth curve and is accomplished by uncontrolled tipping of teeth into a smooth arch. Orthodontic leveling is a method used to align the upper teeth properly with the lower teeth and is accomplished by intrusion or extrusion of the teeth so that the upper and lower teeth come together.

A past study (3) showed no differences of KGW in a comparison between patients who underwent orthodontic treatments and a control group.

A classical study of Dorfman (1978) was conducted to determine changes in the width of keratinized gingiva relative to lower incisor tooth movement. It involved a cephalometric analysis of 1,150 fully treated orthodontic cases evaluated by Kodachrome slides, plaster casts, and cephalometric films, and it was apparent that in a small percentage of cases visible mucogingival changes occurred and could be statistically correlated with the magnitude and direction of tooth movement (4). In this group of patients 1.3

percent (sixteen) showed a decrease in the width of keratinized gingiva with either minimal movement or some labial movement of the mandibular incisors; 0.69 percent (eight) had an increase in keratinized gingival width concomitant with significant lingual positioning of the lower incisors.

However, to our knowledge, there has been -to date- no study that demonstrates how the width of keratinized gingiva changes during the phase of orthodontic alignment and leveling. Therefore, the aim of this study was to examine the effect of the orthodontic tooth alignment and leveling phase on the keratinized gingiva width.

MATERIALS AND METHODS

Ten adult orthodontic patients from the department of orthodontics, faculty of Dental Medicine - Damascus University (9 females and 1 male, mean age of 24 ± 6 years) who had different types of Angle classification and teeth position abnormalities were selected to participate in this study. To be eligible for the study, those patients had to meet the following criteria: (1) good general health; (2) lack of antibiotic therapy during the previous 6 months; (3) absence of anti-inflammatory drug administration in the month preceding the study; (4) periodontally healthy with generalized probing depths ≤ 3 mm and no radiographic evidence of periodontal bone loss; and (5) requirement of an orthodontic treatment plan starting with alignment and leveling as a first stage. One week before the start of orthodontic treatment, all patients received a session of supra – and subgingival ultrasonic scaling and were given written and oral hygiene instructions to be maintained during the whole period of the study.

Full orthodontic treatment plans for the selected patients were carefully prepared according to every case separately. In all of those treatment plans, the first two stages were always an initiation of alignment and leveling of the teeth. It was recommended to include in this study only patients with mild to moderate frontal teeth crowding, with the ability to correct this crowding in 6 months maximally. Crowding was classified according to the following criteria described elsewhere (3) as follows: (1) mild: crowding up to three mm (spacing was also included), (2) moderate: crowding between four and six mm, and (3) severe: crowding more than six mm.

The sample of the study consisted of 120 frontal teeth; 10 groups of upper and 10 groups of lower front teeth. Every

group of teeth contained the six frontal teeth from the right canine to the left canine with the canines themselves included. That means every group of teeth (whether upper or lower) contained: the canines, the lateral incisors and the central incisors (Table 1).

Figure 1

Table (1): Study population

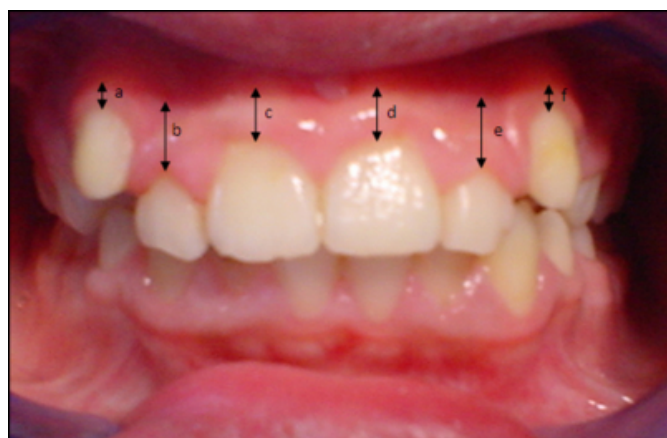
Number of patients		10
Age (Mean \pm SD)		24 ± 6
Sex	Female	9
	Male	1
Sample of study	120 teeth	10 groups of upper incisors (canines + lateral incisors + central incisors)
		10 groups of lower incisors (canines + lateral incisors + central incisors)

In every patient and after proper extraction of the first premolars, the frontal crowded teeth were subjected to a conventional orthodontic alignment and leveling movements by means of a round 0.016×0.016 NiTi wire (Blue Elgiloy, Dentaaurum, Ispringen, Germany) for the first step and gradually into a rectangular 0.018×0.018 NiTi wire (Blue Elgiloy, Dentaaurum, Ispringen, Germany) for the second step. Brackets with 0.018-in slots were used. The wires described above were prepared, placed into the slots and secured by ligatures. The alignment and leveling phase included the distalisation of the canines. All important modifications were made according to every case separately. To control the patients' periodontal status, plaque index (PI) (6), gingival index (GI) (7), probing depth (PD) and papillary bleeding index (PBI) (8) were measured in the mesiobuccal, midbuccal and distobuccal aspects of all examined teeth.

The width of keratinized gingiva was measured 3 times midbuccally at every single tooth in every group of frontal teeth from the gingival margin to the mucogingival conjunction with a millimeter-calibrated periodontal probe (Michigan O probe with Williams markings). The mucogingival junction was defined with Schiller's iodine (IKI) solution as described elsewhere (9). The measurements were recorded to the nearest 1 mm and then expressed as the average of keratinized gingiva width (aKGW) for every group of teeth (Fig. 1).

Figure 2

Figure (1): Average of keratinized gingiva width aKGW is expressed as the sum of KGW records on all the teeth in every group and divided by 6



In the figure, for example, aKGW (in the upper jaw) = $(a+b+c+d+e+f)/6$ (in millimeter)

All clinical parameters as well as aKGW were assessed 4 times; at baseline (prior to orthodontic appliance placement), after 1 month, after 3 months and after 6 months. All orthodontic procedures and clinical assessments of the periodontal tissues were achieved at the department of Orthodontics and at the department of Periodontology – Faculty of Dental Medicine - Damascus University.

After 6 months, the orthodontic alignment and leveling phase was completed.

The values were calculated as the mean \pm standard deviation (SD) and Analysis Of Variance (ANOVA), a calculation procedure to allocate the amount of variation in a process and determine if it is significant or is caused by random noise, was used to evaluate the statistical significance of the differences of the clinical measurements among the experimental categories in each group/column.

A probability of $P < 0.05$ was accepted for rejection of the null hypothesis and to state that with a 95% level of confidence that the two parameters are not the same.

Those statistical analyses were performed by means of a computer software program (version 11, SPSS, Chicago, III).

RESULTS

After 6 months, the alignment and leveling phase was totally achieved and the frontal teeth were set in normal positions.

Considering the periodontal situation, no statistically

significant changes were observed in the scores of plaque index, gingival index, probing depth and papillary bleeding index recorded during the whole period of study ($P > 0.05$) (Tables 2, 3).

Figure 3

Table (2): Periodontal indices recorded during the treatment in the upper jaw

Upper jaw	Baseline	1 Month	3 Months	6 Months	Test
Plaque index	0.01 \pm 0.003	0.1 \pm 0.031	0.1 \pm 0.031	0.1 \pm 0.031	NS
Gingival index	0.15 \pm 0.05	0.16 \pm 0.09	0.41 \pm 0.14	0.4 \pm 0.12	NS
Probing depth	1.64 \pm 0.77	1.42 \pm 0.63	1.68 \pm 0.8	2.03 \pm 1.28	NS
Papillary bleeding index	0.3 \pm 0.05	0.2 \pm 0.02	0.36 \pm 0.09	0.14 \pm 0.01	NS

NS: no statistically significant difference of pairwise comparisons, $P > 0.05$

Figure 4

Table (3): Periodontal indices recorded during the treatment in the lower jaw

Lower jaw	Baseline	1 Month	3 Months	6 Months	Test
Plaque index	0.04 \pm 0.001	0.21 \pm 0.031	0.21 \pm 0.031	0.21 \pm 0.031	NS
Gingival index	0.25 \pm 0.033	0.09 \pm 0.005	0.50 \pm 0.041	0.60 \pm 0.052	NS
Probing depth	1.86 \pm 1.21	1.54 \pm 0.98	1.76 \pm 0.85	2.02 \pm 1.17	NS
Papillary bleeding index	0.25 \pm 0.03	0.16 \pm 0.02	0.4 \pm 0.06	0.14 \pm 0.01	NS

NS: no statistically significant difference of pairwise comparisons, $P > 0.05$

In the upper jaw, aKGW records, expressed in millimeter, were 6.5 \pm 1.02, 6.5 \pm 1.58, 6 \pm 1.25 and 6 \pm 1.02 at baseline, 1 month, 3 months and 6 months respectively. In the lower jaw, aKGW records were 3.5 \pm 0.76, 3.5 \pm 0.62, 3 \pm 0.91 and 3 \pm 0.81 at baseline, 1 month, 3 months and 6 months respectively. No statistically significant changes were found between the measurements during the whole period of observation ($P > 0.05$) (Table 4).

Figure 5

Table (4): Changes of aKGW values in the upper and lower jaws

Time Jaw	Baseline	1 Month	3 Months	6 Months	ANOVA Test
The upper jaw	6.5±1.02 mm	6.5±1.58 mm	6±1.25 mm	6±1.02 mm	NS
The lower jaw	3.5±0.76 mm	3.5± 0.62 mm	3±0.91 mm	3±0.81 mm	NS

NS: no statistically significant difference of pairwise comparisons, $P > 0.05$ mm: Millimeter

DISCUSSION

While the orthodontic treatment might contain several types of tooth movements, it is a little bit difficult to expect an exact reaction of the periodontal tissues around the teeth which undergo orthodontic forces. However, lingual tooth movement will result in an increased buccolingual thickness of the tissue at the facial aspect of the tooth which results in coronal migration of the soft tissue margin (decreased clinical crown height). Facial tooth movement, on the other hand, will result in a reduced buccolingual tissue thickness and thereby a reduced height of the free gingival portion and an increased clinical crown height ($_1$). It should be noted that this is still a debatable topic since other investigators did not find such results ($_{10, 11}$). Another study ($_{12}$) showed that incisor inclination (>95 degrees) and free gingival-margin thickness (>0.5 mm) showed greater and more severe recession on the mandibular central incisors. Nevertheless, when comparing thickness to the final inclination, thickness had greater relevance to recession.

The challenge of alignment and leveling, as the first two stages in almost every orthodontic treatment, is to make the upper and lower teeth fit together. While alignment allows aligning the teeth in a virtual smooth curve, leveling continues the process by lining-up the teeth to be at the same level so they can fit against each other.

In our study, it has been focused on the alterations of the keratinized gingiva width around 120 teeth underwent orthodontic alignment and leveling movements.

The alterations of the periodontal indices in our study were not of statistical significance neither in the upper jaw nor in the lower jaw; it could be attributable to efficient personal

and professional bacterial plaque-control procedures.

In the current study, we considered only the frontal parts of both the upper and the lower jaw to observe any alterations of KGW.

The width of keratinized gingiva around the examined teeth in our study did not show major alterations that could be considered of statistical significance neither in the upper nor in the lower jaw. Since inflammation can lead to morphological changes of the gingiva, any gingival inflammation, when occurs, should always be taken into consideration when the KGW is to be studied. In our study, no gingivitis features were noted around the teeth since GI and PBI records remained stable and within normal limits. According to this observation, it could be stated that the registered alterations of KGW were only due to the orthodontic movements applied. These results agree with other studies which did not show significant alterations of KGW during orthodontic treatments ($_{3, 13}$).

It is well known that orthodontic alignment and leveling phase may consist of different less-controlled types of movements. For this reason, we could not refer the alterations of KGW to only one type of orthodontic movements (i.e. proclination, retraction etc...), since their is no application of specific pure orthodontic movements. However, the reduction of aKGW in the upper jaw from 6.5mm at baseline to 6mm at 6 months, although not significant, may give a sign that the teeth in this part underwent more facial movements. Accordingly, the same can be stated considering aKGW records in the lower jaw which also showed a reduction from 3.5mm at baseline to 3mm at 6 months.

According to Dorfman ($_4$), a continuous creeping of the gingiva in apical direction usually leads to mucogingival problems, namely gingival recession and facial bone dehiscences. In our study, however, no mucogingival complications were noted during the whole period of the study.

This study had certain limitations with regard to precise determination of the movements of soft tissues and the orthodontic forces applied, but it still of value because it was carried out in human subjects for the first time.

CONCLUSION

Within the limitations of the current study, it could be stated that, during the orthodontic alignment and leveling phase,

the keratinized gingiva did not undergo major alterations in width. An exclusion of any features of gingivitis was a prerequisite to confirm this idea. On the other hand, a predominance of facial tooth movements might always be considered when orthodontic alignment and leveling are to be initiated.

ACKNOWLEDGMENTS

The authors are grateful to Prof. Dr. Ramadan Darwish for his statistical advice.

References

1. Wennstrom JL. Mucogingival considerations in orthodontic treatment. *Semin Orthod*1996 Mar;2(1):46-54.
2. Wennstrom J, Lindhe J, Nyman S. Role of keratinized gingiva for gingival health. Clinical and histologic study of normal and regenerated gingival tissue in dogs. *J Clin Periodontol*1981 Aug;8(4):311-28.
3. Trossello VK, Gianelly AA. Orthodontic treatment and periodontal status. *J Periodontol*1979 Dec;50(12):665-71.
4. Dorfman HS. Mucogingival changes resulting from mandibular incisor tooth movement. *Am J Orthod*1978 Sep;74(3):286-97.
5. Sayin MO, Turkkahraman H. Malocclusion and crowding in an orthodontically referred Turkish population. *Angle Orthod*2004 Oct;74(5):635-9.
6. Silness J, Loe H. Periodontal Disease in Pregnancy. Ii. Correlation between Oral Hygiene and Periodontal Condition. *Acta Odontol Scand*1964 Feb;22:121-35.
7. Loe H, Silness J. Periodontal Disease in Pregnancy. I. Prevalence and Severity. *Acta Odontol Scand*1963 Dec;21:533-51.
8. Muhlemann HR. Psychological and chemical mediators of gingival health. *J Prev Dent*1977 Jul-Aug;4(4):6-17.
9. Lang NP, Loe H. The relationship between the width of keratinized gingiva and gingival health. *J Periodontol*1972 Oct;43(10):623-7.
10. Djeu G, Hayes C, Zawaideh S. Correlation between mandibular central incisor proclination and gingival recession during fixed appliance therapy. *Angle Orthod*2002 Jun;72(3):238-45.
11. Melsen B, Allais D. Factors of importance for the development of dehiscences during labial movement of mandibular incisors: a retrospective study of adult orthodontic patients. *Am J Orthod Dentofacial Orthop*2005 May;127(5):552-61; quiz 625.
12. Yared KF, Zenobio EG, Pacheco W. Periodontal status of mandibular central incisors after orthodontic proclination in adults. *Am J Orthod Dentofacial Orthop*2006 Jul;130(1):6 e1-8.
13. Closs LQ, Branco P, Rizzato SD, Raveli DB, Rosing CK. Gingival margin alterations and the pre-orthodontic treatment amount of keratinized gingiva. *Braz Oral Res*2007 Jan-Mar;21(1):58-63.

Author Information

Aous Dannan, D.D.S, M.Sc.

Department of Periodontology, Faculty of Dental Medicine, Witten/Herdecke University

Mohammad Atef Darwish, D.D.S, Ph.D.

Department of Periodontology, Faculty of Dental Medicine, Damascus University

Mohammad Nasser Sawan, D.D.S, Ph.D.

Department of Orthodontics, Faculty of Dental Medicine, Damascus University