

Idiopathic Fibrosis of The Quadriceps Muscle (Vastus intermedius and Vastus lateralis): A Case Report with Magnetic Resonance Imaging

I Al Shuaili, R Bhandal, G Kiefer, S Bhandal

Citation

I Al Shuaili, R Bhandal, G Kiefer, S Bhandal. *Idiopathic Fibrosis of The Quadriceps Muscle (Vastus intermedius and Vastus lateralis): A Case Report with Magnetic Resonance Imaging*. The Internet Journal of Radiology. 2017 Volume 20 Number 1.

DOI: [10.5580/IJRA.47984](https://doi.org/10.5580/IJRA.47984)

Abstract

Idiopathic fibrosis of the quadriceps muscles is not a common entity. The clinical presentation of this entity is typical and Magnetic Resonance Imaging is done to exclude other conditions. Our case is a 27 months old boy that was referred to the rheumatologist by the orthopaedic surgeon presented with gradually progressing loss of flexion of the left knee and limping gait. No history of recent trauma or previous injection to that limb. No history of joint swelling or other joint involvement. Radiographs, ultrasound and the bone scan are normal. No bony abnormality detected and no joint effusion. The Magnetic Resonance Imaging demonstrates atrophy with intra-substance T2 and T1 hyper intense foci suggestive of fatty atrophy with fibrosis of the left side vastus muscles.

INTRODUCTION:

Idiopathic fibrosis of the quadriceps muscles is not a common entity. Early presentation is not usual as well. Few cases were reported in the literature describing the Magnetic Resonance Imaging which is considered the modality of choice for diagnosis and some of them added the histopathological correlation as well.

CASE REPORT:

We report a 27 months old boy that was referred to the rheumatologist by the orthopaedic surgeon from another institution with possible underlying juvenile idiopathic arthritis in the left knee. This patient presented with complaints of gradually progressing loss of flexion of the left knee and limping gait. No history of recent trauma or previous injection to that limb. No history of joint swelling or other joint involvement. Mental and motor development was otherwise normal

Physical examination revealed full extension in both knees but significant loss of flexion of the left knee was seen. The patient was able to do a total of 15 degrees of flexion before he started complaining of severe pain and inability to flex further on the left side. He walked with a significant limp. The rest of the joints exam were unremarkable including his

hips and ankles joint which had full range of motion and no evidence of any effusion or arthritis. No evidence of lesions or rash was seen in the overlying skin.

Radiographs and ultrasound of knees and the bone scan were normal. No bony abnormality was detected neither was joint effusion (Figure 1). The Magnetic Resonance Imaging demonstrated atrophy with intra-substance T2 and T1 hyper intense foci suggestive of fatty atrophy with fibrosis (Figure 2 and 3) compared to the normal side.

Figure 1

AP and lateral radiograph of the left knee show normal bones and soft tissue.

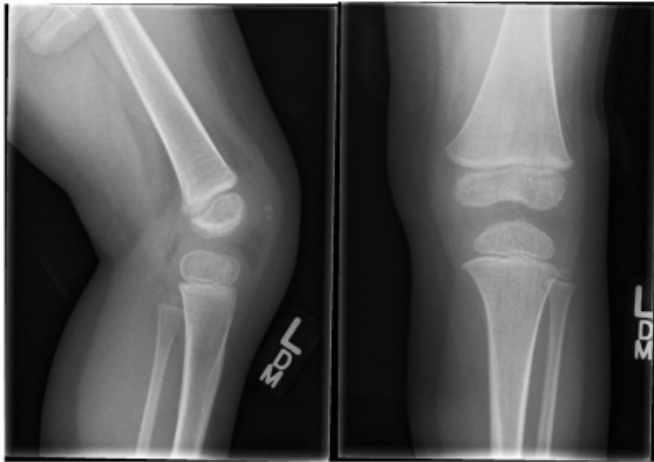


Figure 2

Axial STIR show small size left vastus lateralis and intermedius muscles and hypo-intense signal of the left vastus intermedius muscle compared to the right side.

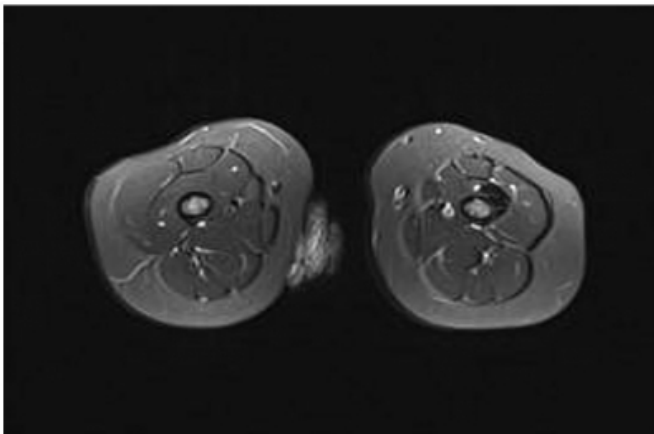
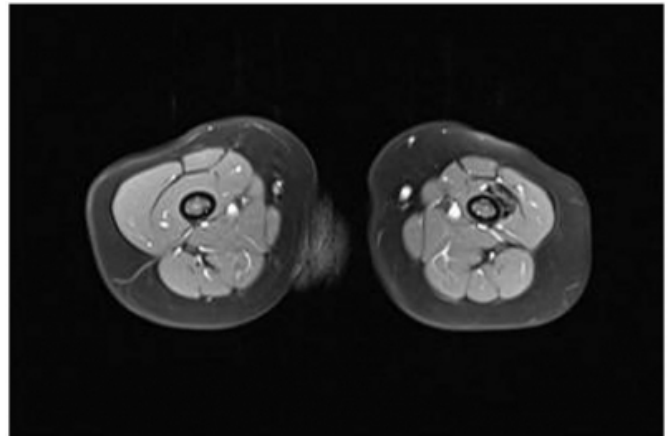


Figure 3

Axial T1 FS post gadolinium show hypo-intense signal of the left vastus intermedius muscle with no enhancement in keeping with fibrosis.



DISCUSSION:

In the literature, quadriceps muscle contractures have been reported as either congenital [1–3] or acquired (mainly due to injections or trauma) [4–5]. Herewith, congenital cases generally display bilateral involvement and acquired ones show unilateral involvement.

Quadriceps contractures have been classified into three types: rectus femoris type, vastus type and mixed type [6]. Vastus type is the most common form and rectus type has been reported as quite rare.

The exact cause is still unknown (8). The pathophysiology of the progressive fibrosis is unclear but was suggested that causes includes compression of the muscles bundle and capillaries by the volume of the medication injected and the toxicity of the drugs (9–11).

MRI findings of this entity include decreased size of the affected quadriceps muscles, fatty atrophy and fibrosis of the muscles. The fatty atrophy appears as hyper-intense signal on T1WI and T2W images with suppression on STIR sequences. Fibrosis appears as hypo-intense in all of the above sequences.

CONCLUSION:

This rare disease should be kept in mind by the general practitioners and the orthopaedic surgeon in cases of loss of flexion of the knee and abnormal gain. Magnetic Resonance Imaging is the modality of choice for diagnosis of this entity. Early diagnosis and treatment can help to prevent and decrease disability.

References

1. Hnevkovsky O. Progressive fibrosis of the vastus intermedius muscle in children. *J Bone Joint Surg* 1961;43B:318–25.
2. Fairbank TJ, Barrett AM. Vastus intermedius contracture in early childhood. *J Bone Joint Surg* 1961;43B:326–34.
3. Karlen A. Congenital fibrosis of the vastus intermedius muscle. *J Bone Joint Surg* 1964;46B:488–91.
4. Lloyd-Robert GC, Thomas TG. The etiology of quadriceps contracture in children. *J Bone Joint Surg* 1964;46B:498–502.
5. Gunn DR. Contracture of the quadriceps muscle. A discussion on the etiology and relationship to recurrent dislocation of the patella. *J Bone Joint Surg Br* 1964;46:492–7.
6. Sano S, Kokubun S. Report of the diagnosis and treatment of muscular contracture– the Ad Hoc Committee of the Japanese Orthopaedics Association of Muscular Contracture. *J Jpn Orthop Ass* 1985;59:223–53.
7. Don P Mathew, Idiopathic Fibrosis of The Quadriceps Muscle (Rectus Femoris): A Case Report with Magnetic Resonance Imaging, *Indian Journal Of Applied Research*. Volume: 6, Issue: 5, May 2016.
8. Rachawan Suksathien. Idiopathic Fibrosis of the Quadriceps Muscle: A Case Report with Magnetic Resonance Imaging and Pathological Findings. *J Med Assoc Thai* 2008; 91 (4): 568-73.
9. McCloskey JR, Chung MK. Quadriceps contracture as a result of multiple intramuscular injections. *Am J Dis Child* 1977; 131: 416-7.
10. Diabach JA. Non traumatic soft tissue disorder. In: Canale ST, editor. *Campbell's operative orthopaedics* 10th ed. Philadelphia: Mosby; 2003: 885-8.
11. Birch JG, Carter PR, Cummings DR, Damsey ME, Ezaki M, Frobish CE, et al. Muscle disease. In: Herring JA, editor. *Tachdjian's pediatric orthopaedics*. 3rd ed. Philadelphia: W.B. Saunders; 2002: 1499-500.

Author Information

Ibtisam Humaid Al Shuaili, Clinical Fellow Paediatric Radiology

Alberta Children Hospital

Calgary, Canada

Rajpal Bhandal, Surgical Assistant. Orthopedic Department

Alberta Children Hospital

Calgary, Canada

Gerry Kiefer, Orthopedic Surgeon. Orthopedic Department

Alberta Children Hospital

Calgary, Canada

Samarjeet Bhandal, Clinical Assistance, University of Calgary

Staff Radiologist, Alberta Children Hospital

Calgary, Canada