

Leiomyosarcoma Of The Maxillary Sinus: An Unusual Site Of Occurrence

S Dhingra, A Sethi, I Singh, D Sareen

Citation

S Dhingra, A Sethi, I Singh, D Sareen. *Leiomyosarcoma Of The Maxillary Sinus: An Unusual Site Of Occurrence*. The Internet Journal of Head and Neck Surgery. 2007 Volume 2 Number 2.

Abstract

We report the case of a 31-year-old female who presented to us with a facial swelling that was diagnosed to be a leiomyosarcoma of the maxillary sinus. The patient was subjected to radical surgery followed by radiotherapy and is free from disease one year following the treatment.

INTRODUCTION

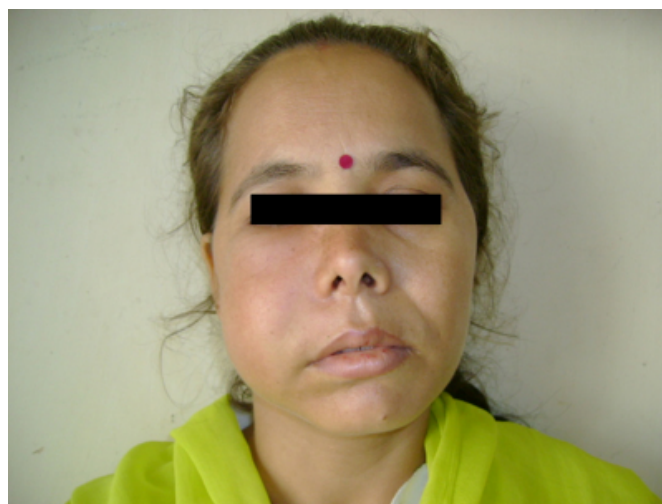Leiomyosarcoma are rare aggressive mesenchymal neoplasms. Since they arise from smooth muscles, they are usually more common in the uterus, gastrointestinal tract and retroperitoneum where there is an abundance of smooth muscle tissue. Only about 3-10% of all leiomyosarcomas arise in the head and neck region¹. Common sites of occurrence in the head and neck include the erector pili muscle in skin, vessel wall, circumvallate papilla, primitive mesenchyme and myoepithelial cells of salivary glands, paranasal sinuses, scalp, cervical esophagus, cheek, buccal mucosa, nose, nasopharynx, tongue, and larynx^{1,2,3,4,5,6}.

CASE REPORT

A 31-year-old female presented to us with a swelling in the area of the right cheek for last four months. The patient was only cosmetically concerned about the mass, as she had no other complaints. It was a firm smooth mass on palpation, about 1.5 X 2 cm in size, with well-defined margins and non-tender.

Figure 1

Figure 1: Showing the right facial swelling on presentation.



Endoscopic assessment of the nasal cavities revealed no abnormality. There was no cervical lymphadenopathy. Rest of the otolaryngological examination revealed no other abnormality.

A CT Scan of the paranasal sinuses was done that revealed a heterogeneously enhancing soft tissue mass involving the right maxillary sinus with destruction of its antero-lateral wall without involving the orbit or the posterior wall of the antrum.

Figure 2

Figure 2: A CECT-Scan of the paranasal sinuses (Axial view) showing the right maxillary sinus mass.

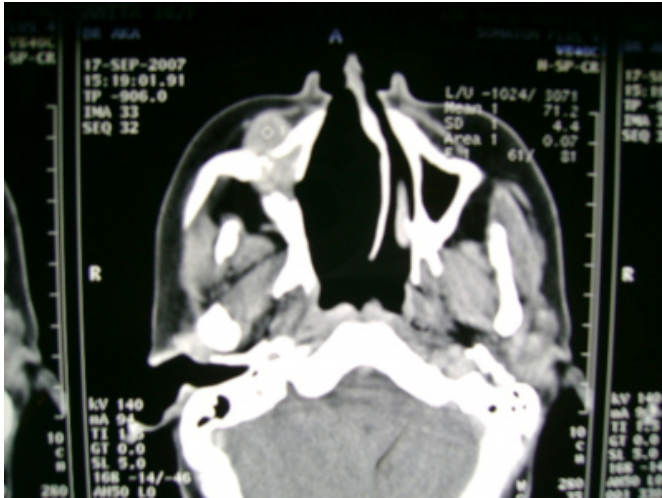
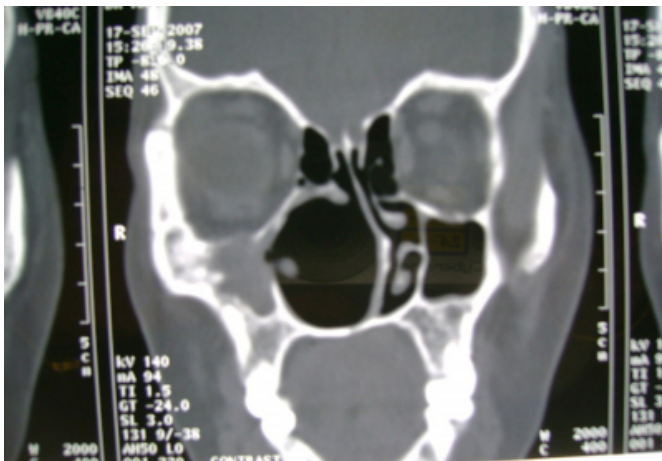
Figure 3

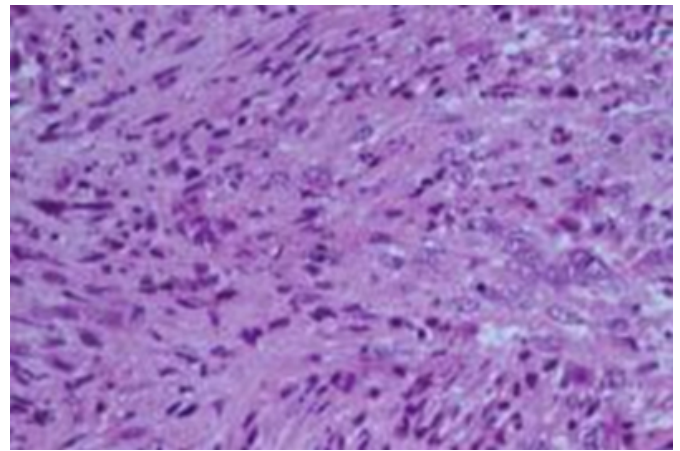
Figure 3: A CECT-Scan of the paranasal sinuses (Coronal view) showing the right maxillary sinus mass.



The patient underwent excision of the mass via a sublabial approach and the entire mass was removed in toto. On gross examination it was a 2 X 2 cm pinkish well circumscribed firm smooth mass. Histopathology revealed it to be a leiomyosarcoma that was confirmed by special stains (actin and vimentin).

Figure 4

Figure 4: Photomicrograph showing spindle cells with abundant eosinophilic cytoplasm and pleomorphism (H & E Staining, 400X).



The patient was subjected to a total maxillectomy on the basis of the tissue diagnosis. The surgery and postoperative period were uneventful. The patient was referred to the medical oncology department where she received postoperative radiotherapy. The patient is well without any symptoms for the disease one year post-treatment.

DISCUSSION

Leiomyosarcomas are among the unusual soft tissue sarcomas of the head and neck. Since 1950, only 38 cases of leiomyosarcoma of the head and neck structures have been reported. Twenty-seven patients were male, and eleven were female. Ages ranged from 2 months to 88 years, the average age being 45 years. A bimodal tendency exists with 40% of cases recorded in patients one to twenty-nine years old and 40% occurring in patients 51 to 67 years of age. Six cases occurred in children⁶. The behaviour of these lesions is related to the site and extent of the primary tumour. Epistaxis, dysphagia, hoarseness, fever, stridor, and cough have been reported depending upon the site of the lesion^{2,4,5}. Rare symptoms include pain and tenderness whereas they are more prominent features of leiomyomas.

Clinically, leiomyosarcoma presents as slowly enlarging, discrete, firm, non-ulcerated painless mass. The lesion is submucosal or subcutaneous, reflecting its mesenchymal origin. Stout and Hill concluded in their work on leiomyosarcomas that lesions of soft tissue origin that were 2.5 cm or larger were more likely to be malignant⁶. On gross examination, leiomyosarcomas appear smooth and well circumscribed. They are usually unencapsulated and grey, tan or pink in colour. They may be polypoidal or

sessile. Microscopically, they appear as spindle shaped cells, with centrally cigar shaped nuclei with paranuclear vacuoles and intensely eosinophilic cytoplasm⁵. Anaplastic features of large, bizarre, pyknotic nuclei and mitotic features are seen in varying degrees. The number of mitotic figures per high power field is an important feature of malignancy. Tumors, which exhibit one mitotic figure per five high power fields, are considered malignant⁶. They express muscle specific actin, vimentin and desmin.

Optimal treatment is complete resection of the tumour atleast with a one cm margin. Radical resection alone does cause a high rate of local control but achieving a complete resection is usually not feasible due to anatomical constraints. Local recurrences are therefore common and a recurrence rate of 35-50% has been reported². Metastasis occurs via hematogenous route most commonly to the lungs. Cervical metastasis, mostly due to contiguous spread has been reported in 15% cases³. Distant metastasis occurs earlier as opposed to cervical metastasis. Rate of regional lymph node metastasis has been reported as 2-5%⁴. Lesions arising from the skin, nasal cavity, and larynx are associated with a better prognosis than lesions in other sites in the head and neck, probably because these sites are more amenable to complete surgical resection. Most patients with soft tissue sarcomas of head and neck receive postoperative adjuvant radiotherapy (RT), including those with low grade lesions⁴. The 5-year local control rates of combination of surgery and RT in soft tissue sarcomas arising in the head and neck range 60-70%,

which are similar to the 5-year cause-specific and overall survival rates⁴. Our patient was also subjected to radical surgery followed by postoperative radiotherapy and is disease-free one year following treatment. The value of adjuvant chemotherapy is unclear. Few data directly pertain to the efficacy of chemotherapy for these tumors.

Leiomyosarcomas are exceptionally rare. Accurate diagnosis and treatment is largely based on a careful search for clinical signs such as bone destruction and invasion of adjacent tissues. A prolonged follow up is necessary to rule out a probable relapse.

CORRESPONDENCE TO

Dr Ashwani Sethi E-80, Naraina Vihar New Delhi-110028, INDIA. Phone No: 91-11-9811338978 E mail- dr_sethi@rediffmail.com

References

1. Goldberg SH, Hanft K, Ossakow J. Pathologic quiz case 1:Leiomyosarcoma. Arch Otolaryngol Head Neck Surg 1988; 114: 1330-2
2. Mindell RS, Calcaterra TC, Ward PH. Leiomyosarcoma of the head and neck. A review of the literature and report of 2 cases. Laryngoscope 1975; 85: 904-10
3. Kazemian A, Kamian SH, Hosein MS, Azizi MR. Leiomyosarcoma of the tongue; Report of a case. Iran J Radiat Res, 2005; 3(3): 143-147
4. Mendenhall WM, Mendenhall CM, Werning JW, Riggs CE, Mendenhall NP (2005). Adult head and neck soft tissue sarcomas. Wiley Inter Science, DOI: 10.1002/hed. 20249.
5. Dobben GD. Leiomyosarcoma of the nasopharynx. Arch Otolaryngol 1958; 68: 211-3
6. Stout AP, Hill WT. Leiomyosarcoma of superficial soft tissues. Cancer 1958; 11: 844-854.

Author Information

Shruti Dhingra, M.S.

Junior Resident, Department of ENT, M.A.M.C. and associated L.N. Hospital

Ashwani Sethi, M.S.

Senior Resident, Department of ENT, M.A.M.C. and associated L.N. Hospital

Ishwar Singh, M.S.

Professor, Department of ENT, M.A.M.C. and associated L.N. Hospital

Deepika Sareen, M.S.

Senior Resident, Department of ENT, M.A.M.C. and associated L.N. Hospital