

Congenital Caecal Band Presenting as Appendicitis

A De Rosa, K Oyewole, M Sait, T Gathani, R Vashisht

Citation

A De Rosa, K Oyewole, M Sait, T Gathani, R Vashisht. *Congenital Caecal Band Presenting as Appendicitis*. The Internet Journal of Surgery. 2008 Volume 21 Number 2.

Abstract

Congenital bands are extremely rare and often present in childhood with symptoms of bowel obstruction. They are thought to develop during embryogenesis, where abnormal adhesions of peritoneal folds induce the formation of a fibrous band. Congenital bands have been described between the bowel, mesentery, abdominal wall, liver and intra-abdominal ligaments. We report a case of a 22-year-old female who presented with symptoms and signs of appendicitis; at laparoscopy, a congenital band was found connecting the caecum to the anterior abdominal wall with a normal appendix. This case represents an unusual presentation of a congenital band in an older individual. In addition, to our knowledge, we are the first to describe a congenital band connecting the caecum to the anterior abdominal wall.

BACKGROUND

Congenital bands are extremely rare. They often present in childhood with symptoms of bowel obstruction, due to mechanical compression of the bowel by the band or entrapment of a bowel loop between the band and the mesentery. The location of congenital bands is variable. They have been described between the bowel, mesentery, abdominal wall, liver and intra abdominal ligaments. However, there are no other case reports describing a congenital band connecting the caecum to the anterior abdominal wall. This case is both important and interesting on three accounts - it describes an atypical presentation of a congenital band, in an older patient, at an anatomical location that has not previously been described in the literature.

CASE REPORT

A 22-year-old female presented to the accident and emergency department with a three-day history of worsening abdominal pain. The pain began in the umbilical region and moved to the right iliac fossa. It was constant in nature and exacerbated by movement. She felt nauseous but had not vomited. She had opened her bowels that morning and had no urinary symptoms. She had no gynaecological symptoms and her last menstrual period was three weeks before.

Eighteen months ago she had experienced a similar episode and an abdominal ultrasound scan at that time was normal. Past medical history included psoriasis treated with almond oil and no previous surgery or history of tuberculosis.

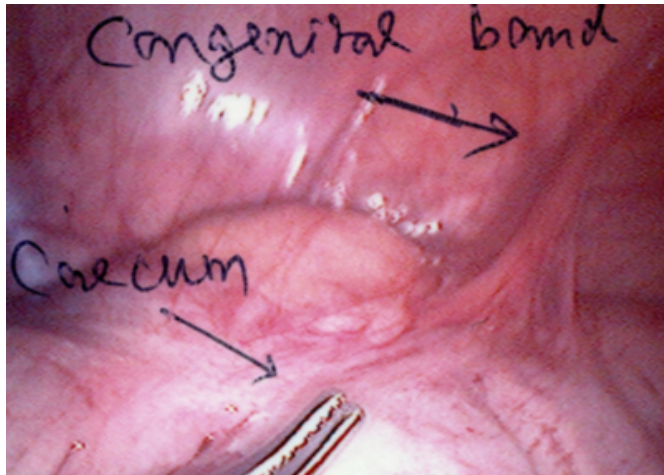
On initial examination she was afebrile and haemodynamically stable. Abdominal examination demonstrated diffuse tenderness and localised peritonitis in the right iliac fossa.

Laboratory investigations showed a normal white cell count and mildly elevated C-reactive protein (25 mg/L). Urine dipstick testing was positive for ketones (trace) and blood (2+). Abdominal ultrasound scan did not show a dilated appendix, unfortunately the ovaries could not be visualised.

Clinically, she continued to experience pain and was persistently tender in the right iliac fossa and hence a diagnostic laparoscopy was performed with the patient's consent thirty six hours post admission. At laparoscopy a dense band was seen connecting the caecum to the anterior abdominal wall and a macroscopically appearing normal appendix (Image 1). No Meckel's diverticulum was identified. The band was divided releasing the caecum and the appendix was removed.

Figure 1

Image 1. Photo showing the congenital band between the caecum and anterior abdominal wall



The patient made an uneventful postoperative recovery and was discharged the following day. Subsequent histology demonstrated a microscopically normal appendix. At follow-up six months later she was symptom-free.

DISCUSSION

Congenital bands cause and usually present with symptoms of bowel obstruction. Rarely, the presentation may be more suggestive of other conditions such as mesenteric infarction, perforated duodenal ulcer, diverticulitis, cholecystitis or strangulated hernia, and there are only two other reports of congenital bands presenting as appendicitis in a French article by Habib et al.¹, but the anatomical location of the band in this case was not described to arise from the caecum.

The anatomy of congenital bands is variable and several locations have been described including between the ascending colon and terminal ileum, ligament of Treitz and terminal ileum, right lobe of the liver and ascending colon², rim of the iliac fossa to the sigmoid mesocolon³, jejunum to jejunum⁴, ileum to the sigmoid mesentery⁵, root of the mesentery to jejunum^{6,7}, terminal ileum to the mesoappendix⁸ and Ladd's bands arising from the caecum going across the duodenum to the parietal peritoneum in the

right hypochondrium. There are no cases in the literature describing a congenital band between the caecum and the anterior abdominal wall.

In this case, the absence of constipation, vomiting, hypovolaemia and radiological signs made bowel obstruction unlikely. The nature and location of the pain made appendicitis versus an ovarian pathology the most likely differential diagnosis. Irrespective of the suspected diagnosis, in a case such as this where symptoms and signs persist for a number of days in the absence of conclusive imaging, surgical intervention is necessary to avoid complications, which in cases of symptomatic congenital bands are those of untreated bowel obstruction. Laparoscopy is a safe and feasible method in the diagnosis and treatment of congenital bands⁹, as well as in the diagnosis and possible treatment of those conditions that they may mimic.

References

1. Habib E, Elhadad A. Small bowel obstruction by a congenital band in 16 adults. *Ann Chir* 2003;128:94-7. French.
2. Akgur FM, Tanyel FC, Buyukpamukcu N, Hicsonmez A. Anomalous congenital bands causing intestinal obstruction in children. *J Paediatr Surg* 1992;27:471-3.
3. Lin DS, Wang NL, Huang FY, Shih SL. Sigmoid adhesion caused by a congenital mesocolic band. *J Gastroenterol* 1999;34:626-8.
4. Itagaki MW, Lema R, Gregory JS. Small bowel obstruction caused by a congenital jejuno-jejuno band in a child. *Pediatr Emerg Care* 2005;21:673-4.
5. Barias E, Sezen O, Firuzan D, Mesut Y, Harun G. Anomalous congenital band: a rare cause of intestinal obstruction and failure to thrive. *Pediatr Surg Int* 2005;21:1018-20.
6. Dimitrois C, George AA, Dimosthenis Z, Nikolas X. Intestinal obstruction due to an anomalous congenital band. *Saudi J Gastroenterol* 2008; 2008;14:36-37.
7. Liu C, Wu TC, Tsai HL, Chin T, Wei C. Obstruction of the proximal jejunum by an anomalous congenital band-a case report. *J Pediatr Surg* 2005;40:E27-9.
8. Maeda A, Yokoi S, Kunou T, Tsuboi S, Niinomi N, Horisawa M, Bando E, Uesaka K. Intestinal obstruction in the terminal ileum caused by an anomalous congenital vascular band between the mesoappendix and the mesentery: Report of a case. *Surg Today* 2004;34:793-795.
9. Wu JM, Lin HF, Chen KH, Tseng LM, Huang SH. Laparoscopic diagnosis and treatment of acute small bowel obstruction resulting from a congenital band. *Surg Laparosc Endosc Percutan Tech* 2005; 15:294-6.

Author Information

Antonella De Rosa, MB ChB

Department of General Surgery, West Middlesex University Hospital

Kehinde Oyewole, MB ChB

Department of General Surgery, West Middlesex University Hospital

Mohamed Razick Sait, MD MRCS

Department of General Surgery, West Middlesex University Hospital

Toral Gathani, MD, MRCS

Department of General Surgery, West Middlesex University Hospital

Rajiv Vashisht, FRCS

Department of General Surgery, West Middlesex University Hospital