

# Mycetoma of Hand-An unusual presentation

K Rahman, M Naim, M Farooqui

## Citation

K Rahman, M Naim, M Farooqui. *Mycetoma of Hand-An unusual presentation*. The Internet Journal of Dermatology. 2009 Volume 8 Number 1.

## Abstract

Mycetoma, also known as "Maduromycosis", after the name of place Madurai in south India, is a chronic, specific, granulomatous, progressive inflammatory disease, mainly affecting the foot. The affection of hand is uncommon. We present here a case of middle age man who presented with swelling and discharging sinuses in right hand form where there was discharge of black colored grains. Radiograph showed extension in bone and soft tissue with lytic lesion in 2<sup>nd</sup> metacarpal. He was treated with antifungal and amputation of 2<sup>nd</sup> finger and is doing fine for last 3 months.

## INTRODUCTION

Mycetoma is chronic subcutaneous infections characterized by a clinical triad of chronic indurations, draining sinuses and discharge of granules<sup>1</sup>. The granules are microcolonies of causative agent. It was described for the first time by Gill in 1842 and named "Madura Foot" after the place Madurai in south India where it was detected<sup>2</sup>. Infection develops after traumatic inoculation of contaminated soil, containing the causative agent and progress to adjacent tissue and bone. Foot is the most commonly affected organ and affection of hand is a rarity<sup>3</sup>. Several clinical strategies are available for the treatment which includes surgery, ketoconazole, voriconazole, itraconazole and amputation<sup>4</sup>. We report a case of mycetoma hand that recurred several times and was cured finally by amputation.

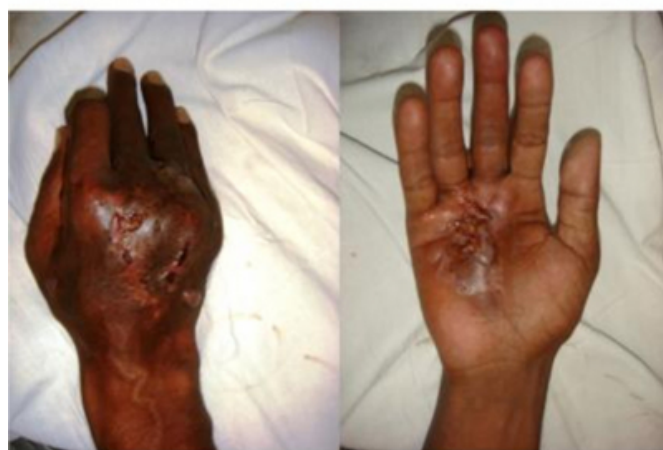## CASE REPORT

A middle aged male, farmer by profession, from a north Indian village presented with a complaint of swelling and discharging sinus over right hand for 4 months. He was apparently well 3 yrs back when he injured his hand during routine farming work. Few days after, he developed swelling and a discharging sinus. He consulted a local practitioner who prescribed some antibiotics. After three months when there was no improvement, he was admitted in a hospital where some injectible antibiotics were administered along with wound debridement. He showed some improvement but after 6 months he again developed similar complaints and presented at our institute with swelling and a discharging sinus from which there was discharge of black colored grains. He was diagnosed as a case of mycetoma of hand and

antifungal was started. He continued the treatment for 12 months and the sinus got healed. Four months back there was recurrence of swelling and sinus with discharge of black colored grains.(Figure 1) The symptoms were now accompanied with pain. On plain radiograph a lytic lesion of head of 2<sup>nd</sup> metacarpal was seen, which suggested the involvement of bone.(Figure 2).

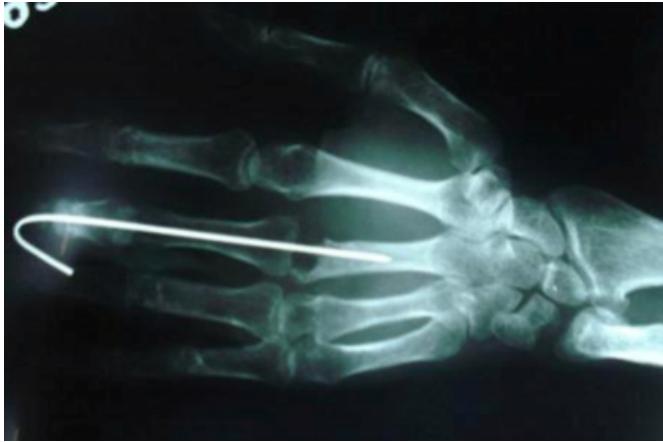## Figure 1

Figure 1: Dorsal and ventral aspect of hand showing swelling and discharging sinuses through which black colored grains were discharged.



**Figure 2**

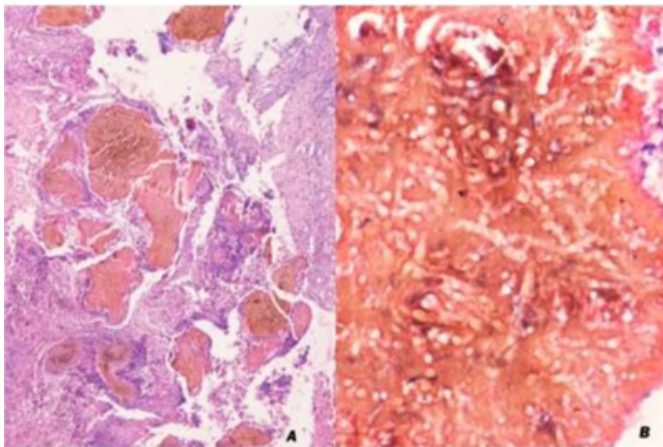
Figure 2: Radiograph shows a lytic lesion at the head of second metacarpal with the wire in situ.



Wound was debrided and sent for histopathological and microbiological examination. A wire was put for the proper alignment of bone. On direct examination fungal spores were seen but there was no growth on culture. Histopathological examination showed fibrocollagenous tissue containing several granules that on close examination showed fusiform, pseudoseptae, branching hyphae along with spores. (Figure 3).

**Figure 3**

Figure 3: Histopathological section showing several grains (microcolonies) in a fibrocollagenous tissue (A, H&E, 4 X), which on higher magnification shows presence of fungal hyphae and spores (B, H&E, 40X)



A diagnosis of mycetoma hand was put forth. He was followed for three months and when there was not much improvement; amputation was done, with removal of 2<sup>nd</sup> finger up to metacarpal. Histopathological examination of the tissue showed similar granules composed of fungal hyphae. The patient is being followed up for last two months. He is on oral Ketoconazole and is doing fine.

## DISCUSSION

There are two major forms of mycetoma; bacterial mycetoma also known as actinomycetoma and fungal mycetoma or eumycetoma. Mycetoma principally occurs in tropical and subtropical regions in areas between latitude of 15 S and 30 N<sup>5</sup>. It commonly occurs on foot followed by hand, knee, arm, leg, head and neck, thigh and the perineum. Other rare sites include eyelids, testes, lymph node and middle ear cleft<sup>6</sup>.

The organism is inoculated traumatically through soil in the form of thorn prick, trauma leading to ulceration, blunt trauma and wicks. Clinically they present as progressive granulomatous lesion, sinus tract formation and discharge of grains, tumefaction and spreading into adjacent tissue, bone fascia and ligaments<sup>6</sup>.

The grains discharged from sinus tracts may be white, yellow, brown, red or black depending upon the causative agent<sup>6</sup>. Discovery of these typical grains which are compact colonies of the causative organism and their direct microscopically and cultural examination clinches the diagnosis and differentiates this condition from superficially similar disease like tuberculosis, leprosy, syphilis, elephantiasis, balstomycosis, neoplasm and others. Microscopic examination of the granules shows branching hyphae and spores.

The treatment is by specific chemotherapeutic agents against the causative organism with or without surgery. Amputation may be required for some resistant cases. Ketoconazole or Itraconazole in combination with surgical intervention is recommended for eumycetoma<sup>7</sup>. But, in all cases medical supervision is required as this condition is prone to recurrences.

## References

1. Foltz KD and Fallat LM. Madura foot: atypical finding and case presentation. The journal of foot and ankle surgery. 2004; 43(5): 327-331.
2. Gill. Indian army medical reports. 1874. Churchill, London.
3. Rai V, Balacharan C. Actinomycotic mycetoma of hand; a rare occurrence. Indian journal of Dermatology, Venerology and leprology. 2006; March 1.
4. Loulergue P, Hot A, Dannaoui E et al. Successful treatment of black grain mycetoma with voriconazole. American Journal of Tropical Medicine and hygiene. 2006 Dec; 75 (6): 1106-1107.
5. Mahgoub ES, Murray IG. Mycetoma. William Heinemann, Medical Books Ltd; London: 1973: p 16-29.
6. Mahmoudabadi AZ, Zarrin M. Mycetoma in Iran: a review article. Mycopathologica 2008; 165: 135-141.
7. Negroni R, Lopez Daneri G, Arechavala A, Bianchi MH, Robles AM. Clinical and microbiological study of

mycetoma at Muniz hospital of Buenos Aires between 1989    abd 2004. Rev Argent Microbiol 2006; 38: 13-8.

**Author Information**

**Khaliqur Rahman, MD**

Senior Resident, Department of Pathology, J.N. Medical College, AMU, Aligarh, INDIA-202002

**Mohammed Naim, MD**

Professor, Department of Pathology, J.N. Medical College, AMU, Aligarh, INDIA-202002

**Mohd Raza Farooqui, MS**

Senior Resident, Department of Plastic Surgery, J.N. Medical College, AMU, Aligarh, INDIA-202002