

# Surgical Outcomes Of Inverted Papilloma: A Retrospective Review Of Endoscopic And External Approaches

B Abdullah, K Abdullah, S Khan, M Hamzah

## Citation

B Abdullah, K Abdullah, S Khan, M Hamzah. *Surgical Outcomes Of Inverted Papilloma: A Retrospective Review Of Endoscopic And External Approaches*. The Internet Journal of Head and Neck Surgery. 2006 Volume 1 Number 1.

## Abstract

**Introduction:** Inverted Papilloma is a benign sinonasal tumour which generates considerable interest because they can recur and undergo malignant transformation.

**Methodology :** We performed a retrospective analysis of patients treated at Universiti Sains Malaysia Hospital to determine the surgical outcome of the external and endoscopic approaches. Ten patients with inverted papilloma who underwent the external and the endoscopic treatment between July 1999 and May 2005 were analysed.

**Results :** The study group consisted of 8 male and 2 female patients with mean age of 48 years. The external approach was done in 7 cases whereby an endoscopic technique was done in 3 cases. The follow up period ranged from 3 to 50 months (mean, 20 months). Recurrence rate was 28 % for external approach and none for endoscopic approach.

**Conclusions :** Endoscopic approach has a good surgical outcome in inverted papilloma but case selection plays an important role. Endoscopic technique has the advantage of less postoperative morbidity and also gives an advantage for second surgery by the external approach should a recurrence occur.

## INTRODUCTION

Inverted Papilloma is considered as the most common benign sinonasal tumour and it has a characteristic of aggressive local invasion, high incidence of recurrence and transformation into squamous cell carcinoma. The incidence is between 0.5 to 4 %<sup>1</sup>. It usually arises from the lateral wall of the nose (about 90 % of cases) and in small percentage of cases it does arise from the septum. Of all the paranasal sinuses, maxillary sinus is commonly involved; followed by ethmoid sinus, sphenoid sinus and frontal sinus<sup>1</sup>. In the majority of the cases, unilateral nasal obstruction is the main presenting complaint. Other symptoms include epistaxis, rhinorrhea, facial discomfort, headache and hearing impairment.

Due to its aggressiveness and tendency for local recurrence, most authors agreed that external approach which provides good exposure for tumour clearance is the gold standard treatment<sup>1</sup>. However since 15 to 20 years back, with the advancement of technologies and better imaging technique reasonable clearance of the tumour can also be achieved by a

less cumbersome endoscopic approach. Since then many cases were reported including small and large series regarding the effectiveness of an endoscopic approach even though some still advocate the traditional technique<sup>1,2,3</sup>.

In our small series of ten patients, we would like to determine the surgical outcome of the two techniques in our centre. Other information such as demographic data will also be discussed.

## METHODOLOGY

Operative data entries from 1999 till 2005 were reviewed to find all the operated inverted papilloma cases. Record of ten patients were managed to be traced from the record office. All data including age, sex, presenting complaints, site of tumour, type of surgery, operating surgeon, period of follow up and recurrence were recorded. Data were analysed with SPSS software version 12. Mann Whitney test was performed for non parametric independent two variables to see for any statistical significant differences between the external and the endoscopic approaches in term of tumour recurrence.

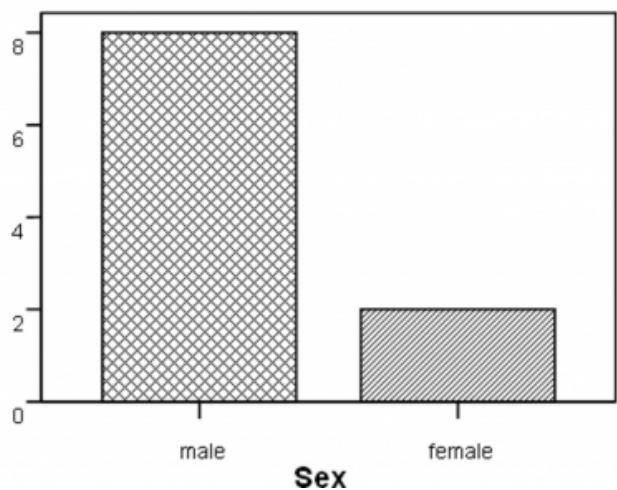
**RESULTS**

There were 8 males and 2 females in this study which confirmed the male preponderance ( Fig 1). Age ranged from 37 to 69 years with a mean age of 48 years. 70% of the cases presented with unilateral nasal obstruction, 20% with epistaxis and 10% gives nasal discharge as the main complaint (Fig 2). The follow up period ranged from 3 to 50 months with a mean of 20 months. The decision of the surgical approach was basically based on surgeon preferences. One surgeon preferred the external approach while the other performed the endoscopic approach. The external approach for excision of IP was performed in 7 cases including one case of initial endoscopic converted into the external approach. Only 3 cases were done endoscopically. Recurrence rate was 28 % which involved 2 cases after a follow up period of 12 and 13 months. There was no recurrence from endoscopic approach. Mann Whitney test was performed for non parametric independent two-group comparisons (Fig 3a and 3b). The P value of 0.326 indicates that the difference between the 2 groups of treatment was not significant in terms of tumour recurrence.

**Figure 1**

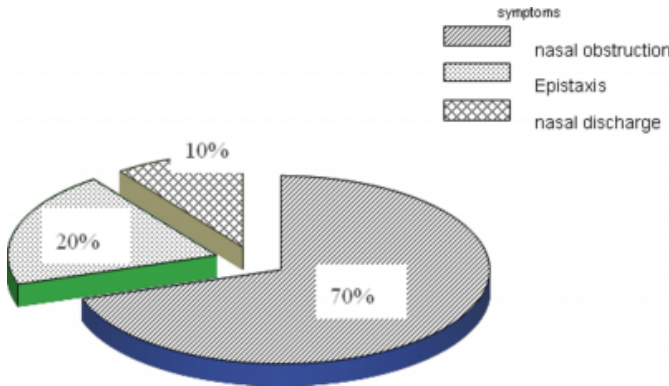
Figure 1: The above bar chart shows male outnumbered female with ratio 4 to1

**Count**



**Figure 2**

Figure 2: Pie chart that shows nasal obstruction is the commonest presenting complaint followed by epistaxis and nasal discharge



a Not corrected for ties.

**Figure 3**

Figure 3a

	Method of Treatment	N	Mean Rank	Sum of Ranks
Recurrence	External approach	7	5.07	35.50
	Endoscopic approach	3	6.50	19.50
	Total	10		

**Figure 4**

Figure 3b

	Recurrence
Mann-Whitney U	7.500
Wilcoxon W	35.500
Z	-.982
Asymp. Sig. (2-tailed)	.326
Exact Sig. [2* (1-tailed Sig.)]	.517 (a)

Both Fig. 3 (a) and 3 (b) showing the results of test statistic that was performed.

## DISCUSSION

Sinonasal papilloma is defined as benign epithelial tumour composed of well differentiated columnar or ciliated respiratory epithelium with variable squamous differentiation<sub>1</sub>. Histologically it can be divided into exophytic or fungiform papilloma, columnar cell papilloma and inverted papilloma. The latter displays a pattern of growth towards the underlying stroma without breaching of the basement membrane.

The incidence ranges from 0.5 % to 4 % of all primary nasal tumours and it is prevalent in the fifth and sixth decades of life<sub>1</sub>. Males are 4 to 5 times more common to be affected than females. The most common presenting complaint was nasal obstruction (50%), nasal discharge (20.8%), epistaxis (16.6 %) and 4.2% of the patient presented with frontal sinusitis<sub>5</sub>. Lateral nasal wall and middle turbinate are commonly involved by inverted papilloma in 93% of cases<sub>1</sub>. Of all the paranasal sinuses, maxillary sinus is the most common to be affected by the tumour which is 48% of the

cases followed by ethmoid sinus (46%), sphenoid sinus (12%) and 8% for frontal sinus<sub>1</sub>.

As proposed by Krouse in year 2000<sub>6</sub>, inverted papilloma can be divided into 4 different stages. In stage I, the tumour is confined to the nasal cavity with no evidence of malignancy. In stage II, the tumour involves the osteomeatal complex, ethmoids and or medial wall of maxillary sinus without any evidence of malignancy. In stage III, the tumour involves the inferior, superior, lateral or anterior wall of maxillary sinus, sphenoid and or frontal sinus without evidence of malignancy. Finally in stage IV, the tumour extends beyond the nasal cavity or paranasal sinuses or the tumour is associated with malignancy. Based on this staging method, in our present series there were 45% (5 patients) for stage II, 36% (4 patients) for stage III and 18 % (2 patients) for stage IV.

CT scan is the radiological investigation of choice in the majority of cases although MRI may be more superior in delineating the surrounding soft tissue involvement. MRI is also valuable in differentiating between a tumour and sinusitis. These radiological evidences are very important in determining the approach and also to provide a guide during surgery.

The surgical management of inverted papilloma has evolved over the years. A previously famous facial incision (lateral rhinotomy), extensive nasal packing and prolonged hospital stay have been replaced by a more conservative, less morbid and cost effective endoscopic surgery. Although, external approach gives an adequate exposure of the entire sinonasal complex for tumour clearance, advancement in imaging technique and endoscopic instruments resulted in the endoscopic approach being the preferred method of treatment in inverted papilloma. It not only reduces the morbidity but at the same time have a recurrence rate if not better is comparable with the conventional method.

However, one should bear in mind that all these are strictly based on case selection. Some authors prefer an endoscopic approach for early stage of inverted papilloma but some still managing advanced stage inverted papilloma endoscopically and reserve external approach for recurrent tumour. With the advanced in endoscopic and powered instruments along with better illumination, there are authors treating recurrent inverted papilloma endoscopically with reasonable outcome<sub>7</sub>.

The morbidity that may be associated with an external

approach with lateral rhinotomy incision are epiphora, chronic dacryocystitis, transient diplopia and eustachian tube dysfunction. Other external approaches such as midfacial degloving, septal translocation and Rouge-denker's operation even though have no external scarring, the morbidity is still high. Due to this, the quality of life of those patients who had an external approach are expected to be lower than those who had an endoscopic approach.

Our comparison is statistically not significant most probably due to the small study size. The choice of treatment was mainly surgeon preferences as one preferred an external approach while the other preferred the endoscopic technique. Recurrence rate was 28% for external approach and no recurrence for endoscopic approach after a mean follow up period of 25 month. Collectively our series shows recurrence rate of 20% and this overall recurrence rate was almost equal to one of the largest series by Lawson et al<sup>1</sup>, which is 18% in 160 cases. Our data however might not reflect the true scenario as majority of the patient defaulted follow up. In the two recurrence cases, one was Krouse stage III and the other was stage IV. Both are treated via external approach including one case of endoscopic converted to an external approach.

Long term follow up is crucial as recurrence may be associated with incidence of malignancy<sup>1</sup>. It is mandatory to prospectively follow the patients every 4 months during the first postoperative year and subsequently every 6 months for at least 4 years<sup>8</sup>.

## **CONCLUSIONS**

With a proper case selection, inverted papilloma can be successfully treated via an endoscopic approach with a recurrence rate comparable to the external approach and this was established by many reported series including the largest

one by Lawson et al<sup>1</sup>. Endoscopic technique has the advantage of less postoperative morbidity and also gives an advantage for second surgery by the external approach should a recurrence occur. The tendency for recurrence and relatively high incidence of malignant transformation mandates careful long term follow-up.

## **CORRESPONDENCE TO**

Dr Baharudin Abdullah MBBS(Mal), MMED ORL-HNS (USM) Department of Otolaryngology - Head and Neck Surgery (ORL-HNS), School of Medical Sciences, Universiti Sains Malaysia, Kubang Kerian 16150, Kelantan, Malaysia. Tel: + 609-7664110 Fax: +609-7653370 Email: baharudin@kb.usm.my

## **References**

1. Lawson W, Kaufman M and Biller HF. Treatment outcomes in the management of inverted papilloma: an analysis of 160 Cases. *Laryngoscope* 2003; 113(9): 1548-1556.
2. Yoon JH, Kim CH, Choi EC. Treatment outcomes of primary and recurrent inverted papilloma: An analysis of 96 cases. *Journal of Laryngology and Otology* 2002; 116 ( 9); 699-703.
3. Baruah P, Deka RC. Endoscopic management of inverted papillomas of the nose and paranasal sinuses. *Ear, Nose and Throat J* 2003; 82(4); 317-321.
4. Brors D and Draf W. The treatment of inverted papilloma. *Current Opinion in Otolaryngology & Head & Neck Surgery* 1999; 7(1):33.
5. Wormald PJ, Ooi E, van Hasselt CA, et al. Endoscopic removal of sinonasal inverted papilloma including endoscopic medial maxillectomy. *Laryngoscope* 2003;113(5): 867-873.
6. Krouse JH. Development of a staging system for inverted papilloma. *Laryngoscope* 2000;110 :965-968.
7. Lee TJ, Huang SF, Lee LA, et al. Endoscopic surgery for recurrent inverted papilloma. *Laryngoscope* 2004;114(1):106-112.
8. Tomenzoli D, Castelnuovo P, Pagella F, et al. Different endoscopic surgical strategies in the management of inverted papilloma of the sinonasal tract: experience with 47 patients. *Laryngoscope* 2004; 114(2):193-200.

**Author Information**

**Baharudin Abdullah, MMED ORL-HNS (USM)**

Dept of ORL-HNS, School of Medical Sciences, Univ. Sains Malaysia(USM)

**Kahairi Abdullah, MBBS (Mal)**

Dept of ORL-HNS, School of Medical Sciences, Univ. Sains Malaysia(USM)

**Shamim Ahmed Khan, FRCS**

Dept of ORL-HNS, School of Medical Sciences, Univ. Sains Malaysia(USM)

**Mohd Hamzah, MS ORL (UKM)**

Dept of ORL-HNS, School of Medical Sciences, Univ. Sains Malaysia(USM)